

Conference Paper

The Caries Process and Its Effect on the Pulp: The Science Is Changing and So Is Our Understanding

Lars Bjørndal, DDS, PhD

Abstract: *The understanding of the caries process and its effect on the pulp is presented in the context that caries does develop in various rates of progression. Early in the caries process, the pulp reflects changes within lesion activity. Thus, the early pulp response is reversible. Later, the rate of caries progression is reflected by the quality of the tertiary dentin. Slowly progressing lesions create tertiary dentin resembling normal tubular dentin. Rapidly progressing lesions lead to the production of atubular dentin or complete absence of tertiary dentin, as well as pulp necrosis and apical pathology. Finally, the nature of the untreated deep carious lesion is an ecosystem that might undergo significant changes. The untreated lesion is temporarily converted from an active and closed lesion environment into one that is open and slowly progressing. The analysis of untreated carious lesions has transformed the treatment philosophy of deep carious lesions. (Pediatr Dent 2008;30:192-6)*

KEYWORDS: DENTAL CARIES, DENTAL PULP, DENTIN, INDIRECT PULP TREATMENT, STEPWISE EXCAVATION, TERTIARY DENTIN

Can We Obtain Consensus on Caries Pathology?

Caries can be compared with a train that passes through many stations. Imagine that each station represents a specific stage of caries progression. The first station represents the initial surface etching at the outer enamel layer, leading to the dull white appearance of the active progressing enamel lesion. The last station represents the deepest layer of the carious tooth, with a necrotic, infected root canal system and the presence of apical pathosis. Investigators, clinicians, and researchers who enter the “caries train” have typically focused on only a few stations. They might also have different understandings and opinions about how to treat dental caries. Their opinions have developed from a mixture of clinical empirical tradition and an understanding from research. These opinions could be named the cariologist opinion, the operative opinion, and the endodontic opinion.

Some Opinions about the Approach to Dental Caries

The classic cariologist opinion is focused on the prevention of caries and further progression of the established lesion. The initial focus is on the white spot lesion, whose histologic picture is visualized in the laboratory via transmitted or polarized light. Treatment philosophies here are typically related to nonoperative and preventive approaches. If caries has progressed into the dentin, with demineralized dentin being visible on the x-ray or, at most, extending through half the thickness of the dentin, excavation procedures are planned to avoid pulp exposures.

The operative opinion is typically initiated when caries has progressed into a clinical breakdown of the enamel surface and with carious dentin exposure. Without focusing on specific details about caries pathology, the cavity needs to be “drilled and filled.” A lesion means an exposure of the pulp, and this might be avoided by leaving carious dentin behind. The operative opinion also tends to be a two-edged sword, because sometimes the design of the cavity overrides the fact that the caries lesion might not be in need of operative intervention. However, for esthetic or other reasons, the operative intervention is carried out with a minimally invasive approach, even though the actual lesion is dark, discolored, arrested caries.

Finally, the endodontic opinion deals with the prevention of an infected pulp and subsequent apical pathosis; the issue of a lesion mainly concerns this region. Therefore, all carious dentin should be removed, even if the result is a pulp exposure. The existence of these virtual opinions was reflected in a recent practice-based research network to determine dentists’ treatment methods for deep caries lesions in which one would expect pulpal exposure.¹ The survey findings showed that 62% of the responding dentists would remove all caries (operative opinion), 18% would partially remove caries (cariologist opinion), and 21% would initiate endodontic treatment (endodontic opinion). Differences in decision making for treating deep carious lesions in primary molars have also recently been reported.²

Actually, this topic is not new, as shown in the following quotations: “It is better that a layer of discolored dentin should be allowed to remain for the protection of the pulp rather than run the risk of sacrificing the tooth.”³ In contrast, Black⁴ wrote: “...it will often be a question whether or not the pulp will be

Dr. Bjørndal is associate professor, Department of Cariology and Endodontics, School of Dentistry, Faculty of Health Sciences, University of Copenhagen, Denmark. Correspond with Dr Bjørndal at lb@odont.ku.dk

exposed when all decayed dentin overlaying it is removed... It is better to expose the pulp of a tooth than to leave it covered only with softened dentin.”

It is necessary to remain within the historical perspective to understand how these different opinions have justified various treatment concepts. The endodontic opinion advocating an invasive pulp treatment in relation to caries might very well have gained inspiration from pulp studies carried out on animal models by using standardized test cavities in sound dentin, in which the pulp reacts very early to the influx of various external stimuli. These stimuli might include samples of plaque or soft carious dentin.⁵⁻⁶ In this context, the study by Brännström and Lind⁷ has been a key reference, showing that the early enamel lesion in human teeth could also lead to odontoblast alterations and signs of pulpal infiltration. This is a key reference because in this symposium presentation it is hypothesized that these findings have been used as evidence for the early onset of irreversible pulpal inflammation caused by caries progression. Taken together, it is tempting to suggest that the observation of the “early influx pulp data” might have led to the clinical interpretation that irreversible pulp inflammation is also reached relatively early in relation to caries. Therefore, radical interventions have been advocated. A recent Cochrane review of pulp management in extensive caries deals with clinical studies in which deep lesions without clinical symptoms were treated.⁸ One could question why a pulp-preserving treatment was not an option.

In contrast, the cariologist opinion, and to some extent the operative opinion, can be traced back decades to Massler.⁹ Massler, among others, integrated a sophisticated and advanced biologic understanding of caries into caries treatment. He described acute and chronic caries on the basis of clinical criteria and histologic descriptions. Consequently, different pulpal reaction patterns were to be expected that could lead to differing means of treating caries as opposed to only a radical approach.

With the metaphor of the caries train in mind, it is too much to force everyone to get on and off at all the stations, but during a symposium such as this, a natural goal would be to reach a consensus of understanding caries in between these group opinions. Therefore, when entering a caries discussion aiming to cross invisible lines of dental subspecialties, it is necessary to be clear and precise with the use of well-defined terms. Why? Because the interpretation of the very same clinical situation even today might reflect completely different treatments^{1,2}, and misunderstandings might very well occur in communication between clinicians and researchers. Let us update our understanding of caries pathology by considering that the caries train might use more than one track. This reflects the understanding and importance of caries as a disease that can progress at varying rates.

What is the sequence of the various zones in carious dentin, beginning with early lesions? When and how does the pulp begin to produce extradentinal matrix and tertiary dentin? What is the spreading pattern of caries? When will microorganisms

invade the demineralized dentin? Can we say something about the prehistory of caries, when viewing the histologic picture of tertiary dentin? Why do we sometimes find tertiary dentin produced during caries, whereas at other times it is difficult to detect? Is knowledge about lesion activity important?

An Update of Caries Pathology: The Non-cavitated Enamel Lesion Complex—Understanding the Early Pulp–Dentinal Response to Caries

The proximal white spot lesion is triangular when viewed in 2 dimensions and conical when viewed in 3 dimensions. On the basis of quantitative data related to the degree of porosity in the enamel lesion, the lesion comprises a multitude of many microlesions following the direction of the enamel rods. Hence, the topography of the lesion reflects the acidogenic potential of the cariogenic biofilm at the enamel surface. The central lesion area is the oldest part and shows the deepest penetration, whereas the peripheral parts represent “new beginners” following the direction of the rods.¹⁰

In short, the shape of the enamel lesion represents a transmission of stimuli from the enamel surface that can be related to time and provides the possibility for understanding the subjacent pulpal-dentinal response in relation to time. Thus, the deepest penetration of the entire caries lesion complex can also be seen as the oldest lesion area along the dentin-pulp interface following the direction of the dentinal tubules. Consequently, the peripheral areas represent younger and less progressed areas along the dentin-pulp interface, guided by the cariogenic biofilm covering the surface of the enamel lesion. The morphology of reactionary dentinogenesis, defined as tertiary dentin produced by primary odontoblasts, has been described by using this concept.¹¹ I will return to this subject later.

Examples of Improved Laboratory Methods That Have Created a Better Understanding

One approach that has improved our understanding from the histologic findings of Brännström and Lind⁷ was the use of thin, undemineralized tooth sections in the examination of well-defined carious lesions. The normal structural relationships between enamel, dentin, and the pulp were preserved with this new histologic method. Therefore, it was possible to describe morphologic changes in the enamel and the subjacent pulpal-dentinal organ within the same section.¹² Also, the application of immunohistochemistry has improved our understanding of the underlying molecular events,¹³ as well as reactions leading to reactionary and reparative dentinogenesis.¹⁴

The Sequence of the Carious Development in the Tooth

Morphologic changes in odontoblasts have been found in well-defined enamel lesions in freshly extracted third molars.¹⁴ Moreover, morphologic and molecular features in the odontoblast cells leading to the production of extradentinal matrix can also be detected.¹⁵⁻¹⁶ During our daily clinical practice we might

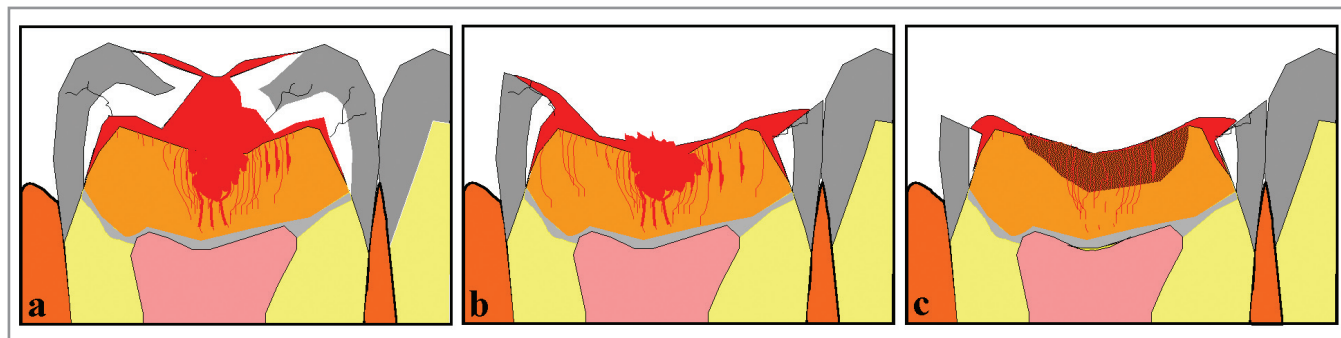


Figure 1. Diagrams showing the temporary conversion of the cariogenic ecosystem during untreated lesion progress. A closed lesion environment develops in relation to an occlusal lesion (a). Eventually the white demineralized and undermined enamel breaks as a result of mechanical stress, changing the environment into an open ecosystem (b). Consequently, a stage of mixed lesion activity develops. In the occlusal part, classic signs of slow lesion progress are noted in terms of a darker appearance of the demineralized dentin, whereas at the margins, optimal growth conditions for the plaque are apparent, and active lesion progress continues (c). Red zones indicate plaque. Reprinted with permission from Blackwell Munksgaard from Bjørndal L. Dentin and pulp reactions to caries and operative treatment: biological variables affecting treatment outcome. *Endodontic Topics* 2002;2:10–23.²²

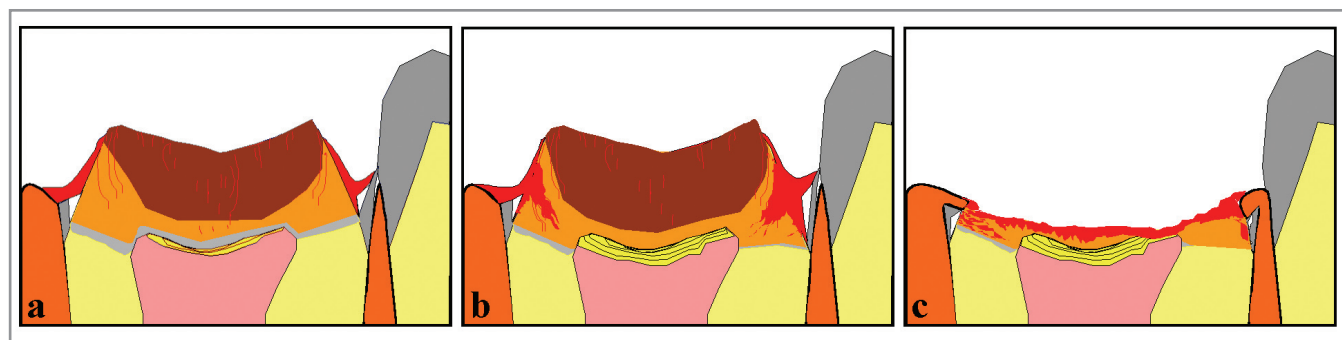


Figure 2. The pattern of untreated deep lesions might involve a decrease in lesion activity (a), but it might be temporary because the enamel margins will obtain protection for the cariogenic process (b). Eventually the entire crown breaks, leaving remnants of roots behind (c). Red zones indicate plaque. Reprinted with permission from Blackwell Munksgaard from Bjørndal L. Dentin and pulp reactions to caries and operative treatment: biological variables affecting treatment outcome. *Endodontic Topics* 2002;2:10–23.²²

only recall the early odontoblast response from the library, but when we experience the pulp in relation to caries, it is during a very late stage of lesion progression as we consider whether pulp exposure should be avoided.

How should we interpret the early pulp response? An updated interpretation and understanding would be that the pulpal response follows the caries lesion from the very beginning. However, it should not be considered as a “station” along the track of irreversible pulp inflammation, hence a “point of no return.” Some observations even indicate that the pulp might react to the signals passing through the enamel even before histologic caries reactions can be observed in the dentin.¹⁴

The first visible histologic change in the dentin subjacent to an enamel lesion is the formation of hypermineralized dentinal tubules. This reaction is seen in the dentin before any signs of demineralization. The reaction might represent activity of the odontoblasts, and it might very well resemble the age-related intratubular physiologic sclerosis.¹⁷ When the enamel lesion reaches the dentinoenamel junction (DEJ), dentin demineralization is initiated. Note that the initial dentin demineralization takes place not in unaffected sound dentin but in dentin with a decreased permeability as a result of the presence of the hypermineralized dentin.

After the dentin begins the process of demineralization, the advancing front of demineralization also reflects the dynamic nature of the cariogenic biofilm, expressed as different pH gradient creating either dissolution or reprecipitation of dentin mineral. Thus, the hypermineralized dentin is probably the result of physiologic activity from the odontoblast, but it also contains reprecipitation of previously dissolved dentin crystals. However, this topic requires additional study.¹⁸

No serious microbial invasion takes place in the dentin as long as the highly organized enamel layer (even though being demineralized) separates the biofilm from the dentin. The bacteria are not able to penetrate through the enamel rod structure.¹⁹ The microbial invasion is related to the gradual structural breakdown of the enamel layer.²⁰

Another important change in our understanding is the misinterpreted concept of caries spreading along the DEJ subjacent the non-cavitated enamel lesion.²¹ The extent of the demineralized dentin is restricted to the histologic enamel lesion contact, and no spreading of demineralized hard tissue is noted undermining sound enamel. The lateral spread of demineralized dentin and enamel is related to the total breakdown of the enamel layer and therefore describes a relatively later stage of tissue destruction than previously believed.

During the stages of dentin exposure a completely different situation is created under heavy bacterial invasion. A moist, soft, disintegrated, demineralized, and necrotic zone is observed. At this active stage the carious dentin can easily be separated from the enamel. The outflux of mineral has been extensive, and as the moisture is decreased, eventually the dentin shrinks, and a clinically visible gap develops between the enamel and dentin (Fig. 1a). Subsequently, the cariogenic biofilm gains improved growth conditions along the lateral spread of caries or retrograde caries.²³ If the carious tooth is left untreated, further tissue breakdown occurs. Eventually the caries process will bring about irreversible changes in the pulp, leading to necrosis and pulpal infection with apical pathosis. This worst case scenario is often what we find in many textbooks. It also represents what takes place several times a week in dental practice. In Denmark caries is still the most frequent reason for endodontic treatment.²⁴

Lesion Activity and Pulpal Response

What is the significance of how rapidly caries progresses in relation to a pulpal response? Let us once again benefit from the histologic findings of the early pulp response to enamel caries.¹⁴ In addition to odontoblast cell reaction *per se*, the odontoblasts also display a different response to active versus arrested caries. When the non-cavitated enamel lesion has histologic contact with the DEJ, the odontoblasts within active lesions have a significantly lower cytoplasm:nucleus ratio compared with control sites. In contrast, this situation is not found in the arrested or slowly progressing enamel lesion. Moreover, only active enamel lesions show evidence of proliferation of cells from the subodontoblastic cell-rich zone into the cell-free zone. In short, the pulpal response follows not only the early caries lesion; it also mirrors changes in lesion activity.

In cavitated lesions, different patterns of tertiary dentin can be expected relative to the prehistory of each lesion. The presence or absence of tertiary dentin, as well as its quality, should be seen as a reflection of the nature of the external stimuli that have previously passed through the dentin. As an additional example, the rapidly progressing caries lesions would typically follow the sequence of odontoblast necrosis²⁵, eventually followed by the presence of atubular dentin formation, also known as fibrodentin. Let us in this context return to the morphology of the reactionary dentinogenesis defined as tertiary dentin produced by primary odontoblasts. A few studies have described this sequence by comparing central and old lesion areas with peripheral and lateral parts of younger lesion areas.^{11,14} It appears that the primary odontoblasts are involved in the early onset of new extradentinal matrix in the younger portions of the lesion, whereas the older central lesion area shows the gradual development of atubular fibrodentin.²⁶

In contrast, slowly progressing lesions characteristically display tubular dentin formation at the pulpal site. This tertiary dentin shows a mixture of reactionary dentinogenesis and dentin produced by new odontoblast-like cells. It appears that

this takes place in the same manner as the primary odontoblast cells, with finger-like projections but into the reactionary dentin.¹⁶ Very little attention has been given previously to the potential capacity of the primary odontoblast to be part of tertiary dentin formation.

Also within deep carious lesions (Fig. 1), large variation in lesion activity might appear.²⁷ As the lesion progresses, the enamel breaks down (Fig. 1b), and at the same time the growth conditions change for the cariogenic biofilm. The cavitated lesion transforms from a closed ecosystem into an open ecosystem (Fig. 1c). Different rates of progression can therefore be present within one tooth. After the enamel breakdown, the occlusal part of the tooth has no heavy plaque accumulation, as the degree of protection of the biofilm has decreased. The subjacent dentin discloses the clinical signs of slowly progressing caries by its brownish discoloration (Fig. 2a). In contrast, the peripheral parts are protected, and accumulations of cariogenic biomass are apparent. On the basis of these observations, pulp vitality is not necessarily maintained, but it indicates that deep exposed dentin lesions are not unconditionally related to an irreversible pattern of pulp pathology, as traditionally taught in textbooks advocating invasive pulp treatments.²⁸ Of course, if nothing is done with the deep lesion even though it might be temporarily arrested, eventually the caries activity in the peripheral parts of the lesion leads to the breakdown of the tooth (Fig. 2b, c).

The pulpal response in lesions with a conversion of lesion activity can be reflected by the presence of reparative dentinogenesis, defined as the combination of fibrodentin and new tubular dentin produced by new odontoblast-like cells.²⁹ The presence of fibrodentin or interface dentin indicates that all primary odontoblasts have died. After the change in caries activity, the pulp might respond with reparative dentin resembling the dentin-bridge formation after a direct pulp capping procedure.¹⁶

Understanding of Caries Pathology Creates the Treatment Philosophy Related to Deep Caries

In the past, the following have all been clear justification for the performance of radical operative intervention: (1) early microbial invasion of carious dentin, (2) early spreading along the DEJ that undermines sound enamel, and (3) the early onset of an irreversible pulp response. Even though textbooks often illustrate the worst case scenario, this does not mean that we should wait for it to happen! We should be motivated to understand the lesion activity and use this information in the treatment of caries. Instead of accepting that there is a steady progression through the tooth leading toward the same results if left untreated, it might be more appropriate to understand that caries activity constitutes many different rates of progression, each of them leading to different pulp reactions. Perhaps with the appropriate clinical intervention we can reduce the rate of caries progression, perhaps even arresting the subjacent pulpal inflammation. Only well-designed clinical trials will answer this question, given that we do not yet have noninvasive

tools for the measurement of the severity of the inflamed pulp. Therefore, the clinical discussion of reversible or irreversible development of pulpitis will continue to be controversial in relation to the actual state of pulp pathology. However, when diagnosing deep carious lesions, we must make a choice on the basis of our knowledge of the caries process and its effect on the pulp and on the basis of existing diagnostic methods. The noninvasive pulp treatment of deep caries lesions will be the focus of my second presentation.

References

- Oen KT, Thompson VP, Vena D, et al. Attitudes and expectations of treating deep caries: a PEARL network survey. *Gen Dent* 2007;55:197–203.
- Qudeimat MA, Al-Saiegh FA, AL-Omari Q, Omar R. Restorative decisions for deep proximal carious lesions in primary molars. *Eur Arch Paediatr Dent* 2007;8:37–42.
- Tomes J. A system of dental surgery. London: John Churchill, 1859:336.
- Black GV. A work on operative dentistry in two volumes, vol. II. The technical procedures in filling teeth. 2nd ed. Chicago: Medico-Dental Publishing Co.;1908.
- Bergenholtz G, Lindhe J. Effect of soluble plaque factors on inflammatory reactions in the dental pulp. *Scand J Dent Res* 1975;83:153–8.
- Mjör IA, Tronstad L. Experimentally induced pulpitis. *Oral Surg* 1972;34:102–8.
- Brännström M, Lind PO. Pulpal response to early caries. *J Dent Res* 1965;44:1045–50.
- Nadin G, Goel BR, Yeung CA, Glennly AM. Pulp treatment for extensive decay in primary teeth. *Cochrane Database Syst Rev* 2003;1:CD003220.
- Massler M. Pulpal reactions to dental caries. *Int Dent J* 1967;17:441–60.
- Bjørndal L, Thylstrup A. A structural analysis of approximal enamel caries lesions and subjacent dentin reactions. *Eur J Oral Sci* 1995;103:25–31.
- Lee Y-L, Liu J, Clarkson BH, Lin C-P, Godovikova V, Ritchie HH. Dentin-pulp complex responses to carious lesions. *Caries Res* 2006;40:256–64.
- Bjørndal L, Thylstrup A, Ekstrand KR. A method for light microscopy examination of cellular and structural interrelations in undemineralized tooth specimens. *Acta Odontol Scand* 1994;52:182–90.
- Yoshihara N, Yoshihara K, Nakamura H, Iwaka M, Ozawa H. Immunohistochemical localization of HLA-DR-positive cells in unerupted and erupted normal and carious human teeth. *J Dent Res* 1996;75:1585–9.
- Bjørndal L, Darvann T, Thylstrup A. A quantitative light microscopic study of odontoblast and subodontoblastic reactions to active and arrested enamel caries without cavitation. *Caries Res* 1998;32:59–69.
- Lukinmaa PL, Vaahtokari A, Vainio S, Thesleff I. Expression of type I collagen pro- α_2 chain mRNA in Adult human permanent teeth as revealed by in situ hybridization. *J Dent Res* 1992;71:36–42.
- Bjørndal L, Darvann T. A light microscopic study of odontoblastic and non-odontoblastic cells involved in tertiary dentinogenesis in well-defined cavitated carious lesions. *Caries Res* 1999;33:50–60.
- Tagami J, Hosoda H, Burrow MF, Nakajima M. Effect of ageing and caries in dentin permeability. *Proc Finn Dent Soc* 1992;88(Suppl 1):149–54.
- Kidd EAM, Bjørndal L, Beighton D, Fejerskov O. Caries removal and the pulpo-dentinal complex. In: Fejerskov O, Kidd EAM, eds. *Dental caries: the disease and its clinical management*. 2nd ed. Oxford: Blackwell Munksgaard, 2008:367–83.
- Ekstrand KR, Bjørndal L. Structural analyses of plaque and caries in relation to the morphology of the groove-fossa system on erupting mandibular third molars. *Caries Res* 1997;31:336–48.
- Ricketts D, Ekstrand KR, Kidd EAM, Larsen T. Relating visual and radiographic ranked scoring systems for occlusal caries detection to histological and microbiological evidence. *Oper Dent* 2002;27:231–7.
- Silverstone LM, Hicks MJ. The structure and ultrastructure of the carious lesion in human dentin. *Gerodontology* 1985;1:185–93.
- Bjørndal L. Dentin and pulp reactions to caries and operative treatment: biological variables affecting treatment outcome. *Endodontic Topics* 2002;2:10–23.
- Bjørndal L, Kidd EAM. The treatment of deep dentine carious lesions. *Dent Update* 2005;32:402–13.
- Bjørndal L, Laustsen MH, Reit C. Root canal treatment in Denmark is most often carried out in carious vital molar teeth and retreatments are rare. *Int Endod J* 2006;39:785–90.
- Magloire H, Bouvier M, Joffre A. Odontoblast response under carious lesions. *Proc Finn Dent Soc* 1992;88 (Suppl.1):257–74.
- Bjørndal L. Presence or absence of tertiary dentinogenesis in relation to caries progression. *Adv Dent Res* 2001; 33:80–3.
- Edwardsson S. Bacteriology of dentin caries. In: Thylstrup A, Leach SA, Qvist V, eds. *Dentine and dentine reactions in the oral cavity* Oxford: IRL Press, 1987:95–102.
- Tronstad L. *Clinical endodontics*. 2nd ed. Stuttgart: Thieme, 2003:81.
- Smith AJ, Tobias RS, Cassidy N, et al. Odontoblast stimulation in ferrets by dentine matrix components. *Arch Oral Biol* 1994;39:13–22.

Conflict of Interest: Lars Bjørndal, DDS, PhD, is a Grant Recipient from the Danish Agency for Science Technology and Innovation.

Copyright © 2008 American Academy of Pediatric Dentistry and American Association of Endodontists. This article is being published concurrently in *Journal of Endodontics* July 2008;34:7S. The articles are identical. Either citation can be used when citing this article.