

# Case Report

## Oral Manifestations of a Possible New Periodic Fever Syndrome

Soraya Beiraghi, DDS, MSD, MS, MSD<sup>1</sup> • Sandra L. Myers, DMD<sup>2</sup> • Warren E. Regelmann, MD<sup>3</sup> • Scott Baker, MD, MS<sup>4</sup>

**Abstract:** Periodic fever syndrome is composed of a group of disorders that present with recurrent predictable episodes of fever, which may be accompanied by: (1) lymphadenopathy; (2) malaise; (3) gastrointestinal disturbances; (4) arthralgia; (5) stomatitis; and (6) skin lesions. These signs and symptoms occur in distinct intervals every 4 to 6 weeks and resolve without any residual effect, and the patient remains healthy between attacks. The evaluation must exclude: (1) infections; (2) neoplasms; and (3) autoimmune conditions.

The purpose of this paper is to report the case of a 4½-year-old white female who presented with a history of periodic fevers accompanied by: (1) joint pain; (2) skin lesions; (3) rhinitis; (4) vomiting; (5) diarrhea; and (6) an unusual asymptomatic, marked, fiery red glossitis with features evolving to resemble geographic tongue and then resolving completely between episodes. This may represent the first known reported case in the literature of a periodic fever syndrome presenting with such unusual recurring oral findings. (*Pediatr Dent* 2007;29:323-6)

KEYWORDS: PERIODIC FEVER, MOUTH LESIONS, GEOGRAPHIC TONGUE, STOMATITIS

The diagnosis of periodic fever syndrome is often challenging in children. Periodic fever syndrome is composed of a heterogeneous group of often hereditary disorders, characterized by recurrent fevers in otherwise healthy individuals.<sup>1</sup> Recurrent infections or neoplasms, along with known autoimmune disorders, must be ruled out as possible underlying causes. There are 5 main types of periodic fever syndromes reported in children that have been identified based on their clinical presentations: (1) periodic fever, aphthous stomatitis, pharyngitis and cervical lymphadenopathy (PFAPA); (2) cyclic neutropenia (CN); (3) hypergammaglobulinemia D (hyper-IgD); (4) familial Mediterranean fever (FMF); and (5) tumor necrosis factor receptor-associated periodic fever (TRAPS). Main clinical features of these conditions are summarized in Table 1.

Oral conditions reported in patients with the periodic fever syndromes previously described include: (1) oral ulcerations; (2) gingivitis; and (3) periodontal destruction. Intraoral aphthous ulcers are a hallmark of PFAPA and present in up to 68% of cases.<sup>2</sup> These are generally minor, small, shal-

low, mildly painful ulcerations, which vary in number, and resolve completely along with other signs and symptoms. Aphthous ulcerations also occur in CN and may progress in size to become deep and painful.<sup>3</sup> Major aphthae (periadenitis mucosa necrotica recurrens or Sutton's disease), gingivitis and periodontal involvement have been reported with CN.<sup>3</sup> Aphthous ulcers have been observed in a minority of hyper Ig-D cases, but oral lesions have not been reported as a significant finding in either FMF or TRAPS. Tongue lesions, other than aphthous ulcers, have not been documented as a significant finding in any periodic fever syndrome. The purpose of this report was to describe a case of periodic fever syndrome in a child with a symptomatic, recurrent, fiery red glossitis, which evolved to resemble geographic tongue and then resolved completely between episodes.

### Case description

A 4½-year-old, well-nourished Caucasian girl was referred to the Pediatric Dental Clinic of the University of Minnesota, Minneapolis, Minn, for evaluation of an unusual recurrent asymptomatic glossitis. The patient's medical history revealed the presence of periodic fevers, occurring at regular 3½ to 4½ week intervals, always with an asthma exacerbation. Clinical signs and symptoms included: (1) arthralgia in the hands and knees; and (2) a fever of 101°F to 104°F lasting for 2 to 3 days.

Significant intraoral findings included a fiery red glos-

<sup>1</sup>Dr. Beiraghi is professor, Department of Developmental and Surgical Science, and head, Division of Pediatric Dentistry, <sup>2</sup>Dr. Myers is associate professor and Director of the National Institute of Dental and Craniofacial Research's Temporomandibular Joint Implant Registry and Repository (TIRR) Laboratory, Department of Diagnostic and Biological Sciences, <sup>3</sup>Dr. Regelmann is associate professor, Department of Pediatrics, Division of Pediatric Pulmonology and Infectious Diseases, and <sup>4</sup>Dr. Baker is associate professor, Department of Pediatrics, Division of Hematology-Oncology and Blood and Marrow Transplant, all at the University of Minnesota School of Medicine, Minneapolis, Minn. Correspond with Dr. Beiraghi at beira001@umn.edu

**Table 1. PERIODIC FEVER SYNDROME DIFFERENTIAL DIAGNOSIS**

CLINICAL PRESENTATION	PERIODIC FEVER, APHTHOUS STOMATITIS, PHARYNGITIS, AND CERVICAL ADENOPATHY	CYCLIC NEUTROPENIA	HYPERGAMMAGLOBULINEMIA D	FAMILIAL MEDITERRANEAN FEVER	TUMOR NECROSIS FACTOR RECEPTOR-ASSOCIATED PERIODIC FEVER
AGE OF ONSET (YEARS)	<5	<1	<1	<10	<1
ABDOMINAL PAIN			X		X
AMYLOIDOSIS				X	X
APHTHOUS STOMATITIS	X		X		
ARTHRALGIA/ ARTHRITIS			X	X	X
CERVICAL LYMPHADENOPATHY	X		X		X
CHILLS	X				
CONJUNCTIVITIS					X
DIARRHEA			X		
ELEVATED IgD/IgA *			X		
ELEVATED ESR †	X				
HEREDITARY		X	X	X	X
MALAISE	X				
MILD LEUKOCYTOSIS	X				
MYALGIA				X	X
ORAL ULCERS	X	X			
PERICARDITIS				X	
PERIODIC NEUTROPENIA		X			
PERIODICITY	<4 weeks	21 days	Variable	?	Variable
PERIORBITAL EDEMA					X
PERITONITIS				X	
PHARYNGITIS	X	X			
PLEURITIS				X	
RASH					X
SEROSITIS				X	
SKIN LESIONS				X	X
VOMITING			X		
THERAPY	Prednisone	RG-CSF ‡	None	Colchicine	Prednisone

\* IgD/IgA: Immunoglobulin D/ Immunoglobulin A † ESR: erythrocyte sedimentation rate  
 ‡ recombinant granulocyte colony stimulating factor

sitis, which over time evolved to resemble geographic tongue and then resolved between episodes (Figures 1-3). Pharyngitis and significant lymphadenopathy were not present. Unusual red cutaneous lesions with crusting were present on the face, arms and nose. The child was the second-born (41 weeks gestation) to nonconsanguineous parents. Prenatal, perinatal, and postnatal histories were unremarkable, and all developmental milestones were within normal ranges. The patient was hospitalized at age 1½ years for vomiting/diarrhea and resultant dehydration. She was hospitalized twice for respiratory syncytial virus (RSV) at ages 2½ and 3½ years.

fever conditions described. PFAPA was ruled out, since the patient did not exhibit aphthous ulcerations or significant cervical lymphadenopathy. Cyclic neutropenia was a consideration because of the unconfirmed family history of neutropenia in a maternal uncle.

Repeated laboratory testing, however, did not confirm the presence of neutropenia, and the patient did not exhibit destructive oral ulcerations or repeated severe infections. Hyper-IgD was considered but laboratory testing never indicated sustained high levels of IgD. The skin lesions did not resemble the erythematous papules, which may be seen in hyper-IgD

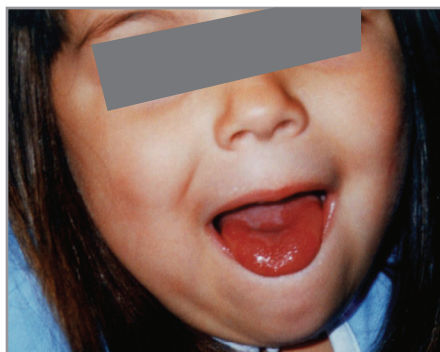

Figure 1. Fiery red glossitis

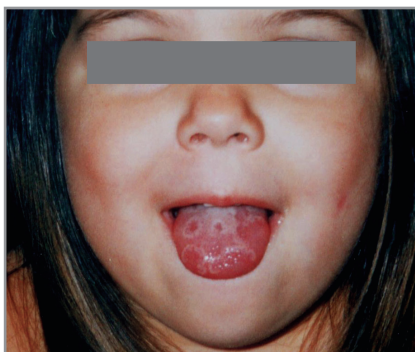


Figure 2. Geographic tongue appearance

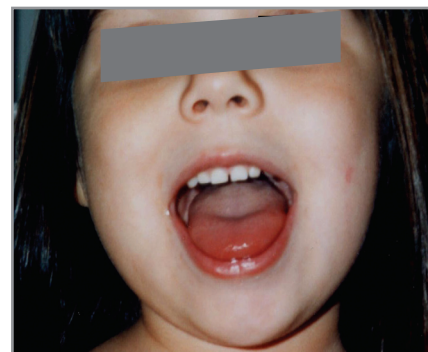

Figure 3. Appearance of tongue between episodes

In 2002, the patient was hospitalized for respiratory distress with tachypnea and a diagnosis of acute exacerbation of severe persistent asthma. She required intubation and mechanical ventilation and remained hospitalized for 10 days. The patient's asthma was subsequently controlled with albuterol and a fluticasone 220 mcg/dose inhaler (2 puffs twice daily). The family history was significant for asthma (mother and maternal uncle). A maternal first cousin's daughter had a low level of IgA, IgE, and IgG. In addition, a paternal uncle reported frequent colds and infections as a youth. A maternal uncle has a diagnosis of neutropenia (not cyclic) as a child, and the maternal grandfather has reactive airways disease. All laboratory results, including repeated neutrophil counts, erythrocyte sedimentation rate, IgA, IgG, IgM, and IgD, were normal. The patient had slightly increased eosinophil counts (13%). Total IgE was increased (514 mg/dl), as was the IgE specific for dog, cat dander, and dust mites.

## Discussion

Pediatric patients with periodic fevers of unknown origin can present a diagnostic challenge for clinicians.<sup>4,5</sup> This is especially true when a child, such as in this case, does not exhibit classical signs and symptoms of a specific disease or syndrome. Infectious diseases, neoplasia, and known autoimmune conditions were ruled out based on clinical testing and laboratory investigations. In addition, the clinical presentation did not fit specifically with any of the 5 main periodic

disease. FMF and TRAPS exhibit less clock-like periodicity than this case and do not have recurrent oral manifestations. Skin lesions, which are erysipelas-like in FMF, and in TRAPS occur as a rash which migrates distally, were not present. In addition, none of the main periodic fever syndromes identified presented with a recurrent glossitis. Her eosinophilia, increased IgE, increased specific IgE, and asthma are suggestive of Churg-Strauss angiitis. The glossitis progressing to geographic tongue, however, has not been described in this disease, and she did not have elevated sedimentation rate.<sup>6</sup>

Glossitis in children may result from a host of local as well as systemic factors. Some local factors include trauma due to injury or burns, sensitivities to foods, topical medications, or oral hygiene products such as toothpastes and mouthwashes.<sup>7</sup> Infections such as candidiasis or primary herpetic gingivostomatitis may also produce a pronounced stomatitis and glossitis. Glossitis due to these local factors is most often symptomatic and transitory, and there is complete resolution without repeating episodes. More persistent forms of glossitis occur with systemic conditions, such as: (1) nutritional deficiencies; (2) some childhood diseases; and (3) blood dyscrasias including neutrophil disorders. Glossitis in such cases may be symptomatic or asymptomatic and is not known to come and go and recur with any regularity. One form of glossitis with an unknown etiology that does come and go and recur over time is geographic tongue.

Geographic tongue is a benign condition that may be

symptomatic, but is often asymptomatic. The condition has been studied as a sign of atopy and has been associated with a history of: (1) asthma; (2) eczema; and (3) hay fever.<sup>8,9</sup> Geographic tongue does occur in children, and its frequency in young children has been typically reported to be around 5%.<sup>10-12</sup> Erythematous, well-demarcated areas of filiform papillary atrophy usually occur on the dorsal or lateral tongue in the anterior two thirds. The lesions expand centrifugally, and yellowish-white, slightly elevated circinate or scalloped borders delineate areas of papillary loss. Lesions of geographic tongue may: (1) appear quickly; (2) heal within a few days or weeks; and then (3) recur in another or adjacent area. Fiery red glossitis preceding development of a geographic tongue has not been reported. White circinate areas on the dorsum of the tongue did not wipe off in this case. Tongue biopsy and candidal smear were not performed, as the child was asymptomatic, and the oral findings appeared nonspecific.

In this case, the patient did not demonstrate the requisite clinical findings to support a diagnosis of any of the major periodic fever syndromes. Family history, clinical characteristics, and phenotype did not provide a sound rationale for undertaking genetic testing. Clinical validity—the accuracy with which a test predicts a particular clinical outcome—is a major consideration in the practice of medical genetics.<sup>13</sup> Clinicians must understand the complexities of genetic testing and the impact of positive, negative, or inconclusive results on patient-perceived risk status and treatment. In addition, ethical, legal, and social implications for both child and family must always be considered before testing is recommended and undertaken.

This is the first known case, to the best of the authors' knowledge, in which a child presented with recurrent episodes of fiery red glossitis in association with periodic fever. The unique clinical findings appear to represent a new periodic fever syndrome and demonstrate why it is imperative for clinicians to evaluate children with unusual oral manifestations for underlying systemic disorders.

### Acknowledgments

The authors would like to acknowledge the contributions of Dr. Shanti Kaimal and Virginia Kelly, RN, in the preparation of this manuscript. Both are associated with the University of Minnesota School of Dentistry, Minneapolis, Minn.

### References

1. Long SS. Distinguishing among prolonged, recurrent, and periodic fever syndromes: Approach of a pediatric infectious diseases subspecialist. *Pediatr Clin North Am* 2005;52:811-35.
2. Pinto A, Lindemeyer RG, Sollecito TP. The PFAPA syndrome in oral medicine: Differential diagnosis and treatment. *Oral Surg Oral Med Oral Pathol Oral Radiol Endod* 2006;102:35-9.
3. Dale DC, Bolyard AA, Aprikyan A. Cyclic neutropenia. *Semin Hematol* 2002;39:89-94.
4. Fietta P. Autoinflammatory diseases: The hereditary periodic fever syndromes. *Acta Biomed Ateneo Parmense* 2004;75:92-9.
5. Lamprecht P, Timmann C, Ahmadi-Simab K, Gross WL. Hereditary periodic fever. *Internist (Berl)*. 2004;45:904-11.
6. Lynch JI, Raghu G. Major Pulmonary disease syndromes of unknown etiology. In: Baum G, Crapo J, Celli B, Karlinksky J, eds. *Baum's Textbook of Pulmonary Diseases*. 6th ed. Philadelphia, Pa: Lippincott-Raven; 1998:450-2.
7. Shulman JD. Prevalence of oral mucosal lesions in children and youths in the USA. *Int J Paediatr Dent* 2005;15:89-97.
8. Marks R, Simons MJ. Geographic tongue: A manifestation of atopy. *Br J Dermatol* 1979;101:159-62.
9. Sigal MJ, Mock D. Symptomatic benign migratory glossitis: Report of two cases and literature review. *Pediatr Dent* 1992;14:392-6.
10. Garcia-Pola MJ, Garcia-Martin JM, Gonzalez-Garcia M. Prevalence of oral lesions in the 6-year-old pediatric population of Oviedo (Spain). *Med Oral* 2002;7:184-91.
11. Vörös-Balog T, Vincze N, Bánóczy J. Prevalence of tongue lesions in Hungarian children. *Oral Dis* 2003;9:84-7.
12. Assimakopoulos D, Patrikakos G, Fotika C, Elisaf M. Benign migratory glossitis or geographic tongue: An enigmatic oral lesion. *Am J Med* 2002;113:751-5.
13. Holtzman N, Watson M. Promoting safe and effective genetic testing in the United States. Final report of the Task Force on Genetic Testing. *J Child Fam Nurs* 1999;2:388-90.