

Clinical Article

Clinical Tips for the Halterman Appliance

David B. Kennedy, BDS, LDS RCS (Eng), MSD, FRCD(C)¹

Abstract: Ectopic eruption of permanent first molars occurs infrequently and causes some resorption of the adjacent primary second molar. The primary second molar can be used as an anchor tooth for the Halterman appliance to disimpact the permanent first molar, provided root resorption is not extreme. A modification of the Halterman appliance is a reverse band and loop appliance with a bonded button on the permanent molar and chain elastic for disimpaction. The purpose of this report was to suggest tips regarding placement and clinical management of this modified Halterman appliance design. (*Pediatr Dent* 2007;29:327-9)

KEYWORDS: ERUPTION, ECTOPIC TOOTH, HALTERMAN APPLIANCE, ORTHODONTICS, INTERCEPTIVE

Ectopic eruption of permanent first molars occurs in 3-4% of children. The maxillary arch is usually affected; only rarely does this occur in the mandible.¹ Etiological factors include a: (1) sibling with ectopic eruption²; (2) shorter smaller maxilla^{3,4}; (3) larger mesiodistal width of the permanent first molar with increased mesial inclination⁴; (4) cleft lip and/or palate⁵; and (5) association with other dental anomalies.⁶

Kennedy and Turley⁷ have described strategies for the clinical management of ectopically erupting permanent first molars. When the primary second molar has not suffered extensive resorption and is symptom free, it is recommended that it be used as an abutment tooth for a Halterman type appliance.^{7,8}

Halterman⁸ described an appliance for correcting impacted permanent maxillary first molars. The primary maxillary second molar is banded with a soldered wire extending distally to the impacted permanent first molar with a recurved hook on the distal extension. A bonded button is attached to the occlusal surface of the permanent first molar (Figure 1). Chain elastic is used from the occlusal button to the recurved hook on the distally extending wire to distalize the impacted molar. The distal extension must be accurately adapted to avoid tissue impingement. This appliance has been very predictable, but

some modifications and clinical tips are offered to enhance clinical success.

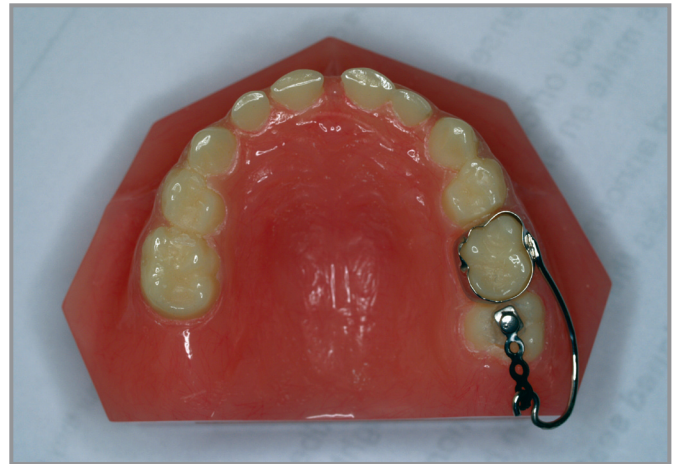

Figure 1. Halterman appliance.

Appliance design

Since the permanent maxillary first molar will often rotate around the palatal cusp coincident with the impaction,⁹ there may be a need to move the impacted molar both distally and to the buccal. Halterman's appliance design does not allow for this directional force. The author's recommended modification is to use a reverse band and loop appliance extending distal to the impacted permanent first molar. The laboratory can be instructed to place 2 spurs on the distal extension: 1 towards the buccal and 1 towards the lingual (Figure 2). Chain elastic can be placed using a catapult or sling shot approach to increase the disimpaction force. The direction of elastic

¹Dr. Kennedy is an orthodontist and pediatric dentist in private practice in Vancouver, BC, Canada.

Correspond with Dr. Kennedy at drdavidkennedy@yahoo.ca

force can be varied, which can assist in improved alignment of the impacted permanent molar. It is imperative that the lab make the extension of the Halterman appliance sufficiently wide mesiodistally to accommodate the full width of the permanent molar. This requires both an accurate impression of the hamular notch and good communication with the lab.

2. reduce occlusal trauma, because the mesial inclination of the impacted molar results in occlusal interference if the bonded button were placed more distally.

Ideally, the bonded button should be placed no further distally than the distal slope of the mesiobuccal cusp of the first permanent molar.

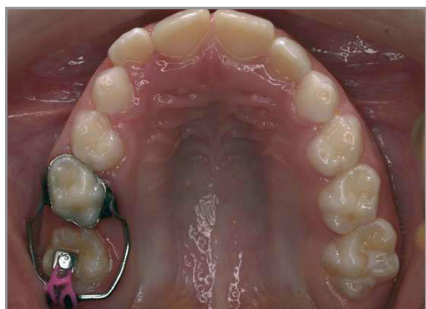


Figure 2. Modified Halterman appliance with reverse band and loop extension, 2 spurs, and an occlusal bonded button with chain elastic placed in a slingshot or catapult pattern.

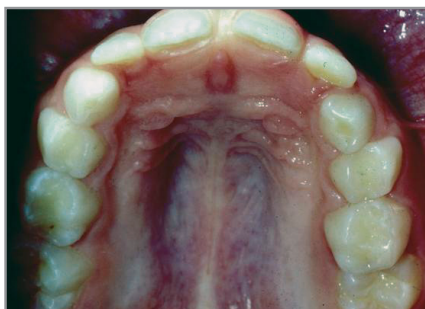


Figure 3. Occlusal view shows impaction of the permanent maxillary left first molar (tooth #14).

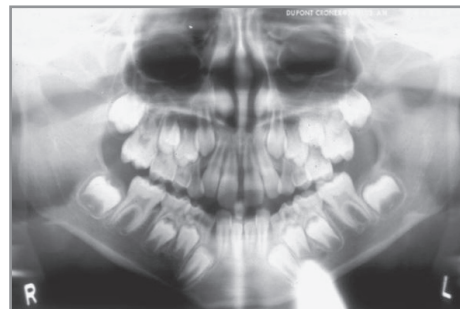


Figure 4. Panoramic radiograph shows impaction of tooth #14.

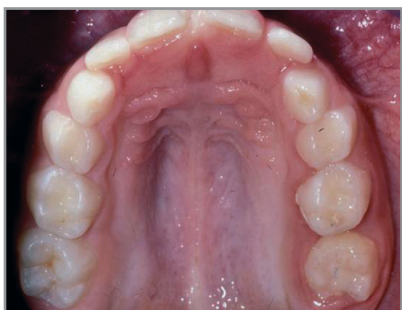


Figure 5. Occlusal view taken 4 months after Figure 2 shows overcorrection of impacted tooth #14.

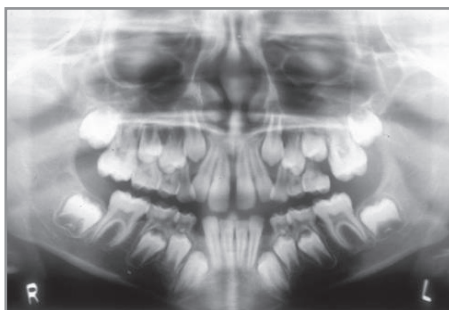


Figure 6. Panoramic radiograph taken 4 months after Figure 3 shows overcorrection of impacted tooth #14. Note root resorption on the adjacent primary second molar.

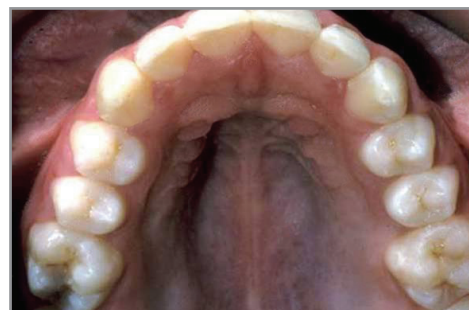

Figure 7. Maxillary occlusal view taken 5 years later shows satisfactory eruption in the permanent dentition.

Placement of the occlusal button

Placing the occlusal button can be challenging in a young mixed dentition patient because of location and isolation during acid etching and placement of the bonded attachment. To facilitate good retention of the occlusal button, the author recommends working with 2 chairside assistants and placing a dry foil in the corner of the mouth for saliva control. One clinical assistant should be responsible exclusively for isolation, and the second assistant should facilitate instrument transfer. Light-cured composite is used to retain the occlusal button because of its quicker set in an area that is difficult to isolate. An alternative would be to use glass ionomer cement.

The occlusal button should be placed as far mesially as possible to:

1. allow greater length of elastic chain to assist the disimpaction; and

Clinical management

After appliance placement, the chain elastic is changed at 2- to 3-week intervals. If the impacted permanent molar needs to be moved to the buccal, the chain is applied from the bonded button to the buccal-soldered spur. For a purely distal movement, the elastic can be stretched from the distal buccal spur to the bonded button and back to the distolingual spur in a catapult or slingshot design, as shown in Figure 2.

Figures 3 to 7 show short- and long-term results with this technique. The impaction is usually corrected within 2 to 4 months (Figures 3 through 6), and over correction is recommended (Figure 6). After disimpaction, the chain elastic is removed and the appliance is left on as the permanent first molar erupts. Once the clinician is assured that the permanent first molar impaction remains corrected, the appliance is removed (Figure 3, 5, and 6). Because root resorption on

the primary second molar has occurred, careful monitoring for premature exfoliation is necessary.⁷ Provided there is adequate space and no premature loss of the primary maxillary second molar, there is satisfactory eruption of the permanent dentition (Figure 7).

References

1. Young DH. Ectopic eruption of the first permanent molar. *J Dent Child* 1957;24:153-62.
2. Bjerklin K, Kurol J. Ectopic eruption of the maxillary first permanent molar: Etiologic factors. *Am J Orthod* 1983;84:147-55.
3. Canut JA, Raga C. Morphological analysis of cases with ectopic eruption of the maxillary first permanent molar. *Eur J Orthod* 1983;5:249-53.
4. Pulver F. The etiology and prevalence of ectopic eruption of the maxillary first permanent molar. *J Dent Child* 1968;35:138-46.
5. Bjerklin K, Kurol J, Paulin G. Ectopic eruption of maxillary first permanent molars in children with cleft lip and/or palate. *Eur J Orthod* 1993;15:535-40.
6. Bjerklin K, Kurol J, Valentin J. Ectopic eruption of maxillary first permanent molars and association with other tooth and developmental disturbances. *Eur J Orthod* 1992;14:369-75.
7. Kennedy DB, Turley PK. The clinical management of ectopically erupting first permanent molars. *Am J Orthod* 1987;92:336-45.
8. Halterman CW. Simple technique for the treatment of ectopically erupting first permanent molars. *J Am Dent Assoc* 1982;105:1031-3.
9. Ackerman JL, Proffit WR. Diagnosis and planning treatment. In: Graber TM, Swain BF, eds. *Current Orthodontic Concepts and Techniques*. Philadelphia, Pa: WB Saunders Co; 1975:51.