



## Light-cured Calcium Hydroxide vs Formocresol in Human Primary Molar Pulpotomies: A Randomized Controlled Trial

Derek Zurn, DDS, MS<sup>1</sup> • N. Sue Seale, DDS, MSD<sup>2</sup>

**Abstract:** **Purpose:** The purpose of this prospective study was to compare light-cured calcium hydroxide (Ca(OH)<sub>2</sub>) with diluted formocresol (FC) for its success as a primary molar pulpotomy medicament. **Methods:** Selection criteria included at least 2 matching, asymptomatic, contralateral primary molars requiring vital pulpotomies. Matched teeth in each patient were randomized to receive either Ca(OH)<sub>2</sub> or FC as a pulpotomy medicament. All teeth were restored with prefabricated metal crowns. Twenty patients (34 pairs of teeth) were followed clinically and radiographically for ≥1 year. Two blinded, standardized, and calibrated examiners evaluated and scored each radiograph for signs of pathology, based upon a modified scale previously proposed. **Results:** Findings were grouped in: (a) 0 - 6; (b) 7 - 12; and (c) 13 - 24 month intervals. Radiographic scoring favored the FC group at the 7- to 12- and 13- to 24-month intervals ( $P < .05$ ). Clinical success was similar for Ca(OH)<sub>2</sub> (94%) and FC (97%) at 12 months or less. Beyond 12 months, clinical success varied more (Ca(OH)<sub>2</sub>=84%, FC=97%), but not significantly ( $P = .08$ ). Combined success rates were lower for Ca(OH)<sub>2</sub> (56%) than FC (94%). **Conclusions:** Light-cured calcium hydroxide does not appear to be a viable alternative to diluted formocresol as a pulpotomy agent. (*Pediatr Dent* 2008;30:34-41) Received September 6, 2006 / Last Revision April 25, 2007 / Revision Accepted April 25, 2007.

KEYWORDS: PULPOTOMY, CALCIUM HYDROXIDE, FORMOCRESOL, PRIMARY MOLAR

Formocresol, first introduced by Buckley in 1904,<sup>1</sup> has long been considered the “gold standard” to which all other medicaments have been compared for primary tooth pulpotomies. It has become the most frequently used medicament, due to its bacteriostatic and fixative properties, with success rates ranging from 55% to 98%.<sup>2-10</sup> This formulation of formaldehyde (a mutagen and carcinogen) and cresol (a caustic agent), however, still raises concerns by dentists and patients, even though its systemic distribution has resulted in no documented ill effects.<sup>11-14</sup> Because of these concerns, alternative pulpotomy agents for primary teeth have been sought.

Calcium hydroxide (Ca(OH)<sub>2</sub>) has been studied as a primary tooth pulpotomy medicament with clinical and radiographic success rates varying from 38% to 94%.<sup>15-24</sup> More recent studies have shown success rates comparable to formocresol in the mid-to-upper 80% range. It has the advantages over formocresol of promoting a healing response and avoiding the issue of systemic uptake. The most frequently reported side effect of Ca(OH)<sub>2</sub> use in primary teeth is internal

resorption. Heilig et al<sup>19</sup> suggested that internal resorption results from an “embolization” process by which particles of Ca(OH)<sub>2</sub> work their way deep into the pulp tissue, forming focal points of inflammation. They attempted to overcome this process by using a hard-setting form of Ca(OH)<sub>2</sub> in 17 teeth. The success rate was 88% for a 9-month observation period.

Visible light-cured materials are available that contain Ca(OH)<sub>2</sub> in a vehicle of light-cured resin that leaches calcium and hydroxyl ions into the surface tissue. The resin vehicle may stabilize the Ca(OH)<sub>2</sub> compound, limiting the breakdown and embolization of the powder and paste forms. This could theoretically minimize the potential for the internal resorption previously observed and improve the success rate of Ca(OH)<sub>2</sub> in primary tooth pulpotomies.

To date, there are no pulpotomy studies using visible light-cured Ca(OH)<sub>2</sub> in primary teeth.

The purpose of this investigation was to compare visible light-cured Ca(OH)<sub>2</sub> with diluted formocresol in pulpotomies performed in asymptomatic, cariously exposed human primary teeth in a randomized controlled trial.

### Methods

Selection criteria for this study consisted of patients with at least 2 matched, contralateral primary molars in the same arch with large carious lesions approximating the pulp, indicating a need for pulpotomy treatment. Inclusion criteria for teeth included:

<sup>1</sup>Dr. Zurn is in private practice in Stoughton, Massachusetts, and <sup>2</sup>Dr. Seale is a Regents Professor and Chairman of the Department of Pediatric Dentistry at the Baylor College of Dentistry, Texas A&M University System Health Science Center, Dallas, Texas.

Correspond with Dr. Zurn at jedidentist@yahoo.com

(1) no history of spontaneous pain; (2) absence of radiographic evidence of internal or external resorption or osseous disease; and (3) the expectation that they would be retained in the arch for at least 2 years.

Twenty-three subjects with 38 matched pairs of teeth were selected from the Department of Pediatric Dentistry, Baylor College of Dentistry Texas A&M Health Science Center, Dallas, Tex. Approval from the Institutional Review Board was obtained. The procedures and possible discomforts, risks, and benefits were explained to the parents of the patients involved, and their informed consents were obtained.

A tooth in each pair was randomly designated by a coin toss to either the experimental/light-cured Ca(OH)<sub>2</sub> or control/formocresol (FC) group, with the contralateral paired tooth being assigned to the other treatment. The pulpotomy procedures were all performed with rubber dam isolation and included: (1) removal of the carious tooth structure and unroofing the pulp chamber with a no. 330 bur; and (2) removal of the coronal pulp tissue with a no. 2 round bur.

All procedures were completed using a high-speed handpiece with water spray. The amputation site was cleaned with a sterile spoon excavator, and hemostasis was obtained using a water-dampened cotton pellet. The amputation site was treated as follows, depending on the group assignment.

**Experimental group.** The amputation site was covered with visible light-cured Ca(OH)<sub>2</sub> (Ultrablend, Ultradent Products, Inc., South Jordan, Utah) and cured according to the manufacturer's recommendations. The remaining pulp chamber was filled with a resin-modified glass ionomer (Vitremmer, 3M ESPE, St. Paul, Minn).

#### Control group.

A cotton pellet dampened with a 1:5 dilution of formocresol (Buckley's Formo Cresol, Sultan Healthcare, Englewood, NJ) was applied to the amputation site for 5 minutes and removed. The pulp chamber was filled with pure zinc oxide and eugenol (ZOE) paste.

All teeth in both groups were restored with prefabricated metal crowns cemented with glass ionomer cement (GC Fuji I, GC America, Inc, Alsip, Ill, or Ketac-Cem, 3M ESPE, St. Paul, Minn). Two standardized operators completed all treatments. One operator completed 21 of the cases (34 pairs of teeth), and the second operator completed 2 cases (4 pairs of teeth) that were treated under general anesthesia.

Table 1. CRITERIA FOR RADIOGRAPHIC SCORING

| Radiographic Score                                            | Definition                                                                                                                                                                                                                                                                                                                                                                                                                                                                                               |
|---------------------------------------------------------------|----------------------------------------------------------------------------------------------------------------------------------------------------------------------------------------------------------------------------------------------------------------------------------------------------------------------------------------------------------------------------------------------------------------------------------------------------------------------------------------------------------|
| 1= No changes present                                         | <ul style="list-style-type: none"> <li>• Internal root canal form is tapering from the chamber to the apex</li> <li>• PDL and periapical regions are of normal width and trabeculation</li> </ul>                                                                                                                                                                                                                                                                                                        |
| 2= Pathological changes of questionable clinical significance | <ul style="list-style-type: none"> <li>• External changes are not allowed (widened PDL, abnormal inter-radicular trabeculation or variation in radiodensity)</li> <li>• Internal resorption is acceptable</li> <li>• Calcific metamorphosis is acceptable and defined as:               <ul style="list-style-type: none"> <li>- Uniformly thin root canal</li> <li>- Shape (non-tapering)</li> <li>- Variation in radiodensity from canal to canal (one cloudier than the other)</li> </ul> </li> </ul> |
| 3= Pathological changes present, observe                      | <ul style="list-style-type: none"> <li>• External changes are present, but not large:               <ul style="list-style-type: none"> <li>- Mildly widened PDL</li> <li>- Minor inter-radicular radiolucency with trabeculation still present</li> <li>- Minor external root resorption</li> <li>- Internal changes are acceptable, but should not be included unless an external change is also present</li> </ul> </li> </ul>                                                                         |
| 4= Pathological changes present, extract                      | <ul style="list-style-type: none"> <li>• Frank radiolucency is present, endangering the permanent successor</li> </ul>                                                                                                                                                                                                                                                                                                                                                                                   |

The study patients were recalled and evaluated clinically and radiographically at 3-month intervals, according to the following 2 criteria:

1. Radiographic criteria: Bitewing and/or periapical radiographs taken at the recall appointments were evaluated for the presence of internal or external resorption, inter-radicular or periapical bone loss, or widening of the periodontal ligament space. The radiographs were classified using a modified scale based on Casas et al.<sup>25</sup>
  - a. 1=no changes present; b. 2=pathological changes of questionable clinical significance; c. 3=pathological changes present, follow-up 3 months; and d. 4=pathological changes present, extract immediately (specific criteria used to score teeth are described in Table 1).

2. Clinical criteria: Teeth were evaluated for the presence of pain, soft tissue swelling, mobility, or other signs of clinical disease. Clinical signs were scored in a manner similar to the radiographic scale:

- a. 1=asymptomatic; b. 2=minor discomfort without clinical signs of disease, follow-up 3 months; and c. 3=clinical signs of irreversible disease (percussion sensitivity, spontaneous pain, mobility, abscess, etc), extract immediately.

All postoperative radiographs were digitally scanned and evaluated by 2 standardized and calibrated examiners. To blind the examiners to the treatment regimens, the coronal portions were blackened-out (Figures 2-4). There was a high level of reproducibility between the 2 examiners ( $\kappa=0.8$ ) following calibration. Radiographic and clinical scores were compared for the matched pairs of teeth using the Wilcoxon signed-rank test (SPSS v. 12.0, SPSS Inc, Chicago, Ill) for each of the

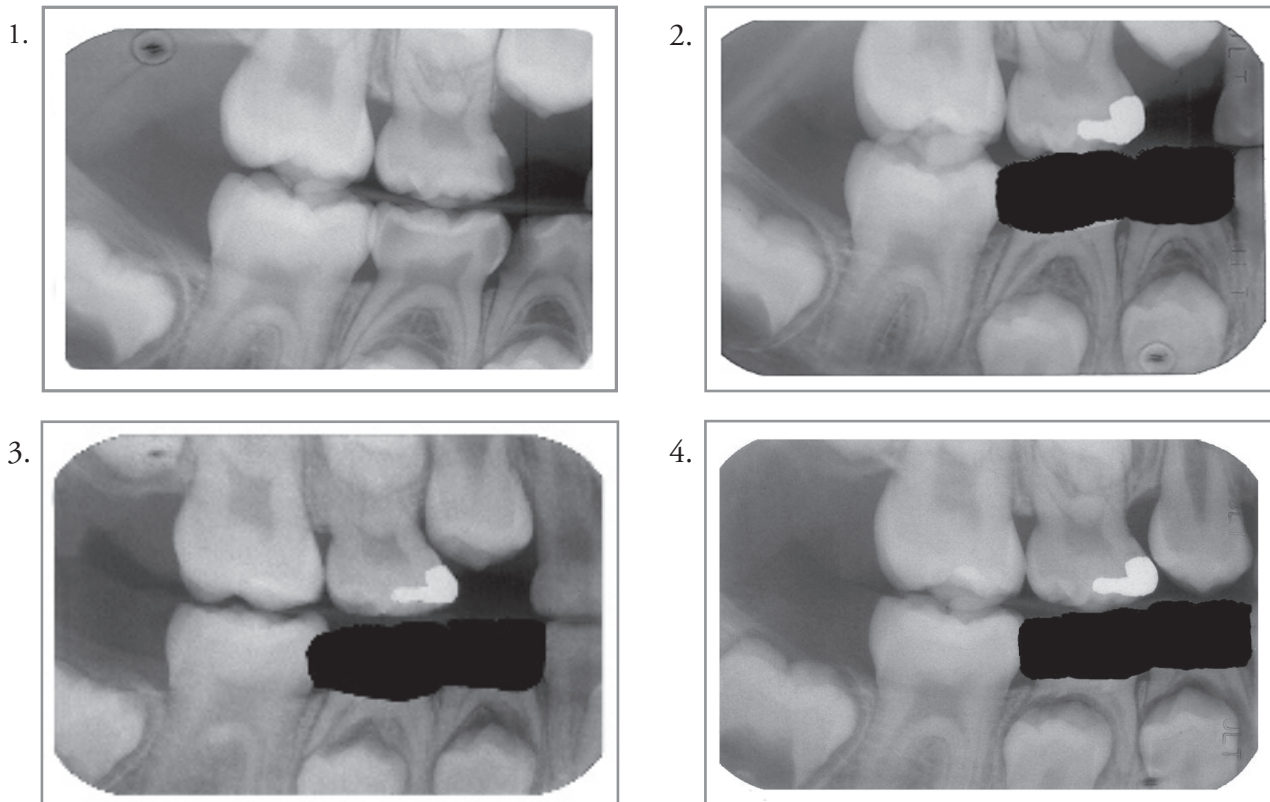


Figure 1. Pre-treatment radiograph.\*

Figure 2. Internal resorption present at 3-month recall in the mesial root of tooth S and distal root of tooth T. Possible dentinal bridging beginning in the mesial root of T.

Figure 3. Internal resorption stabilizes and begins to calcify by 6 months.

Figure 4. Teeth are maintained and survive 18 months.

\* Radiographs were digitally blinded for analysis due to the differing radiodensities of the formocresol treated teeth vs. light-cured calcium hydroxide.

observation intervals. The cumulative rate of failure due to clinical abscesses or osseous radiolucencies was calculated for each treatment, as was an overall cumulative rate of success. These calculations were based on the following equation<sup>26</sup>:

$$\text{Failure percentage} = 100\% \times \frac{(\text{previous failures} + \text{new failures})}{(\text{previous failures} + \text{currently examined teeth})}$$

### Results

Of the original 23 study patients, 20 patients (7 females and 13 males) were available for follow-up  $\geq 12$  months. Three patients were lost due to failure to return for follow-up. Patients ranged in age from 2.3 years to 8.5 years, with a mean age of  $5.3 \pm 1.7$  (SD) years. These individuals represented 34 pairs of treated primary teeth: (a) 8 pairs of maxillary first molars; (b) 8 pairs of maxillary second molars; (c) 11 pairs of mandibular first molars; and (d) 6 pairs of mandibular second molars. The follow-up times ranged from 12 to 24 months with a mean of 16.3 months. Observation times were grouped into: (a) 0- 6; (b) 7- 12; and (c) 13-24-month intervals for purposes of reporting.

The number of teeth available for examination was not equal for all observation periods due to a failure of the patients to return for examination or the extraction of teeth with failed pulpotomies. A total of 16 teeth were extracted due to clinical abscesses or osseous radiolucencies. Of these, 2 teeth were from the FC group and 14 from the  $\text{Ca}(\text{OH})_2$  group.

### Radiographic results

A total of 139 radiographs were available for 68 treated teeth. Radiographic findings are summarized in Table 2. The average radiographic scores were higher for the  $\text{Ca}(\text{OH})_2$  group than for the FC group, indicating more radiographic changes for all time periods. These changes were not significant in the 0- 6-month period. The largest variation between the 2 groups for their average scores was at the 7-12-month period, with  $\text{Ca}(\text{OH})_2=2.6$  and  $\text{FC}=1.4$ . This variation was reflected in the median scores ( $\text{Ca}(\text{OH})_2=3$ ;  $\text{FC}=1$ ) and was statistically significant ( $P=.003$ ). The final 13- 24-month recalls showed less disparity in the mean scores for the 2 groups ( $\text{Ca}(\text{OH})_2=2.1$ ;  $\text{FC}=1.6$ ), and their median scores were the same ( $\text{Ca}(\text{OH})_2=2$ ;  $\text{FC}=2$ ). The difference, however, was still significant ( $P=.02$ ).

The scoring system was devised to represent radiographic changes, not to label individual teeth as a “success” or “failure.” To that end, hard tissue deposition and stabilization was noted as observed radiographically in some teeth (Figures 1-4). Among the observations were: (1) possible dentinal bridging (Figure 2); and (2) the deposition of hard tissue following apparent internal resorption (Figures 2 and 3).

The distribution of radiographic changes across observation times and between groups is summarized in Table 3. The 2 most common radiographic findings over time in the FC-treated teeth were calcific metamorphosis (53%) and internal resorption (26%). Calcific metamorphosis was also the most frequently observed change in the Ca(OH)<sub>2</sub>-treated teeth (47%). External resorption and osseous radiolucency were the next most common changes at 41% and 32%, respectively.

As illustrated in Table 3, there were 9 cases of internal resorption in the FC-treated teeth. Over the course of observation, 8 of these presented with or developed calcific metamorphosis, and 1 appeared to return to a visually “normal” state (visually undetectable by radiographs). None of these teeth were lost due to osseous radiolucency or clinical abscess. In the Ca(OH)<sub>2</sub> group, 7 teeth developed internal resorption after treatment. Of these: (a) 1 had a coinciding osseous radiolucency; (b) 1 developed into an osseous radiolucency; (c) 2 developed coinciding external resorption; (d) 2 developed calcific metamorphosis; and (e) 1 reverted to a visually “normal” state.

**Table 2. DISTRIBUTION OF TEETH WITH OSSEOUS RADIOLUCENCIES AND SCORING FOR FORMOCRESOL (FC) VS. LIGHT-CURED CALCIUM HYDROXIDE (Ca(OH)<sub>2</sub>) PULPOTOMIES**

| Treatment                                                                                  | Observation Period |                     |             |                     |              |                     |
|--------------------------------------------------------------------------------------------|--------------------|---------------------|-------------|---------------------|--------------|---------------------|
|                                                                                            | 0-6 Months         |                     | 7-12 Months |                     | 13-24 Months |                     |
|                                                                                            | FC                 | Ca(OH) <sub>2</sub> | FC          | Ca(OH) <sub>2</sub> | FC           | Ca(OH) <sub>2</sub> |
| Teeth with Osseous Radiolucencies (affected teeth/teeth available*)                        | 1/28<br>4%         | 1/26<br>4%          | 0/25<br>0%  | 6/25<br>24%         | 0/29<br>0%   | 2/23<br>9%          |
| Cumulative Total of Teeth with Osseous Radiolucencies (total affected teeth/total teeth) † | 1/34<br>3%         | 1/34<br>3%          | 1/34<br>3%  | 7/34<br>21%         | 1/31<br>3%   | 9/32<br>28%         |
| Mean Score ‡ (1-4)                                                                         | 1.75               | 2.19                | 1.4         | 2.56                | 1.55         | 2.13                |
| Median Score ‡ (1-4)                                                                       | 2                  | 2                   | 1           | 3                   | 2            | 2                   |
| Test Value §                                                                               | -1.481             |                     | -2.956      |                     | -2.292       |                     |
| P-Value                                                                                    | .14                |                     | .003**      |                     | .02**        |                     |

\* Not every patient was available for every recall period.  
 † 34 teeth were observed for at least 12 months. Several were not available after 12 months.  
 ‡ Extracted/Failed teeth were removed from scoring in the study at the time of extraction.  
 § Wilcoxon Signed-Rank Test, 2-tailed, based on positive ranks  
 \*\* Statistically significant at the P<.05 level

**Clinical results**

The mean clinical scores (scale 1-3) for the FC- and Ca(OH)<sub>2</sub>-treated teeth were similar for all observation periods, with the largest disparity being in the 13- to 24-month recall period (FC=1; Ca(OH)<sub>2</sub>=1.3). The median scores were 1 for all groups and periods. The scoring differ-

ences were not statistically significant—even at the 13- to 24-month period, which had the largest scoring disparity. The clinical results are summarized in Table 4.

**Overall success**

Extractions due to osseous radiolucencies without clinical presentation resulted in the elimination of 10 teeth from examination, and were distributed in the following observation periods: (a) 1 FC and 1 Ca(OH)<sub>2</sub> tooth at 0-6 months; (b) 6 Ca(OH)<sub>2</sub> teeth at 7-12 months; and (c) 2 Ca(OH)<sub>2</sub> teeth at 13 to 24 months (Table 2).

**Table 3. DISTRIBUTION AND FREQUENCY OF RADIOGRAPHIC CHANGES OF FORMOCRESOL (FC) AND LIGHT-CURED CALCIUM HYDROXIDE (Ca(OH)<sub>2</sub>) PULPOTOMIES**

| Observation Period            | Radiographic Changes † | Radiographic Score  |      |                        |       |                     |      |                     |       |                                 |      |                      |       |
|-------------------------------|------------------------|---------------------|------|------------------------|-------|---------------------|------|---------------------|-------|---------------------------------|------|----------------------|-------|
|                               |                        | 1                   |      | 2                      |       | 3                   |      | 4                   |       |                                 |      |                      |       |
|                               |                        | No Change           |      | Calcific Metamorphosis |       | Internal Resorption |      | External Resorption |       | Perforating Internal Resorption |      | Osseous Radiolucency |       |
| Treatment                     | FC                     | Ca(OH) <sub>2</sub> | FC   | Ca(OH) <sub>2</sub>    | FC    | Ca(OH) <sub>2</sub> | FC   | Ca(OH) <sub>2</sub> | FC    | Ca(OH) <sub>2</sub>             | FC   | Ca(OH) <sub>2</sub>  |       |
| 0-6 months                    |                        | 13                  | 7    | 8                      | 8     | 5                   | 5    | 2                   | 7     | 0                               | 1    | 2                    | 2     |
| 7-12 months                   |                        | 15                  | 6    | 14                     | 11    | 6                   | 6    | 2                   | 11    | 0                               | 3    | 2                    | 9     |
| 13-24 months                  |                        | 15                  | 8    | 18                     | 16    | 9                   | 7    | 3                   | 14    | 0                               | 4    | 2                    | 11    |
| End Result ‡ (34 teeth total) |                        | 16/34               | 8/34 | 18/34                  | 16/34 | 9/34                | 7/34 | 3/34                | 14/34 | 0/34                            | 4/34 | 2/34                 | 11/34 |
| Overall Frequency (%)         |                        | 47%                 | 5%   | 53%                    | 47%   | 26%                 | 21%  | 9%                  | 41%   | 0%                              | 12%  | 6%                   | 32%   |

\* Not every patient was available for every recall period.  
 † Teeth showing multiple changes were recorded in each category (i.e., a tooth with external resorption and osseous radiolucency was recorded in both categories).  
 ‡ End Result represents the total observed changes in teeth after at least 12 months follow-up.



Table 4. CLINICAL DISTRIBUTION OF ABSCESSSED TEETH AND SCORING FOR FORMOCRESOL (FC) VS. LIGHT-CURED CALCIUM HYDROXIDE (Ca(OH)<sub>2</sub>) PULPOTOMIES

| Treatment                                                                | Observation Period |                     |             |                     |              |                     |
|--------------------------------------------------------------------------|--------------------|---------------------|-------------|---------------------|--------------|---------------------|
|                                                                          | 0-6 Months         |                     | 7-12 Months |                     | 13-24 Months |                     |
|                                                                          | FC                 | Ca(OH) <sub>2</sub> | FC          | Ca(OH) <sub>2</sub> | FC           | Ca(OH) <sub>2</sub> |
| Abscessed Teeth<br>(affected teeth/teeth available*)                     | 1/28<br>4%         | 1/26<br>4%          | 0/25<br>0%  | 1/25<br>4%          | 0/29<br>0%   | 3/23<br>13%         |
| Cumulative Total Abscessed Teeth<br>(total affected teeth/total teeth) † | 1/34<br>3%         | 1/34<br>3%          | 1/34<br>3%  | 2/34<br>6%          | 1/31<br>3%   | 5/32<br>16%         |
| Mean Score ‡ (1-3)                                                       | 1.07               | 1.14                | 1           | 1.07                | 1            | 1.26                |
| Median Score ‡ (1-3)                                                     | 1                  | 1                   | 1           | 1                   | 1            | 1                   |
| Test Value §                                                             | -.557              |                     | -1.000      |                     | -1.732       |                     |
| P-Value                                                                  | .58                |                     | .32         |                     | .08          |                     |

\* Not every patient was available for every recall period.

† 34 teeth were observed for at least 12 months. Several were not available after 12 months.

‡ Extracted/Failed teeth were removed from scoring in the study at the time of extraction.

§ Wilcoxon Signed-Rank Test, 2-tailed, based on positive ranks

Table 5. OVERALL SUCCESS: A SUMMARY OF CUMULATIVE RADIOGRAPHIC AND CLINICAL RESULTS OF COMPARISON OF FORMOCRESOL (FC) VS CALCIUM HYDROXIDE (Ca(OH)<sub>2</sub>) PULPOTOMIES

| Treatment                                                   | Observation Period |                     |              |                     |              |                     |
|-------------------------------------------------------------|--------------------|---------------------|--------------|---------------------|--------------|---------------------|
|                                                             | 0-6 Months         |                     | 7-12 Months  |                     | 13-24 Months |                     |
|                                                             | FC                 | Ca(OH) <sub>2</sub> | FC           | Ca(OH) <sub>2</sub> | FC           | Ca(OH) <sub>2</sub> |
| Radiographic Cumulative Total of Successful Teeth (Table 2) | 33/34<br>97%       | 33/34<br>97%        | 33/34<br>97% | 27/34<br>79%        | 30/31<br>97% | 23/32<br>72%        |
| Clinical Cumulative Total of Successful Teeth (Table 4)     | 33/34<br>97%       | 33/34<br>97%        | 33/34<br>97% | 32/34<br>94%        | 30/31<br>97% | 27/32<br>84%        |
| Overall Cumulative Total of Successful Teeth*               | 32/34<br>94%       | 32/34<br>94%        | 32/34<br>94% | 25/34<br>74%        | 29/31<br>94% | 18/32<br>56%        |

\* Some teeth had both osseous radiolucencies and clinical abscesses. These dual failures were not counted twice in the overall cumulative total.

Extractions due to clinical abscesses without radiographic presentation resulted in the elimination of 6 teeth from examination, distributed in the following observation periods: (a) 1 FC tooth and 1 Ca(OH)<sub>2</sub> tooth at 0-6 months; (b) 1 Ca(OH)<sub>2</sub> tooth at 7-12 months; and (c) 3 Ca(OH)<sub>2</sub> teeth at 13-24 months (Table 4).

Taking into account all teeth that were extracted, the overall success rates differed for FC (32/34; 94%) and Ca(OH)<sub>2</sub> (25/34; 74%) at 12 months or less. After 12 months, overall success showed more variation between FC (29/31; 94%) and Ca(OH)<sub>2</sub> (18/32; 56%). Thirty-one FC teeth and 32 Ca(OH)<sub>2</sub> teeth were followed for longer than 12 months. These findings are described by observation time period and by cumulative outcome in Table 5.

## Discussion

This investigation intended to compare the success of pulpotomies performed using visible light-cured Ca(OH)<sub>2</sub> with those performed using the gold standard formocresol. It was hypothesized that this more stable form of Ca(OH)<sub>2</sub> would promote healing and eliminate the chronic inflammation seen when the powdered and hard-setting forms break down and embolize. This investigation's results, however, do not demonstrate an improved radiographic or clinical success with the visible light-cured form of Ca(OH)<sub>2</sub>. The success rates observed in this investigation with the Ca(OH)<sub>2</sub>-treated teeth are:

1. comparable with:
  - a. Huth et al,<sup>24</sup> both clinically (84% vs 87%) and overall (56% vs 53%);
  - b. Gruythuysen et al's<sup>21</sup> 1-year results (88%); and
  - c. Fishman et al<sup>20</sup> (81% clinical, 57% radiographic); and
2. not as successful as Heilig et al<sup>19</sup> (88%) or Sasaki et al<sup>23</sup> (88%).

All of these studies utilized some form of a powdered mixture or paste of Ca(OH)<sub>2</sub>. Only Fishman et al<sup>20</sup> reported a sizable number of cases of internal resorption (19% vs this study's 21%). Of these studies, it should be noted that Huth et al had the only other randomized controlled trial with greater than a 1-year follow-up, similar to this study, and their findings were nearly identical.<sup>24</sup>

There were several limitations of this study that were difficult to overcome. The most significant issue was the limited sample size. Patient inclusion criteria were strict. To obtain an adequate number of patients, children requiring treatment under general anesthesia were included, which created another limitation.

These children were treated in an operating room setting due to behavioral difficulties, which made clinical follow-up examinations difficult, and radiographic follow-up even more so. This is why the clinical and radiographic sample sizes did not match during many of the time periods. Ideally, the sample size would need to be much larger, with patients exhibiting a higher level of cooperation, to improve this study.

When using an agent such as Ca(OH)<sub>2</sub> that requires a healing response for success, the histological status of the pulp may be the ultimate determinant of the final outcome. For healing to occur with Ca(OH)<sub>2</sub>, the pulp tissue at the medication interface must be normal enough to remain vital and form a dentinal bridge. The original premise of the pulpotomy

technique was that, by amputating the coronal pulp tissue, all irreversibly inflamed or infected pulp tissue is removed and the remaining radicular tissue is normal and vital. Assessing pulpal health, however, must initially be done by the operator using only radiographic and clinical evidence. Visualization of the quality of the tissue removed and the amount and type of hemorrhage provides additional information. At best, these are crude criteria used to predict the health of the pulp. It is highly likely that the teeth diagnosed for treatment with pulpotomy represent a wide range of variability regarding the histological status of the radicular pulp; some are normal and vital and have the potential to heal, but many are not.

In this investigation, at 13-24 months observation time, 56% of the teeth had outcomes indicative of a positive response to  $\text{Ca}(\text{OH})_2$  and probably represent normal and vital radicular pulps. For those that failed radiographically or clinically, perhaps it is the inappropriateness of the medicament choice for the degree of inflammation or infection of the pulpal tissues remaining that is to blame for this failure. Interestingly enough, these "successes" occurred using a material with a neutral pH in both its cured and uncured forms (independent analysis, Baylor College of Dentistry Biomaterials Science Department). This is contrary to the long-held theory that healing with  $\text{Ca}(\text{OH})_2$  occurs as a result of the highly basic and irritative nature of most formulations.

The majority of the pulpotomies resulting in extraction in this investigation were due to necrotic pulps and abscess formation, rather than to internal resorption. Internal resorption was observed during examination in 7 of the  $\text{Ca}(\text{OH})_2$  teeth (21%). Three of these 7 cases reverted to functional, stable pulpal states, while others eventually necrosed and abscessed. These failed cases may represent teeth in which the spread of inflammation into the radicular pulp rendered it incapable of mounting the requisite healing response.

The modified scoring system used in this investigation evaluated radiographs in a manner similar to how many clinicians practice. Rather than grouping all resorptive radiographic changes as "failures," the authors made an effort to delineate more severe changes such as external resorption involving significant osseous radiolucencies from "contained" radiographic changes such as internal resorption and external resorption involving no supporting structures. This is why the analysis of this study's data focused on the scoring system and not the success rates of each medicament. Anecdotal reports indicate that, in the absence of clinical signs, clinicians are frequently reluctant to label a pulpotomy as a "failure" and extract the tooth due to internal resorption or contained external resorption alone. Some teeth in this investigation demonstrated resorptive changes traditionally labeled as "failures" that appeared to "heal" or stabilize over time. The authors feel that Figures 1 to 4 represent such changes. This scoring system allows for observation of such teeth over time, with the potential for the treated tooth to be clinically viable until exfoliation. By using this system, a "black-and-white"

radiographic success rate is avoided, and a degree of increasing severity of change is reported which more accurately reflects the "gray area" of clinical interpretation that practitioners face daily.

Several components of the pulpotomy technique were managed specifically to control for potential sources of failure. Previous investigators used a hemostatic agent to control hemorrhage.<sup>19</sup> In the current investigation, hemostasis was obtained with sterile water rather than using a hemostatic agent such as ferric sulfate that has been associated with signs of internal resorption when used as a pulpotomy agent.<sup>27</sup> The base material used over the treated pulp stumps for the experimental teeth was chosen to limit the pulpal response to the medicament alone. ZOE was not used as a pulp chamber filling material for the  $\text{Ca}(\text{OH})_2$ -treated teeth, as eugenol is irritating to primary tooth pulpal tissues.<sup>28,29</sup> Instead, a resin-modified glass ionomer was used as has been reported in previous pulpotomy studies.<sup>21,23</sup> Prefabricated metal crowns were used to restore the teeth to reduce leakage and pulpotomy failure due to restoration failure, which has occurred previously when multiple restoration types were used.<sup>21</sup>

Formocresol does not promote a healing response and is highly cytotoxic, injuring the tissue at the medicament-tissue interface. It is possible that outcomes of primary tooth pulpotomies performed with formocresol are far less dependent on the health of the radicular tissues than those performed with agents requiring a healing response for a successful outcome. The prospective, randomized nature of this investigation allowed the teeth to be compared between treatment groups regarding the pulps' histological status. The split-mouth design attempted to ensure that the patient would have a similar immune reaction and eliminate interpatient differences in treatment response. The paired-tooth design also attempted to eliminate possible confounders regarding the types of teeth involved (maxillary vs mandibular, first molar vs second molar), as both medicaments would have been equally affected by these factors.

That being said, the sample size may have been too small for the randomization and split-mouth design to compensate for, and there is always the possibility that the teeth treated with  $\text{Ca}(\text{OH})_2$  might have been more inflamed to begin with. The reverse, however, might also be true. Regardless, this study's observations show a significantly higher number of pathological changes in the teeth treated with  $\text{Ca}(\text{OH})_2$ , which may indicate that formocresol can overcome the variability in the histological health of radicular pulp tissue following primary tooth pulpotomies.

Pulpotomy agents that require a healing response may not be applicable to all asymptomatic cariously involved primary teeth. More astute diagnostic tests may be required to choose those teeth with healthy radicular pulps. In the meantime, formocresol still appears to be the most "forgiving" agent with the widest margin for diagnostic error.

## Conclusions

Based on this study's results, the following conclusions can be made:

1. The visible light-cured form of  $\text{Ca}(\text{OH})_2$  does not result in improved clinical or radiographic findings as a primary tooth pulpotomy agent compared with formocresol.
2. Overall success rates at greater than 12 months observation were 94% for formocresol pulpotomies and 56% for  $\text{Ca}(\text{OH})_2$  pulpotomies.
3. The system of radiographic scoring used in this study provides for a new clinically relevant standard by which minimal radiographic changes can be observed over time and not considered failures.

## Acknowledgement

This research project won the Ralph E. MacDonald Award at the 2006 AAPD annual session for the most outstanding research presented by a graduate student.

## References

1. Buckley JP. The chemistry of pulp decomposition, with a rational treatment for this condition and its sequelae. *Am Dent J* 1904;3:764.
2. Berger JE. Pulp tissue reaction to formocresol and zinc oxide-eugenol. *J Dent Child* 1965;32:13-28.
3. Beaver HA, Kopel HM, Sabes WR. The effect of zinc oxide-eugenol cement on a formocresolized pulp. *J Dent Child* 1966;33:381-96.
4. Redig DF. Comparison and evaluation of two formocresol pulpotomy techniques utilizing "Buckley's" formocresol. *J Dent Child* 1968;35:22-30.
5. Morawa AP, Straffon LH, Han SS, Corpron RE. Clinical evaluation of pulpotomies using dilute formocresol. *J Dent Child* 1975;42:360-3.
6. Rolling I, Thylstrup A. A 3-year clinical follow-up study of pulpotomized primary molars treated with the formocresol technique. *Scand J Dent Res* 1975;83:47-53.
7. Willard RM. Radiographic changes following formocresol pulpotomy in primary molars. *J Dent Child* 1976;43:414-5.
8. Magnusson BO. Therapeutic pulpotomies in primary molars with the formocresol technique. *Acta Odontol Scand* 1978;36:157-65.
9. Fuks AB, Bimstein E. Clinical evaluation of diluted formocresol pulpotomies in the primary teeth of school children. *Pediatr Dent* 1981;3:321-4.
10. Verco PJW, Allen KR. Formocresol pulpotomies in primary teeth. *J Int Assoc Dent Child* 1984;15:51-5.
11. Lewis BB, Chestner SB. Formaldehyde in dentistry: A review of mutagenic and carcinogenic potential. *J Am Dent Assoc* 1981;103:429-34.
12. Hill SD, Berry CW, Seale NS, Kaga M. Comparison of antimicrobial and cytotoxic effects of glutaraldehyde and formocresol. *Oral Surg Oral Med Oral Pathol* 1991;71:89-95.
13. Myers DR, Shoaf HK, Dirksen TR, Pashley DH, Whitford GM, Reynolds KE. Distribution of  $^{14}\text{C}$ -formaldehyde after pulpotomy with formocresol. *J Am Dent Assoc* 1978; 96:805-13.
14. Burnett S, Walker J. Comparison of ferric sulfate, formocresol, and a combination of ferric sulfate/formocresol in primary tooth vital pulpotomies: A retrospective radiographic survey. *J Dent Child* 2002;69:44-8.
15. Doyle WA, McDonald RE, Mitchell DF. Formocresol versus calcium hydroxide in pulpotomy. *J Dent Child* 1962;29:86-97.
16. Schröder U. A 2-year follow-up of primary molars, pulpotomized with a gentle technique and capped with calcium hydroxide. *Scand J Dent Res* 1978;86:273-8.
17. Schröder U, Szpringer-Nodzack M, Janicha J, Wacinska M, Budny J, Mlosek K. A one-year follow-up of partial pulpotomy and calcium hydroxide capping in primary molars. *Endod Dent Traumatol* 1987;6:304-6.
18. Schröder U, Granath L-E. On internal dentine resorption in deciduous molars treated by pulpotomy and capped with calcium hydroxide. *Odontol Revy* 1971;22:179-88.
19. Heilig J, Yates J, Siskin M, McKnight J, Turner J. Calcium hydroxide pulpotomy for primary teeth: A clinical study. *J Am Dent Assoc* 1984;108:775-8.
20. Fishman SA, Udin RD, Good DL, Rodef F. Success of electrofulguration pulpotomies covered by zinc oxide and eugenol or calcium hydroxide: A clinical study. *Pediatr Dent* 1996;18:385-90.
21. Gruythuysen RJ, Weerheijm KL. Calcium hydroxide pulpotomy with a light-cured cavity-sealing material after two years. *J Dent Child* 1987;64:251-3.
22. Waterhouse PJ, Nunn JH, Whitworth JM, Soames JV. Primary molar pulp therapy-histological evaluation of failure. *Int J Paediatr Dent* 2000;10:313-21.
23. Sasaki H, Ogawa T, Koreeda M, Ozaki T, Sobue S, Ooshima T. Electrocoagulation extends the indication of calcium hydroxide pulpotomy in the primary dentition. *J Clin Pediatr Dent* 2002;26:275-7.
24. Huth KC, Paschos E, Hajek-Al-Khatir N, et al. Effectiveness of 4 pulpotomy techniques: Randomized controlled trial. *J Dent Res* 2005;84:1144-8.
25. Casas MJ, Kenny DJ, Johnston DH, Judd PL. Long-term outcomes of primary molar ferric sulfate pulpotomy and root canal therapy. *Pediatr Dent* 2004;26:44-8.
26. American Dental Association Council on Scientific Affairs. Acceptance program guidelines: Dental and enamel adhesive materials. Chicago, Ill. 2001.

27. Smith NL, Seale NS, Dunn ME. Ferric sulfate pulpotomy in primary molars: A retrospective study. *Pediatr Dent* 2000; 22:192-9.
28. Garcia-Godoy, F. A comparison between zinc oxide-eugenol and polycarboxylate cements on formocresol pulpotomies. *J Pedod* 1982;6:203-17.
29. Magnusson B. Therapeutic pulpotomy in primary molars: Clinical and histological follow-up. II. Zinc oxide-eugenol as wound dressing. *Odontol Revy* 1971;22:45-54.

## Abstracts of the Scientific Literature

### Changes in prefabricated metal crowns after exposure to the oral environment

*The purpose of this study was to examine the morphological and elemental changes of prefabricated metal crowns that were originally in the oral cavity. Seventeen prefabricated primary stainless steel crowns that were exfoliated were examined. For each retrieved crown, a new crown of the same type served as a reference. High vacuum scanning electron microscopy was used to assess the surface morphology on retrieved and new metal crowns while a Si(Li) energy dispersive X-ray micro-analysis detector was used to assess the concentration of elements in the metal. In vivo preformed crowns demonstrated significant surface changes compared to the new crowns. Forty-one percent of retrieved crowns showed minor surface deterioration from biting while 12% had extensive surface changes including perforation. However, there were no significant differences in elemental composition of reference and in vivo aged crowns for 7 elements including iron, chromium, and nickel.*

**Comments:** This study shows that the prefabricated stainless steel crowns are durable but are subjected to tremendous forces in the in vivo environment that can result in surface changes, including plastic deformation. Overall, the in vivo environment does not alter the elemental makeup of the crown since it appears that there is no release of elements from the stainless steel alloy of preformed crowns that are used in everyday practice to restore primary teeth. *RJS*

Address correspondence to Dr. S Zinelis, School of Dentistry, University of Athens, Thivon 2, Goudi 11527, Athens, Greece; e-mail: szinelis@dent.uoa.gr.

**Zinelis S, Lambrinaki T, Kavvadia K, Papagiannoulis L. Morphological and compositional alterations of in vivo aged prefabricated pediatric metal crowns (PMCs). *Dent Mater* 2008;24:216-20.**

21 references

### In vivo detection of non-cavitated occlusal caries lesions

*The aim of this study was to compare the outcome of quantitative laser fluorescence (QLF) and meticulous visual inspection (VI) in detecting non-cavitated carious lesions on occlusal surfaces in adolescents. Thirty-four 15 year-old students participated. Five hundred seventeen cleaned occlusal surfaces were air dried and examined using both QLF and VI. The presence/absence of non-cavitated lesions was independently recorded with both methods. Seventy-nine percent of all untreated surfaces were classified as sound or having a non-cavitated lesion using both methods. On 7% of surfaces a lesion was detected by VI only and on 14% by QLF only. The study demonstrated that QLF detects more non-cavitated lesions and smaller lesions compared to VI.*

**Comments:** Meticulous VI is still the diagnostic method of choice for routine dental examinations. QLF's ability to detect clinically invisible lesions does not significantly improve diagnostic outcomes. However, the potential clinical application of QLF is the possibility of long-term monitoring of non-cavitated carious lesions. *KMM*

Address correspondence to Jan Kuhnisch, Ludwig-Maximilians-Universitat Munchen, Poliklinik fur Zahnerhaltung und Parodontologie, Goethestrabe 70, DE-80336 Munchen, Germany. Tel: +49 89 5160 9302; e-mail: jkuehn@dent.med.uni-muenchen.de.

**Kuhnisch J, Ifland S, Tranaeus S, Hickel R, Stosser L. In vivo detection of non-cavitated caries lesions on occlusal surfaces by visual inspection and quantitative light-induced fluorescence. *Acta Odontologica Scandinavica*, 2007;65:183-8.**

27 references