

Scientific Article

Pediatric Bitewing Film Holder: Preschoolers' Acceptance and Radiographs' Diagnostic Quality

Viviane Santos da Silva Pierro, DDS, MSD¹ • Roberta Barcelos, DDS, MSD² • Ivete Pomarico Ribeiro de Souza, DDS, MSD, PhD³
Rubens Raymundo Jr, DDS, MSD, PhD⁴

Abstract: **Purpose:** The purpose of this study was to evaluate a modified bitewing film holder based on preschoolers' acceptance and the diagnostic quality of radiographic images. **Methods:** Sixty-six 3- to 5-year-old children were radiographed with the modified device. Acceptance was assessed according to their behavior during the radiographic examination and to their perception of the procedure. In only the 4- and 5-year-olds, the children's perception was assessed using a faces scale. Evaluation of the images' diagnostic quality for each quadrant (considering pairs of radiographs) was based on anatomic structures usually present on bitewing radiographs. **Results:** During radiographic examination, 73% of the children were cooperative. As to the patients' perceptions ($n=43$), 74% showed satisfaction with the radiographic examination. The diagnostic quality of radiographic images ($n=66$) was adequate in more than 90% of the cases for all evaluated parameters, except for the visualization of alveolar bone crests (54%) and the absence of proximal overlapping (86%). **Conclusions:** The modified bitewing film holder produced adequate radiographs for almost all parameters and was well accepted by preschoolers. (*Pediatr Dent* 2008;30:342-7) Received March 11, 2007 | Last Revision August 31, 2007 | Revision Accepted August 31, 2007

KEYWORDS: RADIOGRAPHY, BITEWING, ALVEOLAR PROCESS, CHILD, PRESCHOOL

Radiographs are essential diagnostic tools that enable dentists to make adequate decisions and treatment plans. In particular, the bitewing radiographic examination has become an important diagnostic aid for interproximal caries detection and periodontal disease, as it produces an anatomically accurate image of the coronal third of the maxillary and mandibular teeth as well as the interproximal alveolar bone.¹ Therefore, every new child patient should have bitewings taken to detect the presence of dental disease when proximal surfaces of primary teeth cannot be visualized.^{1,2}

This examination may, however, be difficult to perform in children. Not only are their mouths smaller, making it difficult for the film to be positioned, but in some cases there is less tolerance, greater anxiety, and more limited understanding.^{3,4}

Making successful bitewing radiographs of young children demands both good behavior-management techniques and

adequate equipment.² For this reason, the use of film holders facilitates the radiographic procedure because they minimize incorrect film placement, bends in the film, and loss of relationship to the area of interest.⁵ It would appear that if these holders were used more often, the number of repeat radiographs would decrease and patients would thus be spared unnecessary radiation exposure.⁶

In their overview of radiographic film holders, Dixon and Hildebolt concluded that although available devices can be considered adequate for routine clinical use, comfortable film-holding devices providing reliable and accurate measurements have yet to be introduced.⁷ Among available devices used to make bitewing radiographs, the HPL bitewing device,^{4,6} the Rinn holder,⁴ the Eezee Grip film holder² and the Kwik-Bite¹ have all been used with children.

Being able to obtain radiographs without hurting or upsetting the child is important for the child's future dental visits. An unsuccessful first experience increases the chance of future rejection of dental treatment.² Studies of children's acceptance of bitewing positioning devices have been published,^{4,6} but they do not include children under 5. Pitts et al tried to include 3- and 4-year-olds in their study that evaluated children's acceptance of 2 bitewing film holders compared with the freehand technique.⁴ All 10 child subjects, however, refused to have radiographs taken. The authors also stated that their findings should promote the development and evaluation

¹Dr. Pierro is doctoral student of Pediatric Dentistry and ³Dr. de Souza is chairman, both in the Department of Pediatric Dentistry; and ⁴Dr. Raymundo Jr is chairman, Department of Dental Radiology, all in the School of Dentistry, Federal University of Rio de Janeiro, Rio de Janeiro, Brazil; ²Dr. Barcelos is assistant professor, Department of Pediatric Dentistry, School of Dentistry, Salgado de Oliveira University, Niterói, Brazil.

Correspond with Dr. Pierro at vivipierro@gmail.com

of film holders that are sufficiently comfortable for use in children's mouths.

The purpose of this study was to evaluate a modified bitewing film holder based on preschoolers' acceptance and on the diagnostic quality of its radiographic images.

Methods

This study was carried out with 66 preschoolers attending the Pediatric Dental Clinic of the Federal University of Rio de Janeiro, Rio de Janeiro, Brazil, who required bitewing radiographs and did not have any films exposed within the last 6 months. The research protocol was approved by the local Ethical Committee on Human Research.

All patients were adequately protected from secondary radiation by using a lead apron and collar, and all radiographs were taken in the afternoon. Bitewing radiographs were performed by only 1 examiner with a film holder modified from the Kwik-Bite device (Hawe-Neos Dental, Bioggio, Switzerland). Because the Kwik-Bite film holder was designed for both adult and pediatric use, some modifications were made to ensure the best fit for a child's mouth. Figure 1 shows a schematic comparison between the Kwik-Bite device and the modified pediatric bitewing film holder, and Figure 2 presents a photograph of both film holders.

The X ray machine used was a Dabi Atlante (Raios X Spectro, Ribeirão Preto, São Paulo, Brazil) operating at 70 kVp and 10 mA. Kodak Insight films (size 0, F-speed) were exposed for 0.7 second. Processing was performed automatically (Level 360, Flat Co Ltd, Nagareyama, Japan).

Patient acceptance. Preschoolers' acceptance was assessed according to their behavior during the radiographic examination and their perception of the procedure.

Before the examination, guardians were asked about the children's previous experience with radiographs to identify those who had never been submitted to such procedure. Afterward, all the patients were classified as either cooperative or uncooperative. Children who were able to keep the film holder in place without the aid of the professional or guardian and who stayed in the correct position were classified as cooperative. Those who did not manage to have their radiographs taken without aid were classified as uncooperative. The professional usually spent about 5 minutes to reassure those children, but if they maintained their poor behavior, active stabilization was used. The guardian usually held the child's arms and legs, while the professional held the child's head, keeping the film holder in place. Both the guardian and the professional used a lead apron and collar during such exposures.

The patient's perception of the examination was assessed only in 4- and 5-year-olds by using a faces scale modified from the Maunuksele et al scale⁸ that represented satisfaction, indifference, or dissatisfaction (Figure 3). A few minutes were spent before each radiograph was taken to establish rapport with the child and to obtain some notion of the child's understanding of the meaning of those schematic facial expressions. After the examination, the children were instructed to choose the face that best represented how they felt during the procedure.

A previous pilot study with 10 3- to 5-year-old children, performed to validate the scale, showed that 3-year-old children were not able to understand the instructions provided with the faces scale.

Radiographic quality assessment. The radiographs were examined for diagnostic quality with the aid of a black mask placed on an illuminated viewing box. Only 1 trained examiner performed the examination, based on 3 dichotomous criteria:

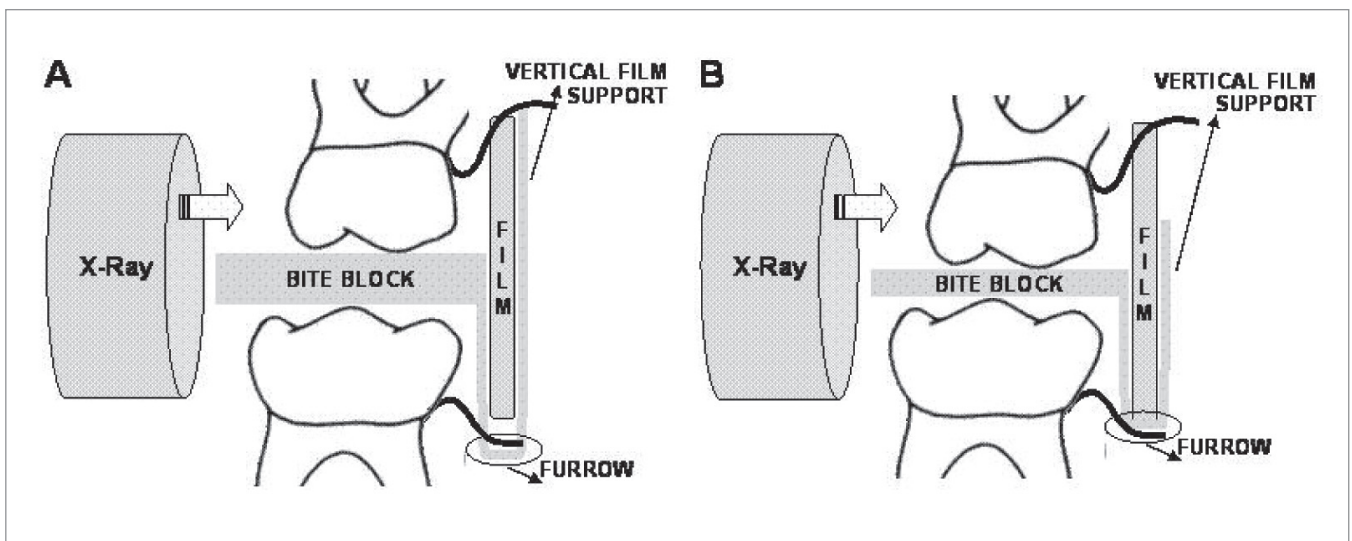


Figure 1. Schematic illustration comparing (A) the Kwik-Bite film holder (Hawe-Neos Dental, Bioggio, Switzerland) with (B) the modified pediatric bitewing film holder. The modified device has a thinner bite block, a vertical film support with reduced height, and a furrow with a smaller extension, especially to fit pediatric films.



Figure 2. The Kwik-Bite film holder, left, and the modified film holder, right.

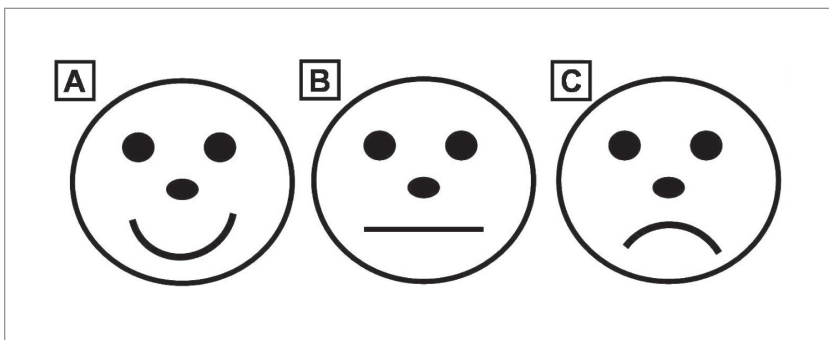


Figure 3. Faces scale modified from the Maunuksela et al⁸ scale showing the 3 schematic faces representing: (A) satisfaction; (B) indifference; and (C) dissatisfaction, respectively.

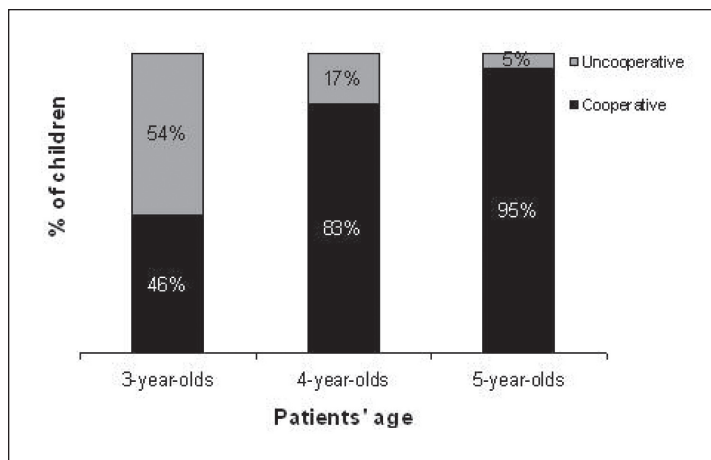


Figure 4. Percentage distribution (%) of children's behavior during radiographic examination according to patients' ages. Mann-Whitney test; $P < .001$.

1. proper film coverage—visualization of the entire crown and the coronal root third of the primary maxillary and mandibular molars and canines;

2. absence of proximal overlapping—observed between primary molars and between primary canines and first molars. Overlapping between 2 adjacent teeth was considered an error if more than one half the depth of enamel, from proximal surface to dentinoenamel junction, was superimposed on the adjacent tooth in at least in 2 different sites.

3. visualization of alveolar crestal bone—visible maxillary and mandibular alveolar crestal bone in the areas cited in 2.

In addition, a global evaluation was performed, based on the sum of errors, which was calculated for each pair of radiographs, including all evaluated criteria.

The reliability of diagnostic quality assessments was tested by a random selection of 13 pairs of radiographs (20% of the total) for double readings, 1 week apart. The kappa statistic was used to assess intraexaminer agreement, which was considered excellent ($\kappa = .94$).⁹

Statistical analysis. Data were analyzed using the SPSS Program, v. 11.0 (SPSS Inc, Chicago, Ill). The Spearman correlation coefficient was used to examine the relationship between 2 numerical variables (patient's age and global evaluation), while the Mann-Whitney test was used to check the relationship between numerical and categorical variables. Two categorical variables were examined either by the Pearson chi-square or Fisher exact test. The significance level was established at 5% ($P < .05$).

Results

The patients who participated in this study ranged from 3 to 5 years old (mean age = 3.92 ± 0.81 years). Among them, 76% ($N = 50$) had never been submitted to an intraoral radiographic examination and 73% ($N = 48$) were classified as cooperative during the examination. The children's behavior was not related to their previous experience with intraoral radiographic examination (Fisher exact test; $P = .52$), as the frequency of children without previous experience was high among both cooperative (73%) and uncooperative (83%) children.

The patients' ages were significantly related to their behaviors during the radiographic examination (Mann-Whitney test; $P < .001$), as the frequency of cooperative children became higher with age (Figure 4).

As to the patients' perceptions ($N = 43$), 74% indicated satisfaction after the examination and all were cooperative during the procedure. Among indifferent children, many

(62%) were also cooperative. On the other hand, most patients who felt dissatisfaction with the procedure (67%) were uncooperative as well. Thus, there was a statistically significant correlation between cooperation and satisfaction with the radiographic examination (Pearson's chi-square test; $P < .001$).

Quadrant	Adequacy (%)		
	Proper film coverage	Absence of proximal overlapping	Visualization of alveolar crestal bone
Maxillary right	92	86	54
Mandibular right	97	92	97
Maxillary left	100	94	92
Mandibular left	100	98	100

After the evaluation of each quadrant, according to our 3 criteria, we verified that all criteria were adequate in more than 90% of the cases, except for the maxillary right quadrant. In this quadrant, only 54% of the radiographs were adequate with respect to visualization of the alveolar crestal bone, and 86% with regard to absence of proximal overlapping, as shown in the Table. All radiographs from the left side were adequate with regard to film coverage, both in the maxillary and mandibular arches, and also concerning visualization of the alveolar crestal bone in all evaluated cases in the mandibular quadrant.

Considering the global evaluation, 41% of the patients had pairs of radiographs without errors, and 36% had just 1 error in 1 of the radiographs. Only 1 child (1%) presented more than 3 errors in his or her pair of radiographs. Although this patient had been uncooperative during the examination, the global evaluation was not related to preschoolers' behavior (Mann-Whitney test; $P = .99$). Cooperative children were the majority among both patients whose radiographs were totally adequate (67%) or among those whose radiographs showed 1 (87%), 2 (67%), or 3 (62%) errors (Figure 5).

Global evaluation (sum of the errors) of bitewing radiographs was not related to patient's age (Spearman correlation coefficient; $P = .82$), although 50% of the radiographs showing 2 or 3 errors belonged to the 3-year-olds (Figure 6).

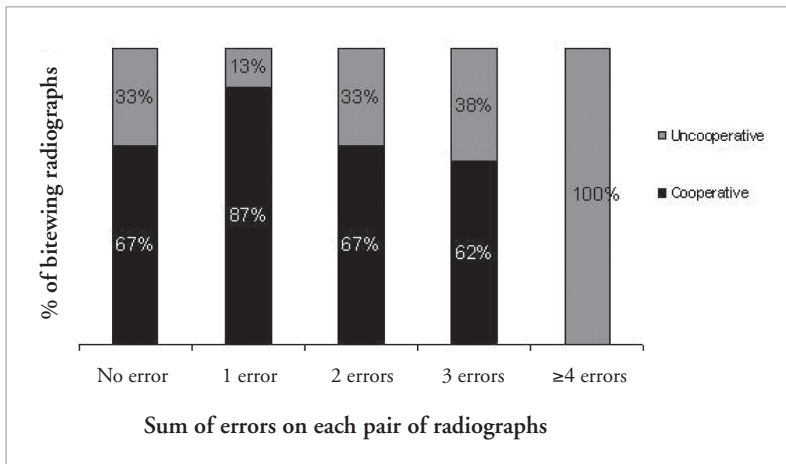


Figure 5. Percentage distribution (%) of global evaluation (sum of the errors) of bitewing radiographs according to preschoolers' behavior during radiographic examination. Mann-Whitney test; $P = .99$.

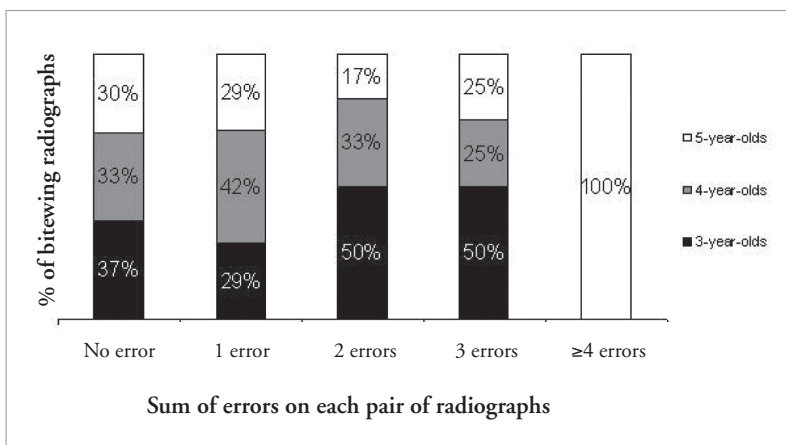


Figure 6. Percentage distribution (%) of global evaluation (sum of the errors) of bitewing radiographs according to patients' ages. Spearman correlation coefficient; $P = .82$.

Discussion

Among the various difficulties that dentists experience in treating preschool children, one of the most serious is that of placing and holding an intraoral radiographic film steady during exposure.¹⁰ For this reason, bitewing film holders have a role to play in children's dentistry whenever bitewing radiographs are indicated, as they simplify and standardize radiographic procedures, thus improving radiographic quality and minimizing technical errors.⁴

The Kwik-Bite film holder has been extensively used in Brazil as part of most Brazilian film holder kits. Nevertheless, although its use has been advocated for both adults and children, clinical practice has demonstrated that its pediatric use is limited to older children. Therefore, some modifications were made in this device to enable its placement in smaller mouths, and an *in vivo* evaluation of the modified device was thought to be worthwhile. Initially, a comparison between the Kwik-Bite and the modified film holder was to be made, but the Kwik-Bite holder simply did not fit preschoolers' mouths because of its size. After placement, children did not manage to bite the bite block.

Postulating that failures in bitewing radiographs might be due to poor technique or poor

patient behavior during the procedure, we designed this study to evaluate not only the diagnostic quality of the radiographs, but also patient's acceptance.

Behavior during radiographic examination was elected as a reliable tool to assess children's acceptance. Because the dental literature usually presents rating scales to determine children's behavior, it was thought that a dichotomous classification based on the necessity for protective stabilization during radiographic examination would be less subjective than the scales.

Children's perception of the modified film holder was also assessed. Due to the preschoolers' lower levels of verbal fluency to communicate their feelings, a faces scale was used for this purpose. Faces scales have been considered the simplest tool to measure the degree of pain or discomfort in young children because they require little abstract ability and they have a range of expressions from smiling to crying.¹¹ No children in this study appeared to have difficulty understanding the instructions provided with the faces scale, except for the 3-year-olds. For this reason, they were not included in this evaluation.

The acceptance level of the bitewing procedure using the modified positioning device was high, with an overall acceptance of 73%. Although this may not be considered remarkable, it should be emphasized that preschool children usually demand behavior management when subjected to dental treatment. Furthermore, the child's age is a very relevant factor in radiographic examinations.⁴

Besides being cooperative, satisfaction was indicated by the majority (74%) of children who took part in the faces scale evaluation (N=43). The radiographic examination could be this age group's first contact with an uncomfortable dental procedure. With this in mind, this satisfaction rate showed that the use of this modified device can contribute not only to obtaining technically adequate radiographs, but also to provide a pleasant experience that could pave the way to adopting a positive attitude toward oral health.

Proper film coverage, absence of overlaps, and visualization of alveolar bone crests are the essential requirements for an acceptable bitewing examination. As for the diagnostic quality of the images, the modified pediatric film holder fulfilled all 3 criteria in more than 90% of the cases, except for the maxillary right quadrant. Errors on the right side were also more frequent when Pitts et al compared freehand and Rinn techniques.⁶ They attributed these errors to the physical difficulty of directly visualizing the film position and alignment of the x-ray cone on the right side compared with the left. In our study, however, the errors were not only more frequent on the right side, but they were specifically located in the maxillary arch of that side. This could be explained by the bilateral use of the device that allows the film to slide down the device's furrow when it is turned upside down to be used on the right side.

Nysether and Hansen found that only 5% of 2,409 pairs of posterior bitewings were error free—the rest exhibited at least 1 technical error.¹² Based on these findings, Pitts et al stated the need to explore any aids capable of reducing the

sizeable number of routinely encountered errors.⁶ These authors demonstrated that the use of the HPL device resulted in reduced numbers of technical errors, when compared with the freehand and Rinn techniques. In our study, 41% of the radiographic pairs were without a single technical error. Although the HPL performed well with older (and probably better behaved) children, we consider our device more suitable because it was successfully used on a younger group (ie, 3- to 5-year-olds).

Therefore, we advocate the modified pediatric bitewing film holder for use in pediatric clinical practice. Although it is not an innovation in the bitewing technique itself, it allows this examination to be performed in preschoolers with comfort and diagnostic quality. Its availability in the dental market, however, is still dependent on negotiation with the manufacturers.

Conclusions

Based on this study's results, the following conclusions can be made:

1. The modified pediatric bitewing filmholder was well accepted by preschoolers.
2. The diagnostic quality of bitewing radiographs was not influenced by the children's behavior. Even uncooperative children were radiographed.
3. The high frequency of errors in the maxillary right quadrant might be related to the modified holder's bilateral use. We suggest that the basic design of the pediatric film holder be maintained, but that its rods be adapted so that one design would be suitable for the right side and one for the left.

References

1. Bogdan MS, Pelzner RB, Kempner D, Moore KE. Extra-oral alignment type bitewing film holder. *Quintessence Int* 1981;12:1307-11.
2. Kaakko T, Riedy CA, Nakai Y, Domoto P, Weinstein P, Milgrom P. Taking bitewing radiographs in preschoolers using behavior management techniques. *J Dent Child* 1999;66:320-4.
3. Bean LR, Isaac HK. X ray and the child patient. *Dent Clin North Am* 1973;17:13-24.
4. Pitts NB, Hamood SS, Longbottom C, Rimmer PA. The use of bitewing positioning devices in children's dentistry. *Dentomaxillofac Radiol* 1991;20:121-6.
5. Bridgman JB, Campbell DJ. An update on dental radiology: Quality and safety. *N Z Dent J* 1995;91:6-21.
6. Pitts NB, Hamood, SS, Longbottom C. An in vivo evaluation in children of the HPL bitewing device. *J Dent* 1989;17:272-8.
7. Dixon DA, Hildebolt CF. An overview of radiographic film holders. *Dentomaxillofac Radiol* 2005;34:67-73.

8. Maunuksela EL, Olkkola KT, Korpela R. Measurement of pain in children with self-reporting and behavioral assessment. *Clin Pharmacol Ther* 1987;42:137-41.
9. Byrt T. How good is that agreement? *Epidemiology* 1996;7:561.
10. Alvares LC. Periapical examination for preschool children. *Oral Surg Oral Med Oral Pathol* 1966;21:47-51.
11. Hain RDW. Pain scales in children: A review. *Palliat Med* 1997;11:341-50.
12. Nysether A, Hansen, BF. Errors on dental bitewing radiographs. *Community Dent Oral Epidemiol* 1983;11:286-8.

Abstracts of the Scientific Literature

Dental amalgam and psychosocial function

High-dose exposure to elemental mercury vapor causes emotional dysfunction, but it is uncertain whether the levels of exposure that result from having dental amalgam restorations do so. A part of the New England Children's Amalgam Trial, a randomized trial involving 6- to 10-year-old children, evaluated the hypothesis that the presence of amalgam restorations resulted in worse psychosocial outcomes than restoration using mercury-free composite resin. The primary outcome was the parent-completed Child Behavior Checklist. The secondary outcome was children's self-reports using the Behavior Assessment System for Children. Children's psychosocial status was evaluated in relation to three indices of mercury exposure: treatment assignment, surface-years of amalgam, and urinary mercury excretion. All significant associations favored the amalgam group. No evidence was found to indicate that exposure to mercury from dental amalgams was associated with adverse psychosocial outcomes over the five-year period following initial placement of amalgams.

Comments: This study shows that the psychosocial status of children who received amalgam restorations is not worse and, in some respects, is better than that of children who received composite resin restoration. **YHW**

Address correspondence to S. McKinlay, New England Research Institutes, 9 Galen Street, Watertown, MA 02472; e-mail: Smckinlay@neriscience.com.

Bellinger DC, Trachtenberg F, Zhang A, Tavares M, Daniel D, McKinlay S. Dental amalgam and psychosocial status: the New England Children's Amalgam Trial. *J Dent Res* 2008; 87:470-4.

32 references

Sealing of sound and caries fissures

Sealing caries fissures is considered an appropriate treatment option for arresting the caries process. However, little information is available regarding the sealing of occlusal cavitated dentin lesions. The hypothesis tested in this in vitro study was that no difference in microleakage and sealant penetration depth exists between cavitated and sound sealed fissures when a resin is used. Eighty molars, each with an occlusal cavitated dentin lesion, were treated according to 5 experimental protocols and compared with a control group of sealed sound molars. In the experimental groups, fissure sealants were placed with and without an adhesive, and in various ways. All teeth were sectioned, and microleakage and sealant penetration into the fissure were evaluated. Sealed caries fissures showed significantly more microleakage and insufficient sealant penetration depth than did sound fissures. Neither the use of an adhesive nor its intermediate curing influenced the microleakage score and the penetration ability of sealants.

Comments: This study indicates that cavitated caries fissures cannot be sealed as adequately as sound fissures and suggests it is likely due to the irregular shapes and the presence of biofilm in cavitated fissures. **YHW**

Address correspondence to M. A. Hevinga, Department of Preventive and Restorative Dentistry, Radboud University Nijmegen Medical Centre, PO Box 9101, NL-6500 HB Nijmegen, The Netherlands; e-mail: m.hevinga@dent.umcn.nl.

Hevinga MA, Opdam NJM, Frencken JE, Bronkhorst EM, Truin GJ. Can caries fissures be sealed as adequately as sound fissures? *J Dent Res* 2008; 87:495-8.

23 references