

# Case Report

## Stainless Steel Crown Aspiration During Sedation in Pediatric Dentistry

A. Adewumi, BDS, MPAedDent<sup>1</sup> • David W. Kays, MD<sup>2</sup>

**Abstract:** Foreign body aspiration (FBA) causes death in more than 300 children every year in the United States. Morbidity and mortality are increased in children due to narrow airways and immature protective mechanisms. Factors to consider in pediatric dentistry are: (1) the patient's age and behavior; (2) presence and extent of disability; (3) local anesthesia; (4) body positioning; and (5) loose teeth. FBA requires prompt recognition and early treatment to minimize potentially serious and sometimes fatal consequences. The purpose of this case report was to describe the aspiration of a stainless steel crown in a 5-year-old boy during conscious sedation. It also discusses how a prompt and accurate diagnosis, early referral, and immediate treatment helped prevent serious complications. (*Pediatr Dent* 2008;30:59-62) Received March 9, 2006 / Last Revision June 1, 2007 / Revision Accepted June 10, 2007.

KEYWORDS: ASPIRATION, PEDIATRIC DENTISTRY, STAINLESS STEEL CROWN

Foreign body aspiration (FBA) is the cause of death for more than 300 children each year in the United States with a higher incidence in boys.<sup>1</sup> Morbidity and mortality tend to be increased in children because they have narrow airways and immature protective mechanisms.<sup>2</sup> A study by Black et al found that 78% of those who die after FBA were between 2 months and 4 years of age.<sup>3</sup> Additionally, Sersar et al stated that FBA was one of the most common and serious problems among children, accounting for 7% of lethal accidents in 1 to 3-year-old children.<sup>2</sup>

The most frequently aspirated objects in children are foods, especially peanuts, followed by nonorganic materials like metals, plastics, or toys.<sup>1</sup> Aspirated foreign bodies tend to become lodged in the right main bronchus,<sup>3</sup> possibly due to the nature of the anatomy of the tracheobronchial tree. Dislodgements in the left bronchus have also been reported.<sup>2</sup>

The common triad of presenting symptoms in an aspiration is coughing, choking and wheezing. Other signs include acute dyspnea and diminished breath sounds.<sup>1-3</sup> Sersar et al<sup>3</sup> suggested that, of all these signs and symptoms, the most predictive is a witnessed aspiration associated with a choking episode—this is referred to as “penetration syndrome.” Aspiration of teeth and restorations is a recognized yet infrequent happening reported in the dental literature. Aspiration

of foreign objects during restorative procedures, especially under sedation, remains a real threat due to the challenges involved with treating young children and the difficulty in airway management.

The purpose of this case report was to describe the aspiration of a stainless steel crown (SSC) in a young child undergoing conscious sedation for restorative dental treatment. It also discusses how an accurate diagnosis prompted early referral for treatment, resulting in a safe outcome for the patient.

### Case report

A healthy 5-year-old boy attended the Department of Pediatric Dentistry of the University of Florida, Gainesville, Fla, for routine restorative dental treatment. The child exhibited extreme anxiety at the initial visit and screening. Following discussion with the child's mother, it was decided that the best treatment option for the patient was the provision of dental treatment using sedation. The patient was in the primary dentition phase, his medical history was unremarkable, airway assessment was normal, and he was considered ASA class I. For treatment to be completed, 4 sedation sessions were scheduled.

The failure of oral midazolam alone to adequately sedate the patient at the first restorative appointment necessitated the use of a combination of midazolam and hydroxyzine<sup>4</sup> for subsequent sedation appointments to increase patient cooperation and gain working time. This combination proved to be successful with this patient, and the sedations were relatively uneventful.

The final appointment involved the placement of an SSC on the primary maxillary left first and second molars.

<sup>1</sup>Dr. Adewumi is an Assistant Professor, Department of Pediatric Dentistry, College of Dentistry, and <sup>2</sup>Dr. Kays is a Pediatric Surgeon, Division of Pediatric Surgery, Department of Surgery, both at the University of Florida, Gainesville, Fla. Correspond with Dr Adewumi at [aadewumi@dental.ufl.edu](mailto:aadewumi@dental.ufl.edu)

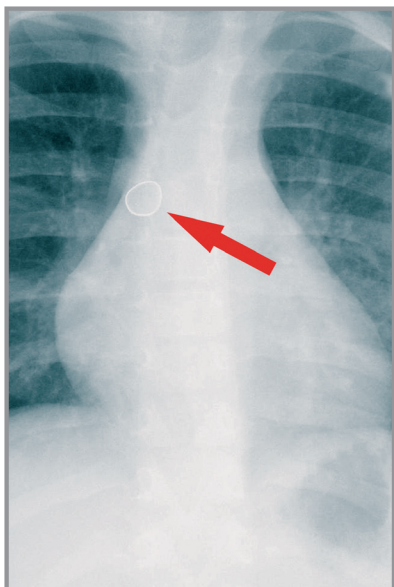


Figure 1. Lateral chest view with the stainless steel crown in place.

On the appointed day, the patient's weight was 18.1 kg. Following informed consent by the mother and verification of no change in the medical history, a combination of 10 mg (0.6 mg/kg) of midazolam with 50 mg (3 mg/kg) of hydroxyzine was given orally. As with previous visits, the patient was placed in a supine position and medically immobilized using a Papoose Board (Olympic Medical, Seattle, Wash) before treatment was initiated.<sup>5</sup> Local anesthesia

was administered in the form of maxillary buccal and palatal infiltrations using 4% Septocaine with epinephrine 1:100,000 (SeptodontUSA, New Castle, Del). A mouth prop was inserted, rubber dam isolation was used, and the primary molars were prepared for SSCs.

To complete the distal preparation of the primary maxillary left second molar, the rubber dam was removed. The appropriate sizes of Ion Crowns (3M ESE, St. Paul, Minn) were, respectively, selected and fitted with a gauze throat shield in place to protect the airway. During the removal of the SSC on the first primary molar prior to cementation, the crown became dislodged distally behind the throat pack into the patient's airway. Following a quick oral exam and high vacuum suctioning, the mouth prop and the Papoose Board were immediately removed. The patient was placed in the prone position with several back slaps to attempt displacement of the crown from his airway. These attempts, followed by the Heimlich maneuver, did not yield the crown.

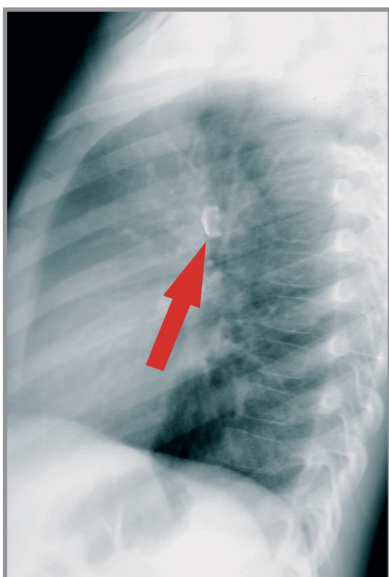


Figure 2. Posterior-anterior view with the stainless steel crown in place.

The initial assessment by the dentist showed that the patient was choking, coughing, and exhibiting mild expiratory wheezing with no obvious signs of respiratory distress. The operator made a provisional diagnosis of FBA. Since the patient showed good air exchange and no further signs of distress, he was moved into a recovery area where his mother was informed of the incident. She was extremely understanding and agreed to our attempts to retrieve the crown. The dentist had a telephone consultation with the pediatric radiologist at Shands hospital at the University of Florida, informed him of her suspicion, and provided him with a concise history of the preceding events followed by a verbal request for a chest radiograph.

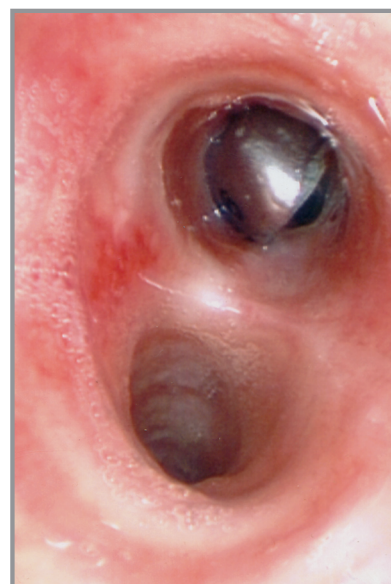


Figure 3. The stainless steel crown is lodged in the right main bronchus.

The patient's respiratory status remained stable, and he was taken in a wheelchair to the hospital's radiology department—escorted by his mother and a dental assistant who was trained in cardiopulmonary resuscitation.

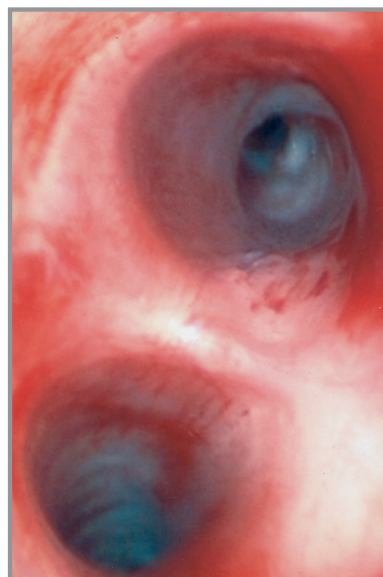


Figure 4. Photograph of the bronchus following removal of the crown.

Upon return to the Department of Pediatric Dentistry and while awaiting the radiologist's results, the patient's condition continued to remain stable. The dentist proceeded to cement new SSCs on the primary maxillary left first and second molars using Fuji I glass ionomer luting cement (GC America, Inc, Alsip, Ill). The radiologist confirmed the diagnosis of FBA over the telephone and informed the dentist of the presence of the SSC in the entrance to the right main stem bronchus (Figures 1 and 2).

The pediatric surgeon on call was immediately contacted, and a diagnostic laryngoscopy with rigid bronchoscopy was performed under general anesthesia to retrieve the foreign body (Figures 3 and 4). The surgery was uneventful, and the patient was discharged home the same day.

## Discussion

This case illustrates the ease with which dental foreign bodies can become dislodged in the airway of a child following routine dental treatment. Children are often referred for sedation because they express extreme behavioral management challenges for the dentist. Though age-appropriate, these behaviors—when coupled with extreme anxiety—make ordinary dental treatment difficult.

The common symptoms of foreign body aspiration are coughing, wheezing, choking, and acute dyspnea.<sup>1-3</sup> These symptoms may spontaneously subside, even when the foreign body remains. Radiographic features depend on the size, location, duration since aspiration, and the nature of the foreign body. Aspiration of foreign body may appear as atelectasis, consolidation, or bilateral over-aeration.<sup>2</sup> Bronchoscopy can be performed for both definitive diagnosis and treatment, if aspiration is suspected. Despite the rarity of these adverse events, aspirations or ingestions in dentistry have been known to occur, typically during cementation of permanent crowns and adjunct procedures such as placement of cast post and core, onlays, and implants.<sup>6</sup> A study by Tiwana and Morton showed that, of the 36 cases of aspiration or ingestion of dental instruments or materials that occurred over a 10-year period, only one involved a true aspiration of a cast post and core.<sup>6</sup> Hodges et al published a case report of a swallowing incident following a fractured solder joint of a dental mirror in an 18-year old developmentally disabled child.<sup>7</sup>

A search of the dental literature did not reveal any reported cases of aspirations in pediatric dentistry. We felt, however, that it was imperative to highlight this case to serve as a reminder that adverse events, though largely preventable, can still occur.

Aspiration or swallowing incidents are more likely to occur when treating a population of young patients with physical, medical, and mental disabilities. These patients often lack cooperative or communicative skills or adequate protective reflexes required for routine dentistry. This often necessitates the use of restraints, sedation, or general anesthesia to achieve a successful outcome of dental procedures. These factors inherently place the patient at more risk for aspiration or swallowing episodes due to their altered state of consciousness. The use of sedation may also be complicated by drug interactions, decreased communication skills, and emesis. Other factors to be considered in pediatric dentistry may include local anesthesia, body and head positioning, loose teeth, loose burs, or instrument fatigue.<sup>7</sup> Aspiration accidents can be minimized by the use of a physical barrier such as rubber dam or gauze throat shields. Alexander and Delholm suggested using dental floss to secure the rubber dam clamp.<sup>8</sup>

Another suggestion is that local anesthesia, especially a mandibular block or palatal anesthesia, can interfere with the sensory or motor control of the pharynx, tongue, and palate.<sup>5</sup> This creates an altered sensation, allowing objects to enter the posterior aspect of the oral cavity, and precipitating an aspiration or swallowing incident. The use of topical anesthetics also contributes to this altered sensory nerve function.

Positioning of the patient is a controversial subject. Some individuals believe the supine position decreases the risk of aspiration or swallowing while others believe this position promotes these incidents.<sup>8,9</sup> While position does play a role, it is often mediated by other associated factors. In the case described, the patient underwent conscious sedation with a combination of midazolam and hydroxyzine. This pharmacological combination has proven successful for producing a mild to moderate sedation level in children.<sup>4</sup>

The combination of these sedatives with palatal anesthesia, the use of restraints, and a supine position, however, may have increased this patient's risk of aspiration in spite of placing a gauze throat shield in the posterior part of the oral cavity. Despite the fact that most aspirations are preventable, Hodges et al described the surprise onset of the object being "lost" or "dropped" into the oral cavity. The use of four-handed dentistry, high-speed suction, ligation of a properly fitted rubber dam clamp, and a gauze throat shield remains the most effective means of preventing aspirations and swallowing materials and loose instruments in dentistry.<sup>7</sup>

Children with behavioral challenges such as attention disorders, severe autism, or extreme and aversive behavioral manifestations—where communication is difficult and restraint is required—also pose an increased risk for aspirations. General anesthesia may be a more viable option for these patients than multiple sedation appointments. Loose primary teeth should be routinely checked, anticipated, and removed if necessary prior to placement of mouth props. Repeated sterilization techniques can result in an increase in instrument wear, leading to failure of soldered joints and disintegration of burs.<sup>7</sup>

Regardless of the reason for the adverse outcome, it is incumbent upon the dentist to be attentive to both early and delayed signs and symptoms of an aspiration accident and act promptly if and when it does occur. In this case, the ability of the dentist to recognize the signs and symptoms of aspiration following failed attempts to retrieve the crown prompted the request of a chest film. Hodges also recommended, in the absence of signs or symptoms of distress by the patient, precise communication with the radiologist following an aspiration or swallowing event with a duplicate sample of the foreign body to accompany the patient. This communication will aid recognition by allowing the appropriate radiographic technique to be selected.<sup>7</sup> Immediate medical and surgical intervention for this patient resulted in the retrieval of the SSC within 2 hours of the incident and a safe discharge from the hospital on the same day. Over the years, professionals in the field of dentistry have worked hard to prevent and minimize adverse events

in the work environment through education and training of dental personnel. Accidents still happen, however, and it is essential that clinicians and their staff remain calm to make prompt decisions and take appropriate actions that will not only prevent potentially serious complications, but may ultimately save their patients' lives.

## References

1. de Oliveira CF, Almeida JF, Troster EJ, Vas FA. Complications of tracheobronchial foreign body aspiration in children: Report of 5 cases and review of literature. *Rev Hosp Clin Fac Med Sao Paulo* 2002;57:108-11.
2. Sersar SI, Hamza UA, Abdel Hameed WA, et al. Inhaled foreign bodies: Management according to early and late presentation. *Eur J Cardiothorac Surg* 2005;28:369-74.
3. Black RE, Johnson DG, Matlack ME. Bronchoscopic removal of aspirated foreign bodies in children. *J Pediatr Surg* 1994;29:682-4.
4. Shapira J, Kupietzky A, Kadari A, Fuks AB, Holan G. Comparison of oral midazolam with and without hydroxyzine in the sedation of pediatric dental patients. *Pediatr Dent* 2004;26:492-6.
5. Frankel RI. The papoose board and mothers' attitudes following its use. *Pediatr Dent* 1991;13:284-8.
6. Tiwana KK, Morton T, Tiwana PS. Aspiration and ingestion in dental practice: A 10-year institutional review. *J Am Dent Assoc* 2004;135:1287-91.
7. Hodges ED, Durham TM, Stanley RT. Management of aspiration and swallowing incidents: A review of the literature and report of case. *J Dent Child* 1992;59:413-9.
8. Alexander RE, Delholm JJ. Rubber dam clamp ingestion—an operative risk: Report of case. *J Am Dent Assoc* 1971;82:1387-9.
9. Cameron SM, Whitlock WL, Tabor MS. Foreign body aspiration in dentistry: A review. *J Am Dent Assoc* 1996;127:1224-9.

## Abstract of the Scientific Literature

### Toothbrushing techniques in orthodontic patients

Since manual toothbrushes with different head designs are still the focus of interest for both manufacturers and clinicians, the aim of this study was to determine whether curved-bristle toothbrushes (CBTs) alone would be more effective in plaque elimination and promoting gingival health than orthodontic toothbrushing protocols in poor-toothbrushing orthodontic patients. The labial surfaces of the maxillary canine-to-canine anterior teeth of 30 patients (12 males and 18 females) were individually photographed following dental plaque staining before and 4 weeks after each toothbrushing protocol, with a 1-month washout interval. The toothbrushes used were: (1) a CBT; (2) an orthodontic toothbrush (OT); and (3) an OT in combination with interproximal toothbrush (OT + IT). OT + IT produced a statistically significant decrease in the mean plaque percentage both for the total labial (7%) and interproximal (18%) tooth surfaces, when compared with the other toothbrushing protocols ( $P < .05$ ). No statistically significant differences were found between the CBT and OT for the amount of bacterial plaque and GI scores ( $P > .05$ ). Neither the CBT nor the OT alone was able to remove plaque under the archwires in poor-toothbrushing patients. Therefore, the use of ITs should be mandatory for effective plaque removal in these patients.

**Comments:** When flossing is compromised due to orthodontic appliances, the use of interproximal toothbrushes should be reinforced not only by orthodontists but also pediatric dentists during regular recalls. **FMS**

Address correspondence to: Dr Selim Arici, Ortodonti Anabilim Dali, Di Hekimli i Fakültesi, Ondokuz Mayıs University, 55139 Kurupelit, Samsun, Turkey; e-mail: sarici@omu.edu.tr.

**Arici S, Alkan A, Arici N. Comparison of different toothbrushing protocols in poor-toothbrushing orthodontic patients. *Eur J Orthod* 2007;29:488-92.**

21 references