

Case Report

Management of an Ectopically Erupting Permanent Mandibular Molar: A Case Report

David B. Kennedy, BDS, LDS, MSD¹

Abstract: Ectopically erupting permanent first molars occur in approximately 3% to 4% of children, and presentation in the mandible is very rare. When the malocclusion warrants a nonextraction treatment plan in the mandible, early correction of an impacted ectopic molar with space regaining is appropriate. The purpose of this case report was to describe and document the correction of a severely impacted permanent mandibular left first molar in the early mixed dentition along with long-term results. A bilateral lingual arch was placed on the primary mandibular second molars with a Halterman-type extension in conjunction with a bonded button on the occlusal surface of the impacted permanent molar and chain elastic. Early space regaining allowed future nonextraction treatment. (*Pediatr Dent* 2008;30:63-5) Received November 6, 2006 / Last Revision March 3, 2007 / Revision Accepted April 13, 2007.

KEYWORDS: ECTOPIC MOLAR, HALTERMAN, LINGUAL ARCH, SPACE REGAINING

Ectopic eruption of permanent first molars occurs in approximately 3-4 % of the population.¹ Commonly, the maxillary arch is affected, with Young reporting only 3 of 78 ectopically erupting permanent first molars occurring in the mandibular arch.¹

Methods have been described for correcting impacted ectopically erupting permanent maxillary first molars.^{2,3} This can be done before premature loss of the primary maxillary second molar or after loss of that tooth.^{2,3} Orthodontic mechanics to distalize permanent maxillary first molars after primary maxillary second molar loss may involve removable appliances³ or fixed appliances, such as the Pendulum, Distal Jet, Jones jig, Niti-coils, or headgear. By contrast, distal movement of permanent mandibular first molars after early loss of primary mandibular second molars is extremely challenging because of reduced anchorage available from mandibular anterior teeth and the presence of denser bone in the mandible. Indeed, a major challenge in orthodontic mandibular arch nonextraction treatment is the avoidance of lower incisor proclination and the prevention of intercanine width expansion with its potential instability.⁴ Therefore, when the clinician is faced with: (1) a mixed-dentition malocclusion that in the long term needs to be treated via nonextraction methods, and (2) space loss from mesial ectopic eruption of a mandibular molar, then early intervention to regain space can be extremely helpful. A literature search revealed no case reports

that demonstrate and document early mixed dentition space regaining in the mandibular arch.

The purpose of this case report was to demonstrate the management of an ectopically erupting permanent mandibular left first molar and to document both short- and long-term results.

Case report

An 8-year-old boy presented with a Class II, Division 2 mixed dentition malocclusion. The primary molar relationship was a half cusp Class II; primary molars and canines exhibited occlusal wear. The maxillary arch demonstrated an absence of crowding, and there was an overbite of 80%. In the mandibular arch, there was premature loss of primary canines and a significant mesial impaction of an ectopically erupting permanent mandibular left first molar (Figure 1). The radiograph demonstrated extensive root resorption on the distal root of the adjacent primary molar (Figure 2). Despite this resorption, the tooth was both firm and symptom free. Radiographs indicated significant leeway space because the retained primary second molars were wider than the unerupted mandibular second premolars (Figure 2). This leeway space could be used to manage the crowding in the region of the unerupted permanent mandibular canines. In general terms, the long-term treatment plan for this patient involved a nonextraction approach because of the Class II, Division 2 deep overbite and minimally crowded malocclusion. For this reason, it was imperative that the permanent molar impaction was corrected to prevent further space loss.

A bilateral appliance was made, as shown in Figure 3, which was taken after treatment had started. At the first visit, separators

¹Dr. Kennedy is an orthodontist and pediatric dentist practicing in Vancouver and Richmond, British Columbia, Canada.

Correspond with Dr. Kennedy at drdavidkennedy@yahoo.ca

were placed mesial to both primary mandibular second molars and also distal to the primary mandibular right second molar. The separators were in place for 1 week. At the second visit, bands were fitted and a mandibular impression was made. The separators were replaced. At the third visit, the appliance was cemented and a button was bonded on the occlusal surface of the impacted permanent molar. Chain elastic was used from the bonded button to the distal extension of the appliance and was replaced at 2- to 3-week intervals (Figure 3). During disimpaction, radiographs were taken that demonstrated complete resorption of the distal root of the retained primary molar (Figure 4). Despite this, the tooth remained firm and symptom free. As the permanent molar was disimpacted, the occlusal button was moved further mesially on the occlusal surface to allow increased elastic force (note position of occlusal button on Figures 3 and 4). The overall time taken to disimpact the permanent molar was 7 months. This relatively long treatment time reflects the severity of the impaction shown in Figure 2.

After the impaction had been corrected, the decision was made to leave the appliance in place because it provided stability to the primary molar, which exhibited extensive root resorption (Figure 5). It also prevented lingual tipping of the mandibular incisors. Subsequent to Figure 5, the occlusal button and distal wire extension were removed, leaving the lingual arch in place. Later on in the mixed dentition, the mandibular lingual arch was converted from bands on the primary second

molars to the permanent first molars (Figure 6). At that time, the primary mandibular right second molar was extracted to utilize available leeway space in the mandibular right quadrant. Subsequently, full fixed appliances were used as second stage treatment with a nonextraction approach.

Discussion

The lack of maxillary crowding, minimal mandibular crowding the deep overbite, and favorable leeway space led to a nonextraction plan (Figures 1, 3, and 6). Class II, Division 2 deep-bite malocclusions are commonly treated with a nonextraction approach in the mandible. Therefore, mandibular arch space regaining was appropriate for the presenting malocclusion, since it would prevent space loss in the mandibular left quadrant. Early aggressive intervention to correct an impacted mandibular molar was successful in achieving the overall treatment goals of completing the patient's treatment without extraction.

The lack of mobility and symptoms in the resorbed primary second molar was a fortunate clinical finding, since it allowed its use as an anchor abutment. The appliance also provided a relatively simple mechanical way of both disimpacting the permanent molar and maintaining the integrity of the resorbed primary molar.

One problem with the appliance was the need to open and close the recurved loop on the distal extension when the chain

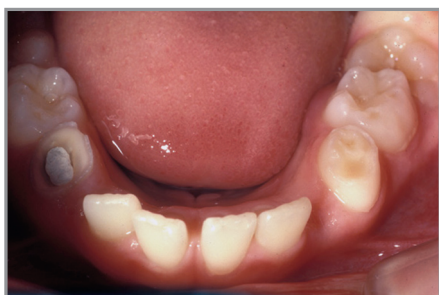

Figure 1. Mandibular occlusal view shows a severe impaction of the permanent mandibular left first molar.

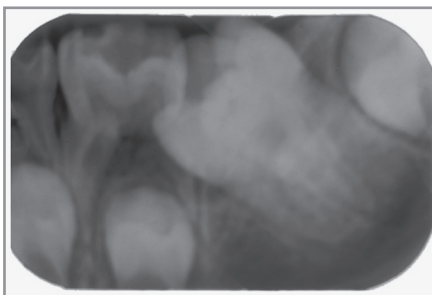


Figure 2. Periapical X ray shows a permanent first molar impaction and extensive distal root resorption of the primary mandibular left second molars. Used with permission.³

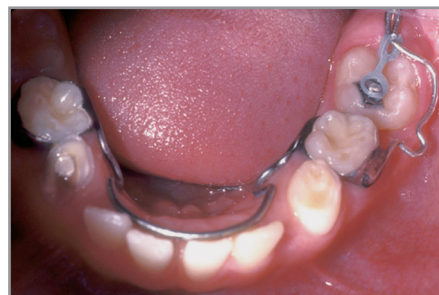

Figure 3. Mandibular occlusal view shows a modified bilateral Halterman appliance. Used with permission.³

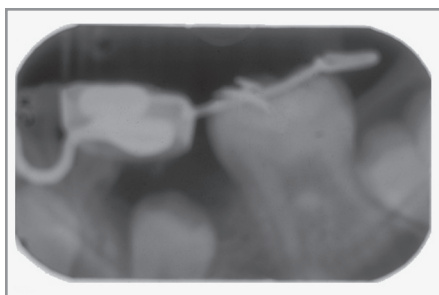


Figure 4. X ray shows total resorption of the distal root of the primary mandibular left second molar and the distal position of the occlusal button. Used with permission.³

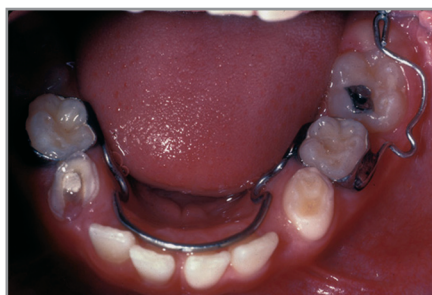

Figure 5. Mandibular occlusal view shows correction of impaction. The lingual arch was retained to stabilize the resorbed primary mandibular left or second molar.

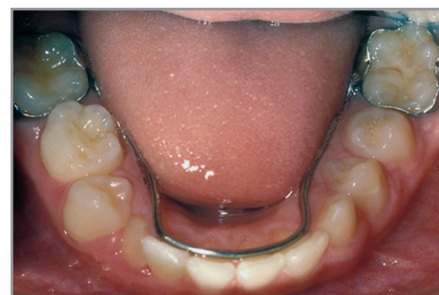

Figure 6. Mandibular lingual arch on the banded permanent first molars.

elastic was changed. When the loop was not fully closed, the chain slipped mesially along the buccally placed extension, thereby applying a buccal, and not distal, disimpacting force. With the benefit of hindsight, a more appropriate appliance design would be to incorporate a reverse band and loop Halterman type of appliance extending from the distal of the primary second molar band with 2 spurs to increase elastic force and vary the direction of force.⁵

References

1. Young DH. Ectopic eruption of the first permanent molar. *J Dent Child* 1957;24:153-62.
2. Halterman CW. Simple technique for the treatment of ectopically erupting first permanent molars. *J Am Dent Assoc* 1982;105:1031-3.
3. Kennedy DB, Turley PK. The clinical management of ectopically erupting first permanent molars. *Am J Orthod* 1987;92:336-45.
4. Burke SP, Silveira AM, Goldsmith LJ, Yancy JM, Van Stewart A, Scarfe WC. A meta-analysis of mandibular intercanine width in treatment and post retention. *Angle Orthod* 1998;68:53-60.
5. Kennedy DB. Clinical tips for the Halterman appliance. *Pediatr Dent*. 2007;29:327-9.

Abstract of the Scientific Literature

The antibacterial effects of mastic gum in orthodontic patients

The aim of this study was to evaluate the antibacterial effect of mastic gum on reducing cariogenic bacteria in patients with fixed appliances. Increased levels of mutans streptococci and lactobacilli have been detected in the oral cavity after bonding orthodontic appliances. Mastic gum, a natural product, is the concrete resinous exudate from the stem of the tree Pistacia lentiscus Linn, which is cultivated on the coast of Turkey. Twenty-five patients age 14±1.0 years with edgewise appliances were selected for the study. Baseline unstimulated saliva samples were collected immediately after placing the brackets in the upper and lower arches. The same patients were used in 2 sequential weeks. During the first week, paraffin wax was used as a control. The following week, the patients chewed mastic gum. Saliva samples were collected at 30-minute intervals after 15, 45, 75, 105 and 135 minutes after chewing. The results showed that in the first 15 minutes, there was a significant reduction in total bacteria and S mutans counts when compared to the placebo. The effect on lactobacilli was significant in the saliva samples collected after 45 minutes. (P<.001) The reduction in total bacteria count reached significance after 15, 45, 75, and 105 minutes. (P<.01).

Comments: This paper offers promise for pediatric dentists and orthodontists who continually struggle with maintaining optimal hygiene for patients with fixed appliances. Though the active ingredient of this natural substance requires purification and marketing prior to widespread availability, it presents an alternative product with little or no side effects. **AOA**

Address correspondence to Dr Nizami Duran, Silahli Kuvvetler Caddesi, Gullu Bahce Mahallesi, Buket Apt Kat 1, No 1, Antakya-Hatay, Turkey; e-mail: nizamduran@hotmail.com.

Aksoy A, Duran N, Toroglu S, Koksal F. Short-term effect of mastic gum on salivary concentrations of cariogenic bacteria in orthodontic patients. Angle Orthod 2007;77:124-8.

31 references