

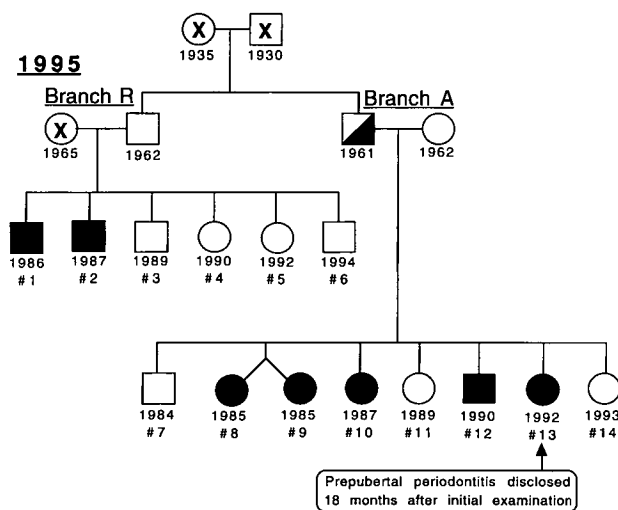


## Clinical and microbial considerations for the treatment of an extended kindred with seven cases of prepubertal periodontitis: a 2-year follow-up

Enrique Bimstein, CD Michael N. Sela, DMD, PhD Lior Shapira, DMD, PhD

**D**estructive forms of periodontal diseases may have an early onset in the primary dentition.<sup>1-4</sup> Two types of prepubertal periodontitis (PP) have been described:<sup>1</sup> a) generalized prepubertal periodontitis (GPP), which is characterized by severe gingival inflammation, gingival tissue proliferation, gingival recession, and a widespread and rapid destruction of the alveolar bone and b) localized prepubertal periodontitis (LPP), which may be clinically inconspicuous, but alveolar bone loss (ABL) at one or more primary teeth is disclosed by radiographic examination.

Periodontitis has been reported to affect siblings and their parents,<sup>5-8</sup> and the present manuscript describes two branches of an extended kindred (Fig 1), in which seven children (siblings and cousins) were affected with PP, and one parent had evidence of localized early onset periodontitis. The clinical and microbial considerations for the different treatment plans of the children, and the outcome of the treatments during a 2-year period are presented.



**Fig 1. Genealogical tree of the kindred: X = adult type periodontitis; half icon darkened = early onset periodontitis; complete icon darkened = prepubertal periodontitis.**

### Case reports

A 9-year-old boy (child 1 in the genealogical tree, Fig 1) was referred to the Pediatric Dentistry Clinic of the Faculty of Dentistry-Hadassah School of Dental Medicine in Jerusalem, due to extensive ABL. The initial examination revealed GPP, and the child's parents indicated that one brother and two cousins had a similar oral condition. Therefore, a comprehensive examination of the kindred was performed.

### Systemic condition of the kindred members

In addition to common childhood diseases, the systemic disease history of the kindred (Table 1) revealed that:

- Child 2 had thrombocytopenia 3 years before. Corticosteroid therapy for a week was unsuccessful, the disease was considered to be caused by a viral infection, and with no further treatment, the number of thrombocytes gradually returned to normal after 4 months
- Child 4 has a congenital heart valve defect
- Child 11 was healthy until age 9 months when convulsions took place, was treated with Phenobarbitone for several months, and since then has been under the follow-up care of a neurologist, who diagnosed her as being autistic, as well as an additional chromosome 15. Genetic analysis of the parents revealed that this was a nonheritable mutation
- The father in branch R has suffered from Crohn's disease, which is an intestinal disease characterized by granulomas with regional lymphatic involvement, since 1971.<sup>9</sup>

### Oral health history

As shown in Table 1, children 1, 2, 8, and 9 were previously identified as having abnormal tooth mobility in the primary dentition. Child 1 had early shedding of one tooth. Children 8 and 9 were previously treated by a periodontist who diagnosed LPP and performed subgingival curettage which

was not successful in preventing further ABL. In addition, in the case of child 9, the periodontist decided to extract both maxillary first primary molars and the mandibular right first primary molar due to extensive ABL.

### Initial clinical findings

As shown in Table 2, clinical examination of child 1

revealed the characteristic image of GPP.<sup>1</sup> The mandibular left first primary molar was absent due to early shedding several years before, and the mandibular left primary cuspid shed a few days after the present examination due to lack of bone support and atypical root resorption at its apical third. Children 8 and 9 also had atypical root resorption. Examination of the other kin-

dred members revealed five more children with prepubertal periodontitis, three adults with adult-type periodontitis, and one adult with early onset periodontitis, evidenced by a 9-mm loss of attachment in the maxillary first permanent molar (Figs 1, 2a, 2b, 3a, 4a). Mild-to-moderate dental caries was evident in eight children.

### Microbial examination

For examination of the presence of *Actinobacillus actinomycetemcomitans* and *Porphyromonas gingivalis* in the subgingival plaque, the supragingival plaque was removed and the teeth carefully dried, three sterile paper points were then inserted in the base of the sulcus or pocket for 10 sec, removed, and immediately inserted into a vial containing 0.3 mL of reduced transfer fluid (RTF).<sup>10</sup> The samples were vortexed for 60 sec, and then serially diluted in RTF (1:100, 1:200). Samples from each dilution were plated by means of an automatic spiral platter<sup>11</sup> on Trypticase Soy Bacitracin Vancomycin for *A. actinomycetemcomitans*<sup>12</sup> and Bacteroides

TABLE 1. SYSTEMIC AND ORAL HEALTH HISTORIES

Child Number*	Unusual Systemic Disease	Abnormal Tooth Mobility	Early Shedding	Extractions <sup>†</sup>	Previous Periodontal Treatment
1	-	+	+	-	-
2	+‡	+	-	-	-
3	-	-	-	-	-
4	+§	-	-	-	-
5	-	-	-	-	-
6	-	n/a	n/a	n/a	n/a
7	-	-	-	-	-
8	-	+	-	-	+
9	-	+	-	+	+
10	-	-	-	-	-
11	+ <sup>  </sup>	-	-	-	-
12	-	-	-	-	-
13	-	-	-	-	-
14	-	n/a	n/a	n/a	n/a

\* Child number in the genealogic tree.

† Extractions of primary teeth due to alveolar bone loss.

‡ Transient thrombocytopenia 3 years before.

§ Congenital heart valve defect.

|| Autistic, with an additional chromosome 15 (non-heritable mutation).

n/a Not applicable

TABLE 2. INITIAL FINDINGS

Child Number	Age in Years	Gender	Dental Caries	Unusual Gingivitis	Gingival Recession	Teeth with		
						Atypical Root Resorption	Alveolar Bone Loss	Periodontal Diagnosis
1	9	male	+	+	+	73	53-55, 63-65 73-75, 83-85	GPP
2	8	male	-	-	-	-	54, 64, 74	LPP
3	6	male	+	-	-	-	-	normal
4	5	female	+	-	-	-	-	normal
5	3	female	+	-	-	-	-	normal
7	11	male	-	-	-	-	-	normal
8	10	female	+	+	-	74, 84	54, 74, 84	LPP
9	10	female	+	+	-	74, 85	74, 75, 85	LPP
10	8	female	+	-	-	-	84	LPP
11	6	female	-	-	-	n/e	n/e	normal
12	5	male	-	-	-	-	53, 54, 64, 65, 85	LPP
13	3	female	+	-	-	-	-	normal

GPP = generalized prepubertal periodontitis, LPP = localized prepubertal periodontitis, n/e = not examined

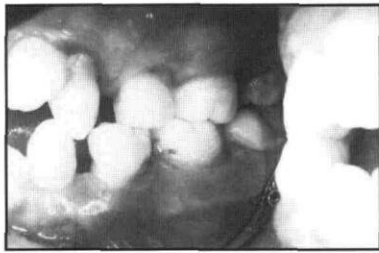


Fig 2a. Initial right intraoral photograph (mirror view) of child #1. Gingival inflammation and recession are evident in the primary teeth.

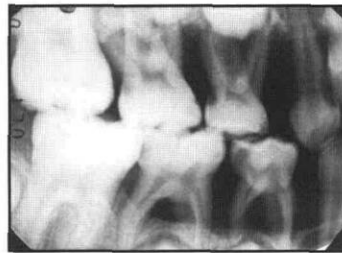


Fig 2b. Initial right bite-wing radiograph of child # 1. Extensive alveolar bone loss is present in all the primary teeth.

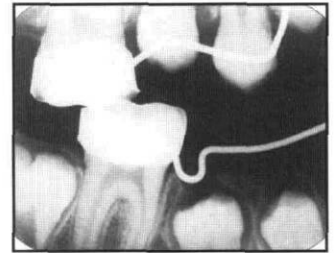


Fig 2c. One year follow-up right bite-wing radiograph of child # 1. No alveolar bone loss is evident.

TABLE 3. INITIAL MICROBIAL FINDINGS

Child Number	Bone Situation*	A.a.†	P.g.‡
1	GPP	+	+
2	LPP	-	+
3	normal	-	+
4	normal	-	-
5	normal	-	+
7	normal	+	+
8	LPP	+	+
9	LPP	+	+
10	LPP	+	+
12	LPP	+	-
13	normal	+	+

\* LPP= localized prepubertal periodontitis, GPP= generalized prepubertal periodontitis.

† *Actinobacillus actinomycetemcomitans*.

‡ *Porphyromonas gingivalis*.

catalase-positive bacteria with the specific typical "star shaped" colony were counted as *A. actinomycetemcomitans*.) Plates from each sample were then incubated for the assessment of the anaerobic organisms in a Coy anaerobic chamber (Coy Laboratory Products, Ann Arbor, MI) for 7 days in an atmosphere of N<sub>2</sub>, H<sub>2</sub>, and CO<sub>2</sub> at 37° C.

### Initial microbial findings (Table 3)

Microbial cultures were performed with the subgingival plaque from six children with PP and five children without ABL. *A. actinomycetemcomitans* was cultured from the subgingival plaque of five children with ABL and two children without ABL. *P. gingivalis* was cultured from the subgingival plaque of five children with ABL and four children without ABL. *A. actinomycetemcomitans* and *P. gingivalis* together were found in two children with a healthy alveolar bone and in four with ABL. In children with ABL, neither *A. actinomycetemcomitans* nor *P. gingivalis*, were found in every site with ABL. Only child 4, a 5-year-old girl without ABL, was free of *A. actinomycetemcomitans* and *P. gingivalis*.

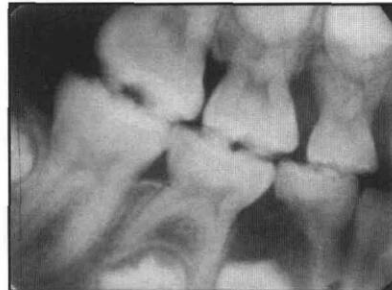

Fig 3a. Initial right bite-wing radiograph of child #10. Alveolar bone resorption affecting both first primary molars, and atypical root resorption of the distal root of the mandibular first primary molar are evident.

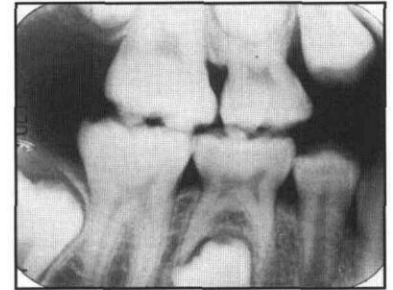


Fig 3b. One year follow-up bite-wing radiograph of child # 10. No alveolar bone loss is evident.

Gingivalis Agar for *P. gingivalis*.<sup>13</sup> (Only

### Initial treatment plans (Table 4)

In addition to oral prevention measures and the treatment of caries, three options were considered for the treatment of the children with PP: 1) antibiotic therapy, which included 375 mg amoxicillin and 250 mg metronidazole, three times a day for 7 days;<sup>14</sup> 2) subgingival irrigation with chlorhexidine in the periodontal pockets; and 3) extraction of the periodontally involved teeth and space maintainers.

In the case of child 1, the immediate extraction of all the primary teeth with ABL was considered crucial due to the proximity of the ABL to the developing permanent teeth (Fig 2b) and the possibility of the spreading of inflammatory lesions to the erupted permanent teeth. Therefore, all the extractions were made concurrently under general anesthesia. Due to the extent of the ABL, the extractions were followed by extensive collapse of the gingiva and numerous sutures were required. Antibiotic therapy, as previously described,<sup>14</sup> was initiated immediately after the extractions. Subsequently, composite sealant restorations, prevention measures, and space maintenance were performed under regular clinic conditions. For child 2, antibiotic therapy was recommended, preventive measures were instructed, and a series of monthly subgingival irrigations with chlorhexidine was established.

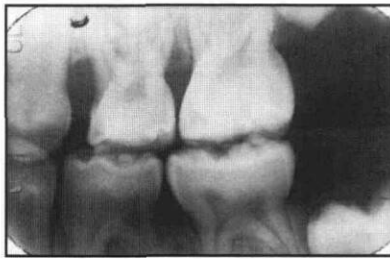


Fig 4a. Initial left bite-wing radiograph of child # 12. Alveolar bone loss is evident in the maxillary first primary molar.

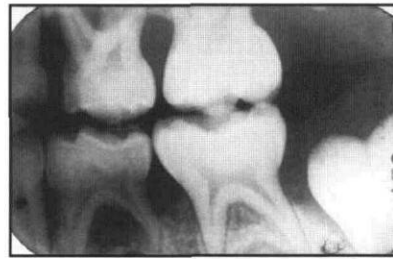


Fig 4b. Six month follow-up left bite-wing radiograph of child # 12. The alveolar bone loss spread apically and to other primary teeth.

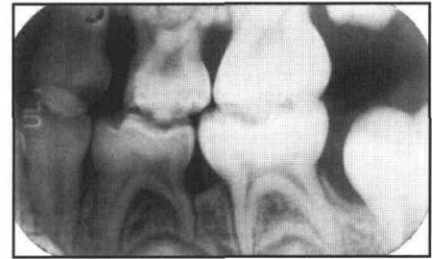


Fig 4c. One year follow-up left bite-wing radiograph of child # 12. Healing of the alveolar bone is evidenced by a well defined alveolar bone crest and a reduction in the size of the alveolar bone resorption areas.

TABLE 4. INITIAL TREATMENT FOR THE CHILDREN WITH PREPUBERTAL PERIODONTITIS

Child Number	Restorative	Sealants	Extractions	Antibiotic Therapy	Subgingival Irrigation	Space Maintainers
1	+	+	+	+	-	+
2	-	-	-	+	+	-
8	+	+	+	+	-	np
9	+	+	+	+	-	+
10	+	-	-	np	-	-
12	-	-	-	np	-	-

np= Recommended but not provided by the treating dentist.

Due to financial considerations, the children of branch A were treated at another clinic. We recommended extractions of the periodontally affected primary teeth, antibiotic therapy, restorative and preventive measures, space maintainers for children 8 and 9; antibiotic therapy and preventive measures for children 10 and 12; preventive measures for child 7; and preventive measures and treatment of caries for child 13. The adult members were referred to a periodontist for treatment. With the exception of child 11, the children of both branches were referred to a pediatrician for systemic evaluation, which disclosed no relevant information.

### Microbial findings after antibiotic therapy

Cultures of the subgingival plaque from six children with PP after antibiotic therapy indicated that all children still had *A. actinomycetemcomitans* and/or *P. gingivalis* in at least one site. Children 1, 2 and 10 had both; children 8 and 12 had *P. gingivalis*; and child 9 had *A. actinomycetemcomitans*. In the case of child 1, the subgingival plaque was obtained from the mesial surfaces of the first permanent molars. It should be noted that children 10 and 12 received the antibiotic therapy only after the 6-month recall.

### Six-month recall findings (Table 5)

The children who had no PP remained without ABL. Child 1 adapted well to function with a reduced number of teeth and to the space maintainers. Mild gingival inflammation was apparent around the first permanent

molars on which the space maintainers bands were cemented. The alveolar bone appeared to be healthy. Prevention measures were reinforced. Child 2 had a significant reduction in gingival inflammation, pocket depths and tooth mobility, and no radiographic evidence of additional ABL. The chlorhexidine subgingival irrigation was suspended.

Children 8 and 9 had the primary teeth with ABL extracted, antibiotic therapy was provided, and carious lesions were treated. Child 9 was provided with space maintainers. Mild gingivitis and a healthy radiographic image of the alveolar bone were evident. The children were referred for reinforcement of preventive measures and additional treatment of caries by the treating dentist. Child 10 had the carious lesions treated. The antibiotic therapy which was recommended had not been provided but there was no evidence of additional ABL. Preventive measures were reinforced and antibiotic therapy was prescribed again. Child 12 did not receive the recommended antibiotic therapy and the LPP deteriorated to GPP (Figs 4b, 5a). Preventive measures were reinforced and antibiotic therapy was initiated. Seven weeks later, a significant reduction of the gingival inflammation was evident (Fig 5b) and the primary molars appeared to be less mobile with no further ABL. On the other hand, both maxillary primary central incisors and the maxillary left primary lateral incisor had a significant increase in mobility, rapidly progressing ABL, and atypical root resorption was evident in both central incisors (Fig 5c). The maxillary centrals and lateral left incisors were extracted under local anesthesia.

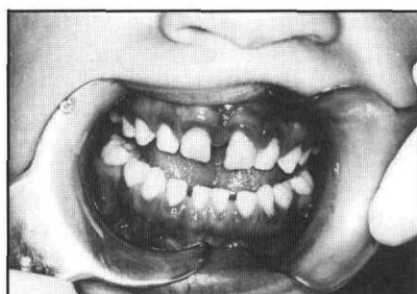### Twelve-, 18- and 24-month recall findings (Table 5)

One year after treatment, no ABL was evident in all the children who previously had no PP, and in children

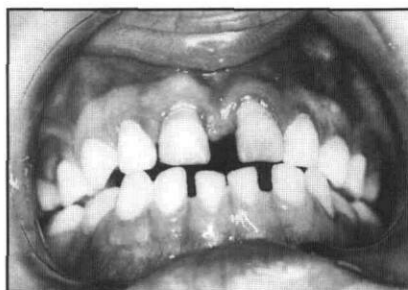**TABLE 5. INITIAL (0) AND FOLLOW UP FINDINGS (6, 12, 18 AND 24 MONTHS) OF THE CHILDREN WITH PREPUBERTAL PERIODONTITIS**

Child number	Gingival inflammation					Gingival recession					Alveolar bone loss				
	0	6	12	18	24	0	6	12	18	24	0	6	12	18	24
1	+++	+	+	+	+	++	-	-	-	-	+++	-	-	-	-
2	++	+	+	+	-	-	-	-	-	-	++	++	++	++	++
8	++	+	+	+	-	-	-	-	-	-	++	-	-	-	-
9	++	+	+	+	+	-	-	-	-	-	++	-	-	-	-
10	+	+	+	+	+	-	-	-	-	-	+	+	+	+	+
12	+	+++	+	-	+	-	++	-	-	-	+	+++	++	++	++
13	-	-	-	++	+	-	-	-	+	-	-	-	-	++	-

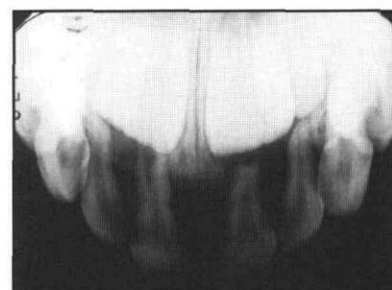- none +mild ++ moderate +++ severe



**Fig 5a.** Six-month follow-up intraoral picture of child # 12. Severe gingival inflammation and gingival recession are evident in several teeth.



**Fig 5b.** Intraoral picture of child # 12, 7 weeks after figure 5a. Antibiotic therapy was prescribed and a significant reduction in gingival inflammation is evident.



**Fig 5c.** Anterior maxillary radiograph 7 weeks after antibiotic therapy and meticulous oral hygiene. Despite of the reduction in the severity of gingival inflammation shown in 5b, extensive and rapid alveolar bone loss and atypical root resorption are evident.

1, 8, 9 (Figs 2c, 3b). No additional ABL was evident in children 2, 10, and 12. Moreover, in child 12, healing of the alveolar bone was evidenced by a reduction in the size of the resorbed bone areas, and a well-defined lamina dura (Fig 4c).

At the 18-month recall examination, the situation remained stable with the exception of child 13, who developed LPP as evidenced by mild gingival inflammation and tooth mobility on the mandibular right primary central incisor, moderate gingival inflammation and recession, and moderate-to-severe mobility and ABL on the mandibular left primary central incisor, which was extracted with a recommendation of antibiotic therapy.

At the 24-month recall, the clinical examination revealed mild gingivitis in children 1 (around the space maintainer bands located at the first permanent molars), 9, 10, 12, and 13, and no gingival inflammation with normal probing depths in children 2 and 8. The radiographic examination revealed normal alveolar bone in children 1, 8, 9, and 13 (in which the mandibular permanent central incisors were erupting), and no further alveolar bone loss in the primary teeth of chil-

dren 2, 10, and 12. Furthermore, an additional improvement in the alveolar bone was evident in child 12.

## Discussion

The general outline of the treatment plans of the present cases was aimed at stopping or reversing the ABL, preventing damage to the permanent tooth germs, preventing spread of the inflammatory lesions to erupted permanent teeth, the restoration of carious teeth, and the prevention of further caries, periodontal diseases, and space loss. Therefore, individual treatment plans were determined based on the extent of ABL, likelihood of involvement of erupted permanent teeth with ABL, dental age, occlusion, and behavior-management considerations.

In the present family, *A. actinomycetemcomitans* and *P. gingivalis* were found in several members of both branches of the kindred, regardless of the presence or absence of ABL. This finding is in agreement with previous reports, which indicate that microorganisms related to ABL may be transmitted between members of the same family,<sup>6-8,15</sup> and that host factors, such as genetic predisposition, may have a more significant ef-

fect on the development of periodontal diseases than the presence of periopathogenic bacteria.<sup>6, 16, 17</sup> These findings led us to the decision not to prescribe antibiotic therapy to the children with no ABL who had *A. actinomycetemcomitans* and/or *P. gingivalis*. The finding that one healthy child (13) who had both microorganisms developed PP during the follow-up period may suggest that antibiotic therapy could have prevented the development of PP. However, the fact that the disease developed 18 months after the initial examination in only one of the four healthy children with *A. actinomycetemcomitans* and/or *P. gingivalis* (Table 3) indicates that our decision was appropriate, and that a long-range follow-up is required in such cases. These findings also suggest a poor predictive ability of microbial analysis to project future ABL. Furthermore, one must consider that reinfection after antibiotic therapy is possible.

The antibiotic of choice for the eradication of *A. actinomycetemcomitans* is tetracycline,<sup>18</sup> which stains the developing permanent dentition.<sup>19</sup> Despite the fact that tetracyclines have been previously utilized in the treatment of PP,<sup>5, 20, 21</sup> we adopted the successful regimen recently reported by Paviciv<sup>14</sup> for the treatment of *A. actinomycetemcomitans*-associated periodontitis in adults, which does not include tetracyclines. This regimen is within the limits of the recommendations of amoxicillin and metronidazole for some systemic diseases in children.<sup>22, 23</sup> It is possible however, that lower dosages, based on the general recommendations for children, of metronidazole (15 mg/kg/24 hr/t.i.d.)<sup>22</sup> and amoxicillin (20–40 mg/kg/24 hr/t.i.d.)<sup>23</sup> for a 7-day course may also be effective.

Two children who had LPP did not receive the initially recommended antibiotic therapy, and while one (child 10) had no further ABL, the other (child 12) developed GPP. The difference in the disease path for the children may be related to the fact that the initial ABL was more severe in child 12 than in child 10 (Table 1). Moreover, in the case of child 12, the antibiotic therapy and oral hygiene achieved alveolar bone healing only at the molar areas (Figs 4b, 4c, 5c). The lack of success in the anterior maxillary teeth was probably due to their more severe lesions. These findings emphasize that the early diagnosis and treatment of periodontal diseases in children are critical for the success of treatment.

In the present cases, a significant reduction in gingival inflammation and an improvement of the radiographic appearance of the alveolar bone were evident (Figs 4b, 4c, 5a, 5b) even though *A. actinomycetemcomitans* and *P. gingivalis* were still components of the subgingival plaque after antibiotic therapy. This apparent discrepancy may be due to a reduction in the total bacterial load or eradication of other periodontal pathogens.

Previous manuscripts on PP report extraction of the primary teeth affected with ABL because of their extensive mobility, or with the purpose of preventing future infections.<sup>5, 20, 24–29</sup> Mandell, Siegal, and Umland<sup>5</sup>

and Ngan, Tsai, and Sweeney<sup>20</sup> report eradication of *A. actinomycetemcomitans* after extractions and antibiotic therapy, and Ram and Bimstein<sup>29</sup> report eradication of *A. actinomycetemcomitans* and *P. gingivalis* after extraction of the primary teeth affected with ABL. It should be emphasized that in children with severe systemic diseases, such as leukocyte adhesion deficiency, not extracting the affected teeth may lead to infections which might endanger the child's life.<sup>30</sup>

In the present cases, *A. actinomycetemcomitans* and *P. gingivalis* were still present in the subgingival plaque of children who had extracted teeth and received antibiotic therapy. Furthermore, in the case of child 1, this treatment failed to prevent infection of the subgingival plaque of the first permanent molars. The reason for these findings may be the transmission of microorganisms within members of the same family,<sup>7, 8, 15</sup> the fact that we did not include subgingival curettage in the treatment,<sup>31</sup> or bacterial resistance to antibiotic therapy.<sup>32</sup> The clinical significance of bacterial resistance to antibiotics should be considered when treating infectious diseases, and antibiotic-sensitivity testing prior to initiating antibiotic therapy should also be considered.

In the case of children 8 and 9, subgingival curettage was not successful in preventing additional ABL before they were brought to our clinic. This outcome may be related to the fact that antibiotic therapy, which is an additional requirement to subgingival curettage in the treatment of *A. actinomycetemcomitans*-related periodontitis, was not prescribed.<sup>31, 33</sup> On the other hand, we achieved healing of the alveolar bone in children 2, 10, and 12 (Figs 4b, 4c) with antibiotic therapy, oral hygiene, and no subgingival curettage. It is possible, however, that inclusion of curettage in their treatment could have resulted in a better clinical outcome and the eradication of *A. actinomycetemcomitans*.

Because the recommended antibiotic therapy<sup>14</sup> is a one-course prescription combined with subgingival curettage,<sup>31</sup> treating all the periodontally involved teeth in the same appointment is recommended. Therefore, sedation may be indicated<sup>30</sup> in children with several affected quadrants, as the extensive treatment may elicit behavior-management problems.

Chlorhexidine subgingival irrigation has a positive clinical effect when utilized as a daily self-therapy by adult patients with periodontitis.<sup>34</sup> One of our present cases was treated with chlorhexidine subgingival irrigation on a monthly basis for 6 months, in addition to antibiotic therapy and oral hygiene instructions. These measures led to healing of the periodontal tissues, although, there is no way to establish if this was the result of the antibiotic therapy, the chlorhexidine irrigation, careful oral hygiene, or a combination of some or all these measures. It should be noted that cessation of the chlorhexidine irrigation after 6 months did not lead to any regression in the tissue situation, suggesting that the antibiotic therapy and meticulous oral hygiene had had the most significant effect on controlling the disease.

Atypical root resorption was observed in teeth with severe ABL in four of the present cases (Figs 2b, 3a, 5c). This finding is in agreement with previous manuscripts that report root resorption related to hypophosphatasia and in children with PP and no systemic disease.<sup>5,26,27,35</sup>

PP has been related to several systemic diseases,<sup>1,2,27,30</sup> and has also been reported in children in whom evaluation revealed no systemic disease related to the oral disease.<sup>21,24-26,35</sup> In our study, child 1 had a high blood level of alkaline phosphatase. A similar finding was previously reported in a case of PP and is considered normal during periods of active bone growth in children.<sup>20</sup> In any case, the possibility of underlying systemic diseases should still be taken into consideration.

This family is probably the largest reported kindred affected with prepubertal periodontitis, and additional case reports and studies are required for better understanding of the etiology and treatment of this disease.

## Conclusions

1. Prepubertal periodontitis may have a high prevalence among children of the same kindred (siblings and cousins).
2. A genetic predisposition for PP is possible.
3. Antibiotic therapy with amoxicillin and metronidazole, or the same antibiotic therapy combined with extraction of the primary teeth affected with ABL may lead, in otherwise healthy children, to clinical and radiographic evidence of healing of PP. However eradication of *A. actinomycetemcomitans* and/or *P. gingivalis* may not be achieved.
4. Long-range follow-up of the family members of children with PP is recommended in order to disclose and treat PP at its early stages.
5. The early diagnosis and treatment of PP is crucial for the success of its treatment, and individual plans should be outlined according to the distinct characteristics of each child.

Dr. Bimstein is professor, Department of Pediatric Dentistry; Dr. Sela is professor, Department of Oral Biology; and Dr. Shapira is lecturer, Department of Periodontology, all at Hadassah School of Dental Medicine, The Hebrew University in Jerusalem, Israel.

1. Page RC, Bowen T, Altman L, Vandesteen E, Ochs H, Mackenzie P, Osterberg S, Engel D, Williams B: Prepubertal periodontitis. I. Definition of a clinical disease entity. *J Periodontol* 54:257-71, 1983.
2. Watanabe K: Prepubertal periodontitis: a review of diagnostic criteria, pathogenesis, and differential diagnosis. *J Periodont Res* 25:31-48, 1990.
3. Van der Velden U: The onset age of periodontal destruction. *J Clin Periodontol* 18:380-83, 1991.
4. Committee on Research, Science and Therapy of The American Academy of Periodontology: Periodontal Diseases of Children and Adolescents. *J Periodontol* 67:57-62, 1996.
5. Mandell RL, Siegal MD, Umland E: Localized juvenile periodontitis of the primary dentition. *ASDC J Dent Child* 53:193-96, 1986.
6. Nishimura F, Nagai A, Kurimoto K, Isoshima O, Takashiba S, Kobayashi M, Akutsu I, Kurihara H, Nomura Y, Murayama Y, Otha H, Kato K: A family study of a mother

and daughter with increased susceptibility to early onset periodontitis: microbiological, immunological, host defensive, and genetic analyses. *J Periodontol* 61:755-62, 1990.

7. Gunsolley JC, Ranney RR, Zambon JJ, Burmeister JA, Schenkein HA: *Actinobacillus actinomycetemcomitans* in families afflicted with periodontitis. *J Periodontol* 61:643-48, 1990.
8. Petit MD, Van Steenberg TJ, Scholte LM, Van der Velden U, De Graff J: Epidemiology and transmission of *Porphyromonas gingivalis* and *Actinobacillus actinomycetemcomitans* among children and their family members. A report of 4 surveys. *J Clin Periodontol* 20:641-50, 1993.
9. Hamilton JR: The digestive system. In *Textbook of Pediatrics*. Berham RE, Vaughan VC, eds. Philadelphia: WB Saunders Co, 1983, pp 923-24.
10. Syed SA, Loesche WJ: Survival of human dental plaque flora in various transport media. *Appl Microbiol* 24:638-44, 1972.
11. Jarvis B, Lach VH, Wood JKM: Evaluation of the spiral plate marker for the enumeration of microorganisms in foods. *J Appl Bacteriol* 43:149-57, 1977.
12. Slots J: Selective medium for isolation of *Actinobacillus actinomycetemcomitans*. *J Clin Microbiol* 15:606-609, 1982.
13. Hunt DE, Jones JV, Dowell JR: Selective medium for the isolation of *Bacteroides gingivalis*. *J Clin Microbiol* 23:441-45, 1986.
14. Pavicic MJ, van Winkelhoff AJ, Douqué NH, Steures RW, de Graff J: Microbial and clinical effects of metronidazole and amoxicillin in *Actinobacillus actinomycetemcomitans*-associated periodontitis. A 2-year evaluation. *J Clin Periodontol* 21:107-12, 1994.
15. Preus HR, Zambon JJ, Dunford RG, Genco RJ: The distribution and transmission of *Actinobacillus actinomycetemcomitans* in families with established adult periodontitis. *J Periodontol* 65:2-7, 1994.
16. Shapira L, Smidt A, Van Dyke T, Barak B, Soskolne AW, Brautbar C, Sela MN, Bimstein E: Sequential manifestation of different forms of Early-Onset Periodontitis. A Case Report. *J Periodontol* 65:631-35, 1994.
17. Nisengard R, Newman MG and Sanz M: The host response: basic concepts. In *Clinical Periodontology*, 7th Ed. Carranza FA, ed. Philadelphia: W.B. Saunders Company, 1990, pp 331-42.
18. Seymour RA, Heasman PA: Tetracyclines in the management of periodontal diseases. A review. *J Clin Periodontol* 22:22-35, 1995.
19. Pindborg JJ: Discolorations. In *Pathology of the Dental Hard Tissues*. Philadelphia: Saunders, 1970, p 211.
20. Ngan PH, Tsai C, Sweeney E: Advanced periodontitis in the primary dentition; case report. *Pediatr Dent* 4:255-58, 1985.
21. Mishkin DJ, Grant NC, Bergeron RA, Young WL: Prepubertal periodontitis: a recently defined clinical entity. *Pediatr Dent* 8:235-38, 1986.
22. Yosselson-Superstine S: Metronidazole. In *Handbook of Drug Information and Consultation*, 2nd. ed. Jerusalem: The Magnes Press-The Hebrew University, 1987, pp 402-404.
23. Yosselson-Superstine S: Amoxicillin trihydrate. In *Handbook of Drug Information and Consultation*, 2nd. ed. Jerusalem: The Magnes Press-The Hebrew University, 1987, pp 35-37.
24. Moffitt JH: Juvenile periodontitis: report of a case. *J Dent Child* 41:452-55, 1974.
25. Cogen RB, Al-Joburi W, Caufield PW, Stanley HP, Donaldson KD: Periodontal disease in healthy children: two clinical reports. *Pediatr Dent* 6:41-45, 1984.
26. Myers DR, O'Dell NL, Clark JW, Cross RL: Localized prepubertal periodontitis: literature review and report of a case. *ASDC J Dent Child* 56:107-11, 1989.
27. Plagmann H-C, Kocher T, Kuhrau N, Caliebe A: Periodontal manifestation of hypophosphatasia. A family case report. *J Clin Periodontol* 21:710-16, 1994.

28. Yoshida-Minami I, Kishimoto K, Suzuki A, Fujiwara T, Shintani S, Morisaki I, Sobue S, Miyasato M, Nagai A, Kurihara H, Murayama Y, Ooshima T: Clinical, microbiological and host defense parameters associated with a case of localized prepubertal periodontitis. *J Clin Periodontol* 22:56-62, 1995.
29. Ram D, Bimstein E: Subgingival bacteria in a case of prepubertal periodontitis, before and one year after extractions of the affected primary teeth. *J Clin Pediatr Dent* 19:45-47, 1994.
30. Roberts MW, Atkinson JC: Oral manifestations associated with leukocyte adhesion deficiency: a five year case history. *Pediatr Dent* 12:107-11, 1990.
31. Sanz M, Newman MG, Nisengard R: Periodontal Microbiology. In Glickman's Clinical Periodontology, 7th ed. Carranza FA, Ed. Philadelphia: W.B. Saunders Co, 1990, p 365.
32. Greenstein G: Clinical significance of bacterial resistance to tetracyclines in the treatment of periodontal diseases. *J Periodontol* 66:925-32, 1995.
33. Christersson LA, Slots J, Rosling BG, Genco RJ: Microbial and clinical effects of surgical treatment of localized juvenile periodontitis. *J Clin Periodontol* 12:465-76, 1985.
34. Soh LL, Newman HN and Strahan JD: Effects of subgingival chlorhexidine irrigation on periodontal inflammation. *J Clin Periodontol* 9:66-74, 1982.
35. Goepferd SJ: Advanced alveolar bone loss in the primary dentition. A case report. *J Periodontol* 52:753-57, 1981.

## Future Annual Sessions of the American Academy of Pediatric Dentistry

**51st Annual Session**  
May 21-26, 1998

**52nd Annual Session**  
May 27-June 1, 1999

**San Diego**  
San Diego Marriott Hotel & Marina

**Toronto**  
Sheraton Centre of Toronto Hotel & Towers

**53rd Annual Session**  
May 25-May 30, 2000

**54th Annual Session**  
May 24-29, 2001

**Nashville**  
Opryland Hotel

**Atlanta**  
Hyatt Regency