



# Seven-year Follow-up of 10 Children With Periodontitis

Enrique Bimstein, CD

*Dr. Bimstein is professor in pediatric dentistry, Hadassah School of Dental Medicine, Hebrew University, Jerusalem, Israel and is on sabbatical, College of Dentistry, University of Florida, Gainesville, Fla.*

*Correspond with Dr. Bimstein at ebimstein@dental.ufl.edu*

## Abstract

The present manuscript reports a 7-year follow-up of a kindred in which 10 children (siblings and cousins) had moderate to severe periodontal diseases in primary (9 children) and permanent teeth (1 child). No systemic condition was related to the periodontal diseases. The number of affected teeth per child varied from 1 to 12. Treatments involved local therapy and systemic antibiotics. Treatment of periodontitis in primary teeth led to alveolar bone regeneration and periodontally healthy permanent teeth. Recurrence was suspected only in 1 case. The different aspects related to prevention, diagnosis, and treatments of families with periodontal diseases are discussed. From this manuscript, it is concluded that (1) susceptible families develop a high prevalence of periodontitis; (2) these families should be carefully monitored to provide early treatment to new cases; and (3) treatment of children with periodontitis in the primary dentition may be successful, with no periodontitis developing in the permanent dentition in adolescence. (*Pediatr Dent.* 2003;25:389-396)

**KEYWORDS:** FAMILIAR PERIODONTITIS, CHILDREN, GENETIC PREDISPOSITION

*Received August 16, 2002 Revision Accepted December 11, 2002*

An increasing number of professional publications, including a recent issue of the journal *Periodontology 2000* and a new book,<sup>1,2</sup> emphasize the relevance of gingival and periodontal diseases in children and clearly indicate that children are not immune to these destructive diseases. Moreover, it has been indicated that:

1. Periodontopathic bacteria are transmissible among family members, leading to a high prevalence of periodontitis in susceptible families.<sup>3-8</sup>
2. There is a genetic predisposition for periodontal diseases.<sup>9-13</sup>
3. Children with periodontitis in the primary teeth have a significantly increased susceptibility for periodontitis at older ages.<sup>14-17</sup>

While there is a significant amount of information on periodontal diseases in adulthood, there is still relatively little information on the prevention and treatment of periodontal diseases in children. The present manuscript presents the outcome of a 7-year follow-up of an extended kindred composed by 2 branches (branch R and branch A, Figure 1), in which 10 children (siblings and cousins) were found to have various degrees of periodontitis: 9 children with prepubertal<sup>18</sup> or childhood periodontitis<sup>17</sup> in their primary teeth; and 1 child with aggressive periodontitis<sup>17</sup>

in her permanent teeth. The kindred included additional children who were still too young (younger than 3 years old) to be examined for periodontitis. Examination of the parents and grandparents revealed that the father in branch A had aggressive periodontitis and the mother of branch R and both paternal grandparents had chronic periodontitis (Figure 1).<sup>7</sup> Since 1971, the father in branch R had suffered from Crohn's disease,<sup>7</sup> an intestinal disorder characterized by granulomas with regional lymphatic involvement<sup>19</sup> that has been related to severe periodontitis.<sup>20</sup>

The initial findings, treatment, and a 2-year follow-up of the kindred were discussed in a previous report.<sup>7</sup> Therefore, this manuscript primarily concentrates on the additional 5-year follow-up, during which the success of the initial treatment of 7 cases with periodontitis and the disclosure of 3 additional cases are described. It should be noted that:

1. All children either were received in the author's clinic or referred for comprehensive oral treatment.
2. All children who were diagnosed with periodontitis were referred for systemic evaluation by a pediatrician who failed to disclose any systemic condition related to the periodontal diseases.

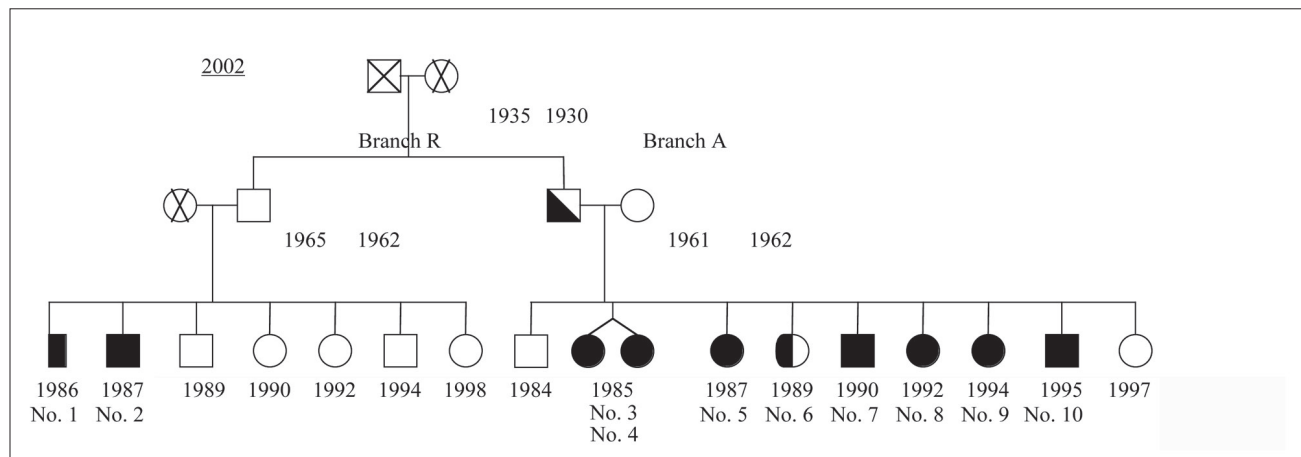


Figure 1. Genealogical tree of the kindred: x=chronic periodontitis; half icon darkened=aggressive periodontitis; complete icon darkened=childhood periodontitis. Numbers under the icons represent the year of birth.

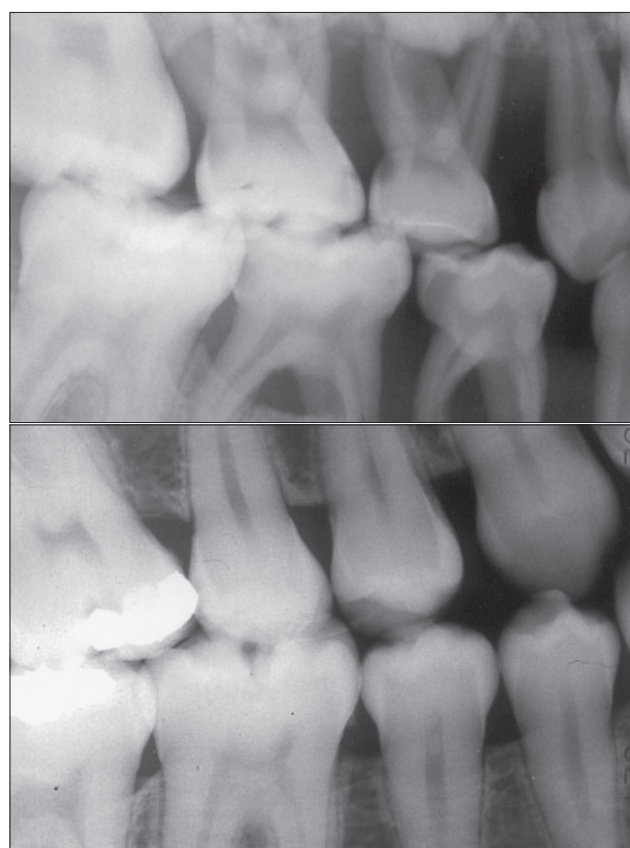


Figure 2. Bite-wing radiographs of case No. 1 at beginning and end of the follow-up (1995 and 2002, respectively). Extensive alveolar bone loss is evident in the primary teeth in the initial radiograph; a normal periodontium is evident in the permanent dentition.

### Three- to 7-year follow-up findings

Figure 1 presents the genealogical tree of the kindred after a 7-year follow-up, during which periodontitis was disclosed in 10 children, 6 of whom were females (1:1.5 male-female ratio).

The last 5-year follow-up, revealed that:

1. Case No. 1, 3, 4, 5, and 7 had occasional gingival inflammation proportional to the child's age and amount of dental plaque accumulation,<sup>21-23</sup> and de-

veloped a permanent dentition with no evidence of periodontal disease (Figures 2 and 3).

2. Case No. 3, 4, and 7 showed alveolar bone regeneration in the affected primary teeth (Figures 3b and 3d) after local and systemic antibiotic therapies.<sup>7</sup>
3. Case No. 5, who had alveolar bone loss in tooth S only (Figure 4, Table 1), had no significant disease change until normal exfoliation, despite the fact that the child did not receive local periodontal treatment or the prescribed antibiotic therapy.<sup>7</sup>
4. Case No. 2 and 8 had occasional gingival inflammation proportional to the child's age and amount of dental plaque accumulation,<sup>21-23</sup> showed alveolar bone regeneration after local and systemic antibiotic therapies, and developed a mixed dentition with no evidence of periodontal disease in the permanent teeth.
5. Case No. 6 was thoroughly examined and treated only at age 12 years (in 2002) under general anesthesia due to severe behavior management problems, including autism, related to her systemic condition.<sup>7</sup> This exam revealed aggressive periodontitis affecting the permanent mandibular anterior teeth (Figure 5, Table 1). The child was treated with curettage, root planning, intrapocket chlorhexidine rinses, and antibiotic therapy with metronidazole and amoxicillin.<sup>7</sup>
6. Case No. 9 was first brought to the author's clinic at age 2 (in 1996) due to trauma to teeth E and F; tooth E was extracted due to an abscess related to the traumatic injury which involved extensive bone resorption. At age 3 years, excessive gingival inflammation not proportional to the amount of plaque and the child's age<sup>21-23</sup> became evident in the buccal area of tooth L; adequate oral hygiene resulted in elimination of the inflammation. In 1999, at 5 years of age, initial signs of localized periodontitis that included bleeding on probing in teeth B and I, a periodontal pocket of 7 mm, and radiographic evidence of periodontitis in teeth B and I were evident (Table 1). Systemic antibiotic therapy with metronidazole and

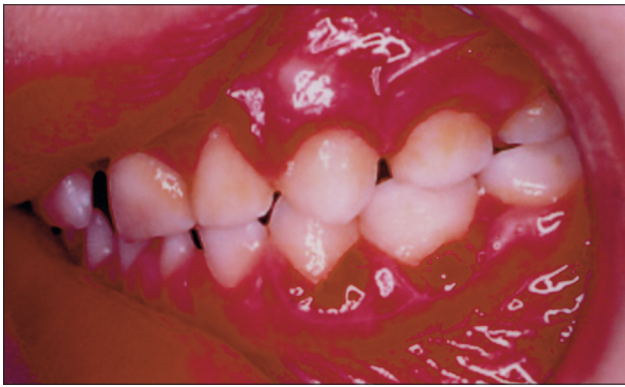

Figure 3a. Clinical photograph of case No. 7 (1995), in which severe gingival inflammation in the primary teeth is evident.

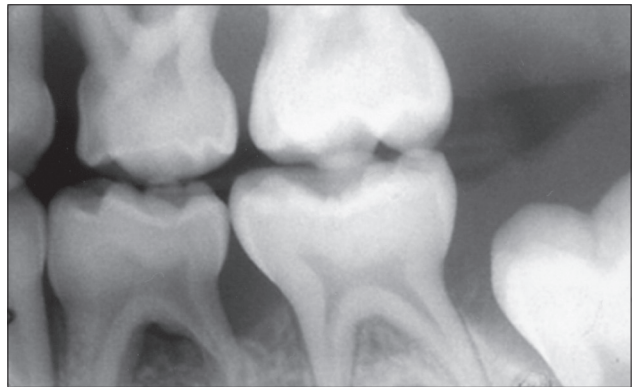


Figure 3b. Bite-wing radiograph of the area shown in Figure 3a. Generalized periodontitis affecting the primary teeth is clear.

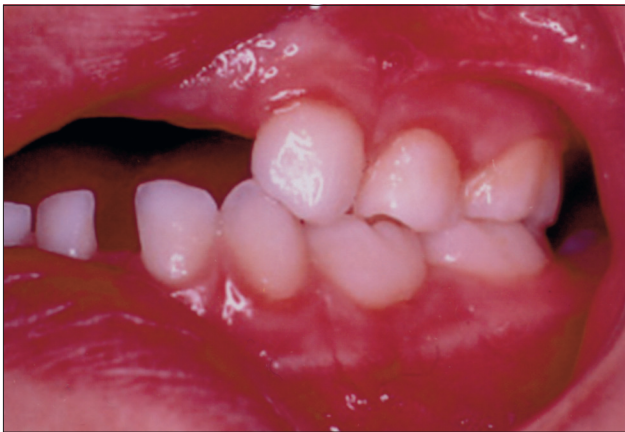

Figure 3c. Clinical photograph of case No. 7, 2 years after treatment of generalized periodontitis. No gingival inflammation is evident.

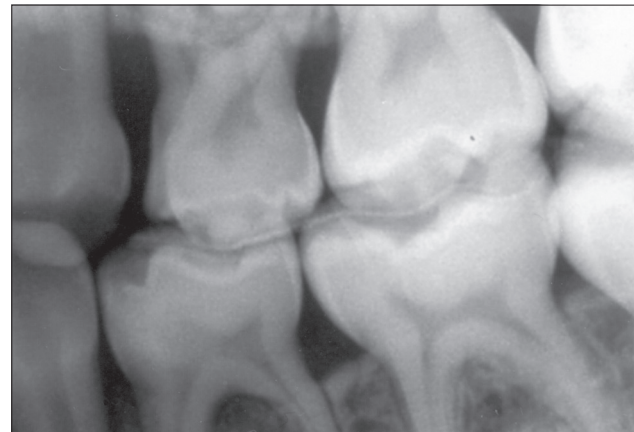


Figure 3d. Bite-wing radiograph of the area shown in Figure 3c. Bone regeneration in the primary teeth is evident.

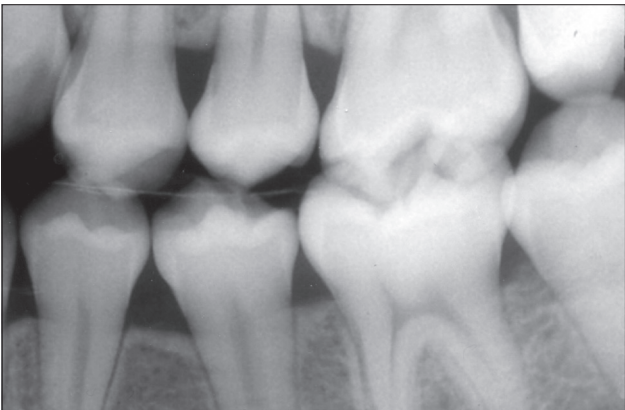


Figure 3e. Final bite-wing radiograph of case No. 7 (2002). No evidence of periodontal disease in the permanent dentition is evident.

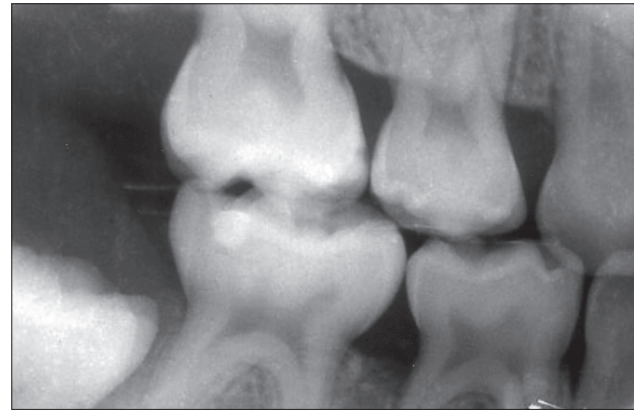


Figure 4. Initial bite-wing radiograph of case No. 5. Alveolar bone loss is apparent only affecting the distal surface of tooth S.

amoxicillin were prescribed.<sup>7</sup> In 2002, a mixed dentition with alveolar bone regeneration in tooth B and no radiographic evidence of periodontitis in tooth I or the permanent teeth were evident.

7. Case No. 10 was first brought to the author's clinic at age 4 years (in 2000). The clinical and radiographic examination revealed: (1) moderate gingivitis in teeth H, I, and J that was not proportional to the amount of plaque and the child's age;<sup>21-23</sup> (2) probing depths of 2.5 to 3 mm in the same teeth that were consid-

ered to be the result from gingival inflammation; and (3) normal alveolar bone height. In 2001, moderate gingivitis not proportional to the amount of plaque and the child's age,<sup>21-23</sup> with no periodontitis, was again evident in teeth I, J, K, and L. Oral hygiene was reinforced. In 2002, severe gingivitis, bleeding on probing, abnormal tooth mobility in tooth I, and periodontitis affecting teeth B, C, H, I, and J became clear (Figure 6, Table 1). Retrospective examination of the previous radiographs revealed that incipient

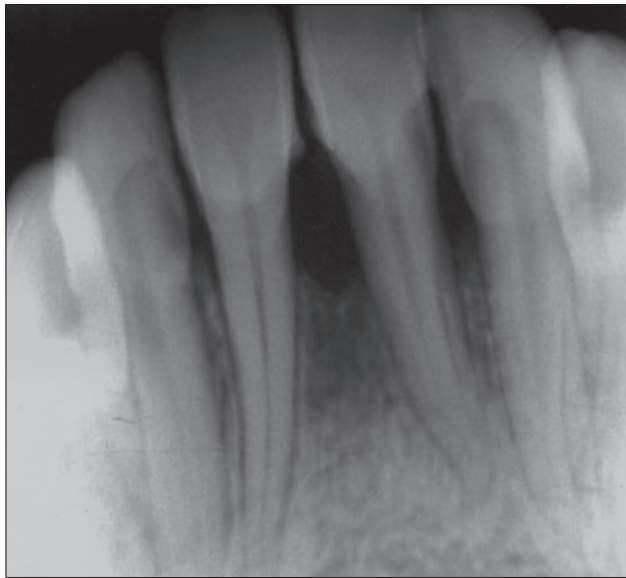


Figure 5. Anterior periapical radiograph of case No. 6. Aggressive periodontitis is evident affecting teeth No. 23, 24, and 25.

alveolar bone loss between teeth I and J was missed in the previous radiographic examination. Curettage and root planning followed by intrapocket chlorhexidine rinses, Periochip (a slow-release chlorhexidine chip) systemic antibiotic therapy with metronidazole and amoxicillin,<sup>7</sup> and intrapocket chlorhexidine rinses at various intervals for 6 weeks were performed.

When first examined in 1995,<sup>7</sup> the kindred included only 6 cases with periodontitis, and case No. 6, 8, 9, and 10 were disclosed 7 years and 18 months, 4 years, and 7 years later, respectively. It should be noted however, that case No. 6 was not thoroughly examined until 2002 at age 12, and it is possible that periodontal disease in the primary teeth was previously present but not disclosed. On the other hand, when case No. 8, 9, and 10 were first examined, they had neither clinical nor radiographic evidence of periodontal disease. Furthermore, the disease became clear after 18 months of the child's follow-up in case No. 8 (age 4 years), 3 years after the child's follow-up in case No. 9 (age 5 years), and 2 years after the follow-up in case No. 10 (age 5 years). In the last case, however, evidence of incipient periodontitis by age 4 was not noticed by the author. It is also of interest that case No. 5 and 7 did not receive the prescribed antibiotic therapy, and, while in case No. 5 the disease did not deteriorate, in case No. 7 it deteriorated from localized to generalized and severe.<sup>7</sup>

### Discussion

The fact that some families may show an increased prevalence of periodontitis,<sup>3-7,24-35</sup> and that siblings may suffer from severe periodontal diseases<sup>7,24-35</sup> have been previously reported in the literature. It should be emphasized, however, that in most of the reports on siblings with severe periodontitis, systemic conditions affecting the families were mentioned,<sup>24-33</sup> and only a few were not related to a

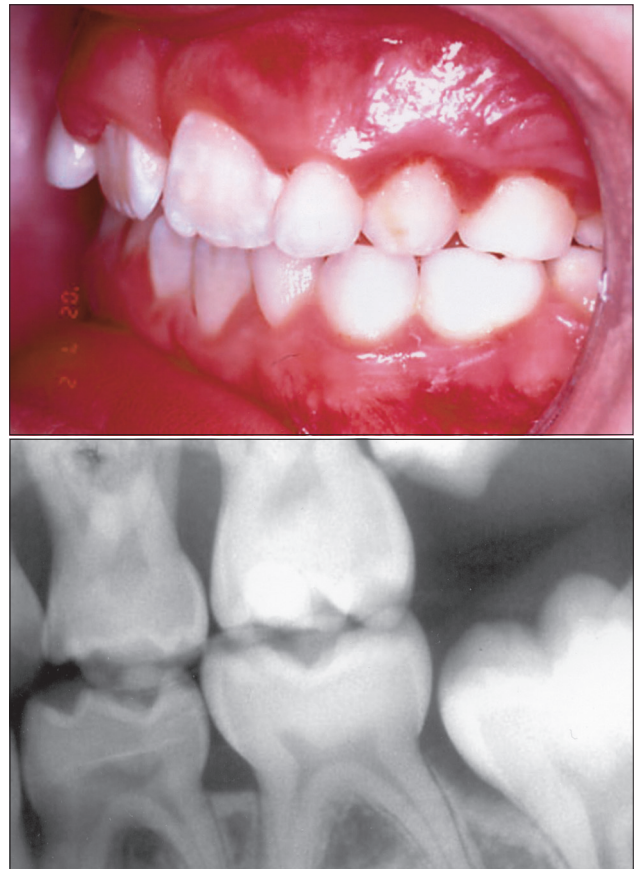

Figure 6. Clinical and radiographic images of case No. 10, 7 years after follow-up of the kindred, and 2 years after the follow-up of the child. Severe gingival inflammation and alveolar bone loss affecting teeth H, I, and J are evident.

**Table 1. Gender, Age in Years, Teeth Affected, and Year of Disclosure of Periodontitis in 10 Children of a Kindred Affected With Periodontitis**

Case No.	Gender	Age	Teeth affected	Year of disclosure
1	Male	9	A, B, C, H, I, J, K, L, M, R, S, T	1995
2	Male	7	A, B, C, I, L	1995
3	Female	9	B, M, L, S	1995
4	Female	9	A, B, I, J, K, L, S, T	1995
5	Female	8	S	1995
6	Female	6	23, 24, 25	2002
7	Male	5	A, B, C, D, E, F, G, H, I, L, S, T	1995
8	Female	3	O, P	1996
9	Female	5	B, I	1999
10	Male	5	B, C, H, I, J	2002

systemic condition<sup>7,34,35</sup> (Table 2). In most families, 3 or less children were affected. However, 1 manuscript reported periodontitis in 5 out of 10 (50%) and in 8 out of 13 (61%) siblings in 2 branches of a family,<sup>35</sup> and another<sup>29</sup> reported periodontitis in 5 out of 7 siblings

(71%). The kindred reported in the present manuscript is unique due to its large number of children, which facilitates the finding of a large number of children with periodontitis and shows an exceptionally high prevalence of periodontitis when branch A is considered independently (80%). It should be noted that, in the previous manuscript with a prevalence of periodontitis of 71% among siblings, abnormal polymorphonuclear leukocytes (PMN) chemotaxis was diagnosed in children with and without periodontal disease.<sup>29</sup>

The fact that the highest prevalence of childhood periodontitis and aggressive periodontitis affecting the permanent dentition of a child (case No. 6) were found in branch A—in which one of the parents had aggressive periodontitis—suggests that the severity of periodontitis of the parents is related to the number of children affected with periodontitis and the severity of the periodontal diseases they develop. This may be true concerning the prevalence and not the severity. However, since localized and generalized childhood periodontitis were found in both branches and child No. 6, due to her special systemic situation, was neither thoroughly examined nor treated until age 12 years, it may be possible that, if she had been diagnosed and treated previously for periodontitis in her primary teeth, she would have not developed periodontitis in her permanent teeth.

There is consensus that bacteria has a primary causative role in periodontal diseases.<sup>3-8,36-38</sup> However, increasing evidence indicates that other factors are also involved in the establishment and development of gingival and periodontal diseases. While it is difficult to determine the relative importance of each etiologic or facilitating factor for gingival and periodontal diseases, there is increasing data that indicates that environmental, dietary, behavioral, and systemic factors—including the genetic complement of the host—have an important role in gingival and periodontal disease initiation, progression, and response to treatment.<sup>9-13,36-38</sup> The complexity of the interaction between these factors is evident in the present kindred since:

1. *Actinobacillus actinomycetemcomitans* and *Porphyromonas gingivalis* were present in children who did or did not develop periodontal disease.<sup>7</sup>
2. *A actinomycetemcomitans* and *P gingivalis* were also present in the subgingival plaque after the affected children received antibiotic therapy.<sup>7</sup>
3. There was a wide range in the number of teeth affected per child (1-12) and the severity of the disease (Table 1).
4. Antibiotic treatment with amoxicillin and metronidazole<sup>7</sup> was required only once during the whole follow-up (up to 7 years, in most cases).
5. While 2 children (case No. 5 and 7) were not provided the recommended antibiotic therapy by their parents, only 1 (case No. 7) developed a more severe form of periodontal disease.

The difference between the 2 cases may be explained by the fact that case No. 5 had only 1 tooth affected with apparently inactive periodontitis (Figure 4), while case No. 7 had several teeth affected with active periodontitis (Table 1).

**Table 2. Reported Families With Siblings Affected With Periodontal Diseases**

No. of siblings	Systemic condition reported	Authors
2	None	Hofmann ID, 1983 <sup>34</sup>
7	Abnormalities in leukocyte chemotaxis in 3 siblings	Vandesteen et al, 1984 <sup>24</sup>
8	None	Spektor et al, 1985 <sup>35</sup>
5	None	Spektor et al, 1985 <sup>35</sup>
3	Hypophosphatasia, suppressed monocyte chemotaxis	Baab et al, 1985, 1986 <sup>25, 26</sup>
2	Papillon-Lefèvre syndrome in both siblings	Preus and Gjermo, 1987 <sup>28</sup>
2	Reduced PMNs chemotaxis in 1 sibling	Sbordone et al, 1990 <sup>27</sup>
5	Reduced PMNs chemotaxis in 2 siblings	Lopez, 1992 <sup>29</sup>
2	None	Petit et al, 1993 <sup>30</sup>
2	Papillon-Lefèvre syndrome	Petit et al, 1993 <sup>30</sup>
2	Hypophosphatasia	Plagman, 1994 <sup>31</sup>
2	Leukocyte adhesion deficiency	Waldtrop, 1995 <sup>32</sup>
7	None	Bimstein et al, 1997 <sup>7</sup>
2	Papillon-Lefèvre syndrome in both siblings	De Vree, 2000 <sup>33</sup>

Several reports suggest that the presence and severity of periodontal diseases in the primary dentition may be related to the presence and severity of periodontal diseases in the same individual at older ages.<sup>14-17</sup> Therefore, it may be concluded that the odds for recurrence of periodontal disease in children of the kindred who were diagnosed with periodontitis are very high. However, in only 1 child (case No. 2), was there suspicion of recurrence of periodontal disease. These findings may be related to the antibiotic treatment, which apparently caused changes in the periodontal flora that prevented the recurrence of the disease.

However, this assumption appears naive when trying to explain a disease that is related to a complicated interaction of factors. The success of antibiotic therapy for periodontitis with amoxicillin and metronidazole was first described in adults.<sup>39</sup> It represents an excellent option for the treatment of periodontitis in children that does not include the use of tetracyclines, which have been previously utilized in the treatment of periodontitis in children,<sup>40,41</sup> but may stain developing teeth.<sup>42</sup> Furthermore, the present report indicates that this systemic antibiotic regime is successful in the treatment of periodontitis in the primary dentition and the prevention of

recurrence of the disease in the primary teeth or its development in permanent teeth, at least until adolescence. This is of particular interest, since a previous study indicates that periodontopathic bacteria affecting the primary teeth may colonize erupted permanent teeth,<sup>43</sup> and neither the erupted permanent teeth nor the permanent teeth that erupted during the follow-up developed additional periodontal disease. This fact again emphasizes the need for and benefits of early diagnosis and treatment of periodontal diseases in the primary dentition.

The present report and previous literature indicate that early diagnosis and treatment of periodontal disease (as in many other diseases) have a definitive effect in the complexity of the treatment and its prognosis. Therefore, children with periodontitis in their primary dentition should frequently be examined; the period of time between visits should be decided individually for every case, based on (1) the disease severity and pace; and (2) the length and findings of the follow-up. It has been previously indicated that, when the severity of gingival inflammation is higher than expected in relation to the child's age and amount of dental plaque,<sup>21-23</sup> it should be considered a warning sign from an increased susceptibility to gingival and periodontal diseases.<sup>23,44</sup> This notion is evidenced by the findings in case No. 9 and 10, in which gingival inflammation which was not proportional to the child's age and amount of plaque were evident months before alveolar bone loss was disclosed. These findings suggest that:

1. In children who belong to families with a high prevalence of periodontal diseases, unexpected severe gingival inflammation is indicative of the need for systemic antibiotic therapy, with the purpose to prevent the establishment of periodontitis.
2. In families affected with periodontitis, all siblings must be carefully followed up to diagnose and treat gingival and periodontal diseases early.

A significant question that still remains unresolved is, does the present kindred have a concealed systemic disease that facilitates the establishment and progression of periodontal diseases? On one hand:

1. Examination by a pediatrician and laboratory analysis did not reveal any systemic disease.
2. The presence of a concealed systemic disease would have facilitated recurrence of the periodontal disease, and recurrence of periodontal disease was suspected in only 1 child in the present kindred.

On the other hand, one of the parents had Crohn's disease, which has been related to periodontal diseases.<sup>20,45</sup> This fact is of interest because, while periodontopathic bacteria are essential for the development of periodontitis, a susceptible host is also required for the development of periodontal diseases,<sup>46,47</sup> suggesting that this family has a genetic factor related to the immune system that facilitates the appearance of periodontal diseases. Secondly, case No. 2 had transient thrombocytopenia at age 5 years.<sup>7</sup> In any event, one should keep in mind that in the present kindred a systemic disease may still be concealed.

## Conclusions

1. Susceptible families develop a high prevalence of periodontitis.
2. All the children of these families, not only those with periodontitis, should be carefully monitored to provide early treatment when needed.
3. Severe gingival inflammation that does not correspond with the child's age or length and period of time of plaque accumulation should be considered a warning sign in every case. This is particularly true in families susceptible to periodontal diseases, for which the treating dentist should consider a more intense treatment than in families with normal prevalence of periodontal diseases. The prescription of systemic antibiotics<sup>7</sup> as a preventive measure for the prevention of the development of periodontitis should be included.
4. Treatment of children with periodontitis in the primary dentition may be successful, with no periodontitis developing in the permanent dentition in adolescence.

## References

1. Kinane DF. Periodontal disease in children and adolescents. *Periodontol* 2000. 2001;26.
2. Bimstein E, Needleman HL, Karinbux N, Van Dyke TE. *Periodontal and Gingival Health and Diseases. Children, Adolescents, and Young Adults*. London, England: Martin Dunitz Ltd; 2001.
3. Nishimura F, Nagai A, Kurimoto K, et al. A family study of a mother and daughter with increased susceptibility to early onset periodontitis: microbiological, immunological, host defensive, and genetic analyses. *J Periodontol*. 1990;61:755-762.
4. Gunsolley JC, Ranney RR, Zambon JJ, Burmeister JA, Schenkein HA. Actinomyces actinomycetemcomitans in families affected with periodontitis. *J Periodontol*. 1990;61:643-648.
5. Petit MD, Van Steenberg TJ, Scholte LM, Van der Velden U, De Graff JK. Epidemiology and transmission of Porphyromonas gingivalis and Actinomyces actinomycetemcomitans among children and their family members. A report of 4 surveys. *J Clin Periodontol*. 1993;20:641-650.
6. Asikainen A, Chen C, Slots J. Likelihood of transmitting Actinomyces actinomycetemcomitans and Porphyromonas gingivalis in families with periodontitis. *Oral Microbiol Immunol*. 1996;11:387-394.
7. Bimstein E, Sela MN, Shapira L. Clinical and microbiological considerations for the treatment of an extended kindred with 7 cases of prepubertal periodontitis: a 2-year follow-up. *Pediatr Dent*. 1997;19:396-403.
8. Ting M, Slots J. Microbiology of periodontal diseases. In: Bimstein E, Needleman HL, Karinbux N, Van Dyke TE. *Periodontal and Gingival Health and Diseases. Children, Adolescents, and Young Adults*. London, England: Martin Dunitz Ltd; 2001:169-187.
9. Offenbacher S. Periodontal diseases: pathogenesis. *Ann Periodontol*. 1996;1:821-878.

10. Michalowicz BS. Genetic and inheritance considerations in periodontal disease. *Curr Opin Periodontol.* 1993;11-17.
11. Shapira L, Schlesinger M, Bimstein E. Possible autosomal-dominant inheritance of prepubertal periodontitis in an extended kindred. *J Clin Periodontol.* 1997;24:388-393.
12. Kornman KS, di Giovine FS. Genetic variations in cytokine expression: a risk factor for severity of adult periodontitis. *Ann Periodontol.* 1998;3:327-338.
13. Hart TC. Genetic aspects of periodontal diseases. In: Bimstein E, Needleman HL, Karinbux N, Van Dyke TE. *Periodontal and Gingival Health and Diseases. Children, Adolescents, and Young Adults.* London, England: Martin Dunitz Ltd; 2001:189-204.
14. Sjödin B, Matsson L, Unell L, Egelberg J. A retrospective radiographic study of alveolar bone loss in the primary dentition in patients with juvenile periodontitis. *J Clin Periodontol.* 1989;16:124-127.
15. Sjödin B, Crossner CG, Unell L, Östlund P. Marginal bone loss in the primary dentition of patients with juvenile periodontitis. *J Clin Periodontol.* 1993;20:32-36.
16. Shapira L, Shmidt A, Van Dyke Th, Barak V, Soskolne AW, Brautbar Ch, Sela MN, Bimstein E. Sequential manifestation of different forms of early-onset periodontitis. A case report. *J Periodontol.* 1994;65:631-635.
17. Delima AJ, Sjödin BE, Tonetti MS, et al. In: Bimstein E, Needleman HL, Karinbux N, Van Dyke TE. *Periodontal and Gingival Health and Diseases. Children, Adolescents, and Young Adults.* London, England: Martin Dunitz Ltd; 2001:75-105.
18. Page RC, Bowen T, Altman L. Prepubertal periodontitis. 1. Definition of a clinical disease entity. *J Periodontol.* 1983;54:257-271.
19. Hamilton JR. The digestive system. In: Berham RE, Vaughan VC, eds. *Textbook of Pediatrics.* Philadelphia, Pa: WB Saunders Co; 1983:923-924.
20. Engel LD, Pasquinelli KL, Leone SA, Moncla BJ, Nielson KD, Rabinovitch PS. Abnormal lymphocyte profiles and leukotriene B4 status in a patient with Crohn's disease and severe periodontitis. *J Periodontol.* 1988;59:841-847.
21. Matsson L. Development of gingivitis in preschool children and young adults. A comparative experimental study. *J Clin Periodontol.* 1978;5:24-34.
22. Matsson L, Goldberg P. Gingival inflammatory reaction in children at different ages. *J Clin Periodontol.* 1985;12:98-103.
23. Bimstein E, Matsson L. Growth and development considerations in the diagnosis of gingivitis and periodontitis in children. *Pediatr Dent.* 1999;21:186-91.
24. Vandesteen GE, Williams BL, Ebersole JL, Altman LC. Clinical, microbiological, and immunological studies on a family with a high prevalence of early-onset periodontitis. *J Periodontol.* 1984;55:159-169.
25. Baab DA, Page RC, Morton T. Studies of a family manifesting premature exfoliation of deciduous teeth. *J Periodontol.* 1985;56:403-409.
26. Baab DA, Page RC, Ebersole JL, Willimas BL, Scott CR. Laboratory studies of a family manifesting premature exfoliation of deciduous teeth. *J Clin Periodontol.* 1986;13:677-683.
27. Sbordone L, Ramaglia L, Bucci E. Generalized juvenile periodontitis: report of a familial case followed for 5 years. *J Periodontol.* 1990;61:590-596.
28. Preus H, Gjermeo P. Clinical management of prepubertal periodontitis in 2 siblings with Papillon-Lefevre syndrome. *J Clin Periodontol.* 1987;14:156-160.
29. Lopez NJ. Clinical, laboratory, and immunological studies of a family with a high prevalence of generalized prepubertal periodontitis and juvenile periodontitis. *J Periodontol.* 1992;63:457-468.
30. Petit MD, van Steenberg TJ, Scholte LM, van der Velden U, de Graaf J. Epidemiology and transmission of Porphyromonas gingivalis and Actinobacillus actinomycetemcomitans among children and their family members. A report of 4 surveys. *J Clin Periodontol.* 1993;20:641-650.
31. Plagmann HC, Kocher T, Kuhrau N, Caliebe A. Periodontal manifestation of hypophosphatasia. A family case report. *J Clin Periodontol.* 1994;21:710-716.
32. Waldtrop TC, Hallmon WW, Mealey BL. Observations of root surfaces from patients with early-onset periodontitis and leukocyte adhesion deficiency. *J Clin Periodontol.* 1995;22:168-178.
33. De Vree H, Steenackers K, De Boever JA. Periodontal treatment of rapid progressive periodontitis in 2 siblings with Papillon-Lefevre syndrome: 15-year follow-up. *J Clin Periodontol.* 2000;27:354-360.
34. Hoffman ID. Familial occurrence of juvenile periodontitis with varied treatment of 1 of the siblings with 5-year follow-up. Case report. *J Periodontol.* 1983;54:44-49.
35. Spektor MD, Vandesteen GE, Page RC. Clinical studies of 1 family manifesting rapidly progressive juvenile and prepubertal periodontitis. *J Periodontol.* 1985;56:93-101.
36. Ranney RR, Debski BF, Tew JG. Pathogenesis of gingivitis and periodontal disease in children and young adults. *Pediatr Dent.* 1981;3:89-100.
37. Socransky SS, Haffajee AD. Microbial mechanisms in the pathogenesis of destructive periodontal diseases: a critical assessment. *J Periodontol Res.* 1991;26:195-212.
38. Schenkein HA. Pathogenesis of aggressive periodontitis. In: Bimstein E, Needleman HL, Karinbux N, Van Dyke TE. *Periodontal and Gingival Health and Diseases. Children, Adolescents, and Young Adults.* London, England: Martin Dunitz Ltd; 2001:147-197.
39. Pavicic MJ, van Winkelhorf AJ, Douque NH, Steures RW, de Graff J. Microbial and clinical effects of metronidazole and amoxicillin in Actinobacillus actinomycetemcomitans-associated periodontitis. *J Clin Periodontol.* 1994;21:107-112.
40. Mandell RL, Siegal MD, Umland E. Localized juvenile periodontitis of the primary dentition. *J Dent Child.* 1986;53:193-196.

41. Ngan PH, Tsai C, Sweeney E. Advanced periodontitis in the primary dentition; a case report. *Pediatr Dent*. 1985;4:255-258.
42. Pindborg JJ. Discolorations. In: *Pathology of the Dental Hard Tissues*. Philadelphia, Pa: Saunders; 1970:211.
43. Dibart S, Chapple IL, Skobe Z, et al. Microbial findings in prepubertal periodontitis. A case report. *J Periodontol*. 1998;69:1172-1775.
44. Needleman HL, Newman HN, Bimstein E. Introduction. In: Bimstein E, Needleman HL, Karinbux N, Van Dyke TE. *Periodontal and Gingival Health and Diseases. Children, Adolescents, and Young Adults*. London, England: Martin Dunitz Ltd; 2001:4-16.
45. Scheper HJ, Brand HS. Oral aspects of Crohn's disease. *Int Dent J*. 2002;52:163-172.
46. Ting M, Slots J. Microbiology of periodontal diseases. In: Bimstein E, Needleman HL, Karinbux N, Van Dyke TE. *Periodontal and Gingival Health and Diseases. Children, Adolescents, and Young Adults*. London, England: Martin Dunitz Ltd; 2001:169-187.
47. Hart TC. Genetic aspects of periodontal disease. In: Bimstein E, Needleman HL, Karinbux N, Van Dyke TE. *Periodontal and Gingival Health and Diseases. Children, Adolescents, and Young Adults*. London, England: Martin Dunitz Ltd; 2001:189-204.

#### ABSTRACT OF THE SCIENTIFIC LITERATURE



### PREDICTING CARIES IN PERMANENT TEETH FROM CARIES IN PRIMARY TEETH: AN 8-YEAR COHORT STUDY

This longitudinal, cohort study sought to determine if caries in the primary dentition can predict caries in the permanent dentition of the same individuals and, if so, with what degree of prediction accuracy. A total of 362 Chinese children, from 3 to 5 years old at the time of the baseline study, were re-examined 8 years later. The study found significant associations between caries prevalence in primary and permanent dentitions. Children having caries in their primary teeth were 3 times more likely to develop caries in their permanent teeth (relative risk ratio=2.6). Caries on primary molars had the highest predictive value (the probability that a child will have caries given that he/she has had caries on primary molars at baseline=85%). This study found that the best indicator of sensitivity (the probability that the child who now has caries in the permanent teeth also has or had caries in the primary teeth=94%) was caries on any of the primary molars. The best indicator of specificity (the probability that the child does not have caries in permanent teeth, given that there was no caries in the primary teeth=98%) was caries on all maxillary anterior teeth.

**Comments:** Many studies have reported that caries in primary teeth is correlated with caries in permanent teeth. This study refines future caries prediction not only on overall risk prediction but also on specific groups of primary teeth involved. It will be interesting to find out how full-mouth rehabilitation of ECC has an effect on caries incidence in the permanent dentition. The main drawback of this study was that caries diagnostic criteria were based on exclusion of noncavitation (enamel caries lesion) for caries-risk prediction. **GVK**

*Address correspondence to Y. Li, Department of Basic Science and Craniofacial Biology, New York University College of Dentistry, 345 E. 24th Street, New York, NY 10010-4086. yihong.li@nyu.edu*

**Li Y, Wang W. Predicting caries in permanent teeth from caries in primary teeth: an 8-year cohort study. *J Dent Res*. 2002;81:561-566.**

28 references