

Eruptive malpositioning of the mandibular permanent lateral incisors: three case reports

E. Jayni Bradley, DMD Ronald A. Bell, DDS, MEd

Abstract

Ectopic eruption of the mandibular permanent lateral incisors involving the loss of the adjacent primary canines is not uncommon, yet the extreme distalization and transposition of such teeth (partial or true) has been reported infrequently. Three cases that illustrate various anomalous eruption-exfoliation patterns are presented. Theories that attempt to explain the etiology of anomalous eruption positions are discussed. However, the multifactorial process of growth and development makes it difficult to identify specific primary etiological factors. Treatment options also are discussed and illustrated, with emphasis on early orthodontic intervention for optimal results.

Introduction

The mandibular permanent lateral incisors commonly are involved in developmental patterns evidencing atypical paths of eruption and anomalous positioning. The anomalous eruption patterns are associated with over-retained primary incisor teeth, atypical resorption with premature loss of adjacent primary teeth, and malpositioning of adjacent permanent teeth. Many approaches have been proposed to describe and explain accurately the occurrence of the atypical eruption and exfoliation patterns, and their clinical implications and management. This paper presents three cases involving displacement of the mandibular permanent lateral incisors with severe disruption of arch integrity and development. The case reports will be used as a focus for a review of the literature that includes classification, etiology, and treatment considerations in managing anomalous eruption patterns.

Literature Review

The terms ectopic eruption and transposition have been used to describe a wide range of positional anomalies in tooth eruption and exfoliation patterns. Ectopic eruption has been used to describe an abnormality of positioning involving adjacent teeth (Sweet

1939; Ruprecht et al. 1984), and the partial or total resorption of the root(s) of the associated primary tooth (O'Meara 1962). Schaad and Thompson (1974) and Shapira and Kuftinec (1982) did not limit the eruption patterns to adjacent teeth, but included any place normally occupied by another tooth that may or may not cause abnormal resorption of a primary tooth. Mader and Konzelman (1979) addressed positional anomalies in terms of transposition, suggesting that true transposition occurs when one tooth occupies another's normal position in the arch. Other authors have used this extreme form of ectopic eruption (i.e., transposition) to describe severe displacement of a tooth having the potential of developing into true transposition (Platzer 1968; Joshi and Bhatt 1975; Winter 1980; Ruprecht et al. 1985; Maric 1987). Anything short of this represents a partial or incomplete transposition (Mader and Konzelman 1979; Maric 1987). More general descriptions, e.g. anomaly of position, atypical path of eruption, and even directional adjectives, may be used in reference to eruption displacements in describing individual cases which fall into the gray area between the strict definitions.

The frequency of eruption anomalies involving ectopic and transpositional occurrences varies according to the terminology chosen by the reporting author, and the degree of displacement shown in the reported cases. Ectopic eruption patterns involving permanent teeth with associated resorption of adjacent primary teeth have been reported in ranges from 2 to 12%, depending on the teeth involved. Wessels (1948) found that approximately 12% of 564 patients exhibited ectopic eruption of at least one permanent lateral incisor with the mandibular permanent laterals most commonly involved, along with atypical resorption or premature loss of the adjacent primary canines. Sweet (1939), Nikiforuk (1948), Byrd (1954), and O'Meara (1962) also found that the mandibular permanent lateral incisors

were the teeth that most often erupted ectopically. O'Meara's 1962 study of 315 patients with documented occurrence of ectopic erupting permanent teeth found 30% involved the mandibular permanent lateral incisors with no gender preference noted, and an equal occurrence of unilateral versus bilateral ectopic eruption patterns.

Case reports of transposition, partial or complete, involving the mandibular permanent incisors and canines are infrequent in the literature. In 14 articles concerning mandibular permanent lateral incisor eruption distal to the canine, 18 of 66 reported cases occurred bilaterally (Rose 1958; Vega 1959; Dixon 1963; Platzer 1968; Taylor and Hamilton 1971; Pifer 1973; Schaad and Thompson 1974; Mollin 1977; Shapira 1980; Kryshalskyj 1982; Shapira and Kuffinec 1982; Shapira and Kuffinec 1983; Woelfel 1984; Maric 1987). No gender preference was shown in these reports, but there was a 2:1 ratio of right side to left side occurrence. These articles were clinical case reports that primarily emphasized the clinical findings and treatment options, which ranged from extracting the involved incisors, to maintaining the teeth in the transposed location, to repositioning the teeth in the proper arch alignment. That the occurrence of such extreme positional anomalies is uncommon is best illustrated by the following population surveys. Buenviaji and Rapp (1984) reported that transposed teeth had a prevalence of 0.08% in a population of 2439 children, 2-12 years old. Jarvinen (1982) reported a frequency of 0.03% transposition involving the mandibular canine and lateral incisor among 13,712 children, 8-9 years old.

Case 1

A 10-year, 5-month-old Caucasian girl was referred to the Pediatric Dental Clinic of the Medical College of Georgia with a chief complaint of "pain in jaw" and "double teeth." Clinical examination revealed eruption of the mandibular permanent lateral incisors in a position lingual to the first premolar on both right and left sides. The permanent canines were not erupted. The primary right canine and both primary lateral incisors were retained, as were the primary second molars (Fig 1a). The overall mandibular arch length had excess space, and the developmental stage of the teeth was within normal limits. Maxillary arch development was within normal limits. The maxillary lateral incisors were peg shaped. The interarch relationships exhibited end-to-end molars bilaterally, a 50% overbite, and 4 mm overjet. Radiographic examination revealed a normal complement of teeth, though atypical positioning and sequencing of the permanent teeth were noted, including rotation of unerupted mandibular second premolars (Fig 1b). The mandibular permanent lateral incisors showed severe distal tipping, distolingual dis-

placement, and mesiolingual rotation of their crown positions, while the root apices appeared to be positioned normally relative to the unerupted permanent canines (Fig 1c).

Orthodontic treatment was planned to reposition the lateral incisors in the normal arch alignment. The first phase of treatment was initiated with extraction of the mandibular primary lateral incisors and the remaining primary canine. For anchorage, the mandibular permanent first molars were banded with a soldered facial 0.036 stainless steel arch wire with elastic hooks anterior to the incisors (Fig 1d). Edgewise, 0.022 slot brackets were bonded to the displaced laterals. Using continuous elastic modules from the heavy facial arch wire to the lateral incisor brackets, the lateral crowns were moved slowly forward with a tipping movement until they were aligned in the general arch form. Advantages of using the facial arch wire with hooks for engaging the elastomeric chain included anchorage, control, avoidance of bracketing and orthodontic engagement of normal positioned teeth, maintenance of the labial position of the permanent central incisors, and allowance of free eruptive alignment of the buccal segments. After the initial tooth positioning, the facial arch wire was removed and the four permanent incisors and permanent first molars were bracketed for leveling and alignment. Progressive arch wire changes from 0.016 nickel titanium to 0.020 stainless steel accomplished alignment of incisors before the canines erupted.

As remaining permanent teeth erupted, brackets were added and engaged to correct significant rotations of the premolars and right canine, and excessive spacing. Space consolidation was achieved on 0.020 round stainless steel arch wire using sliding mechanics (Figs 1e and 1f). Active treatment time was 17 months to achieve Class I buccal segments.

Case 2

A 9-year-old, Caucasian boy, presented to the Pediatric Dental Clinic at the Medical College of Georgia. He was referred from a private practitioner with a chief complaint of a misplaced tooth. Clinical examination revealed eruption of the mandibular permanent right lateral incisor into the first premolar space (Fig 2a, see page 384). The clinical crown exhibited mesiolingual rotation and distolabial inclination. The primary right lateral and primary right canine were retained, while the primary right first molar had exfoliated prematurely. The mandibular dental midline was 1 mm to the right of the facial midline: no functional deviation was noted. The permanent first molars occluded in an end-to-end relationship. Upper arch development and alignment was within normal limits. Radiographically, the mandibular permanent right lateral incisor was tipped severely distally, and the root apex appeared

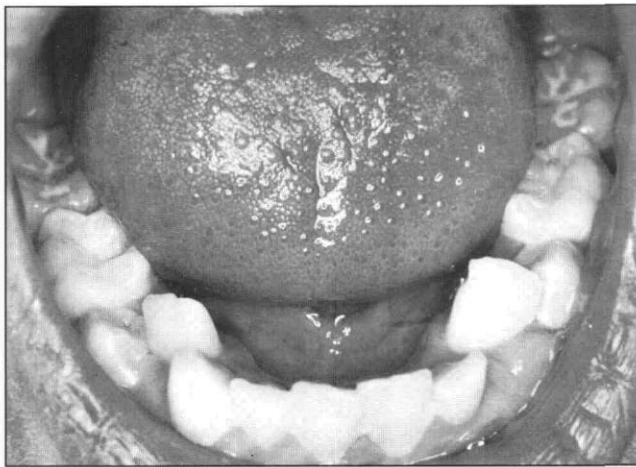


Fig. 1a

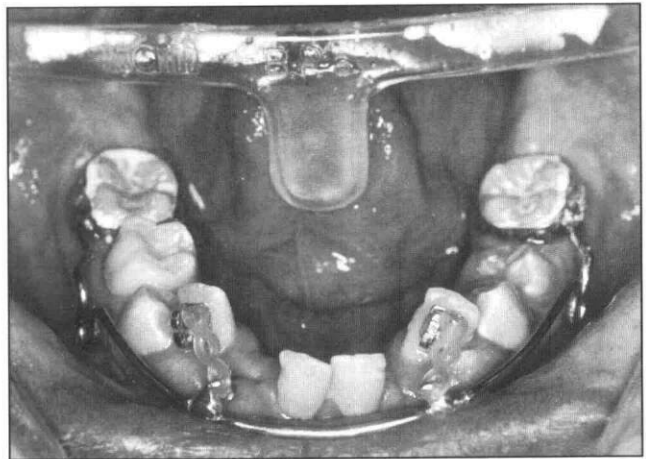


Fig. 1d

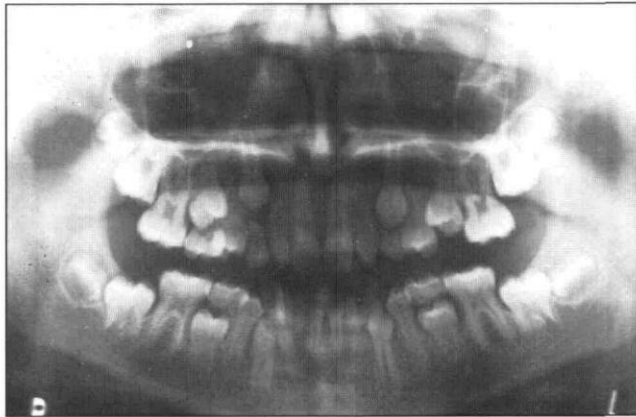


Fig. 1b

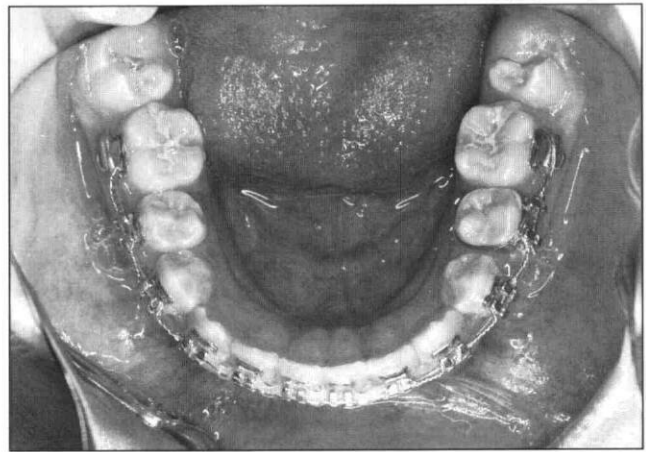


Fig. 1e

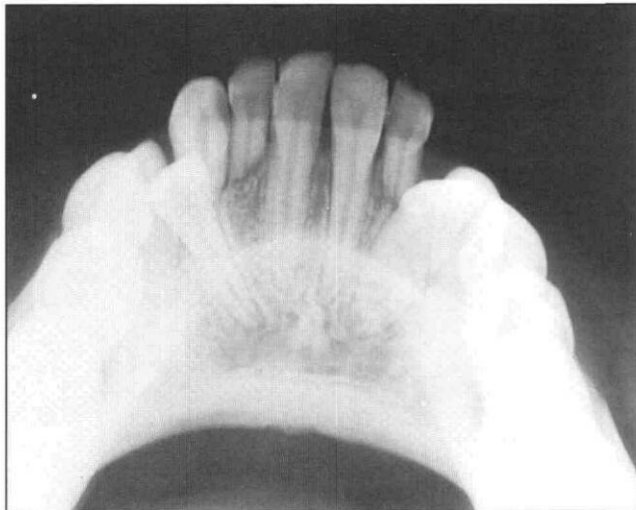

Fig. 1c

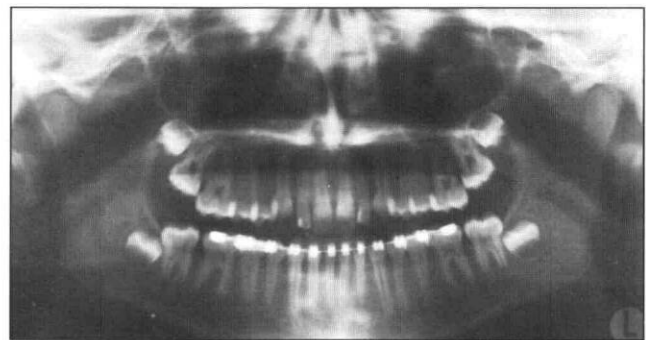


Fig. 1f

Fig 1. Bilateral displacement of permanent mandibular lateral incisors of case #1 at the initial clinical examination (1a); initial radiographs including a panorex (1b); and an occlusal view (1c). Treatment was initiated using a soldered labial bow and elastomerics (1d). With eruption of the permanent dentition, treatment advanced to a full bonded arch (1e) and stabilized as shown in the panoramic radiograph (1f).

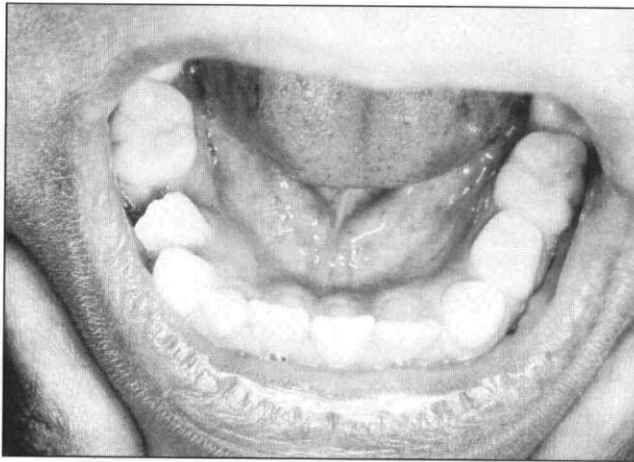


Fig. 2a

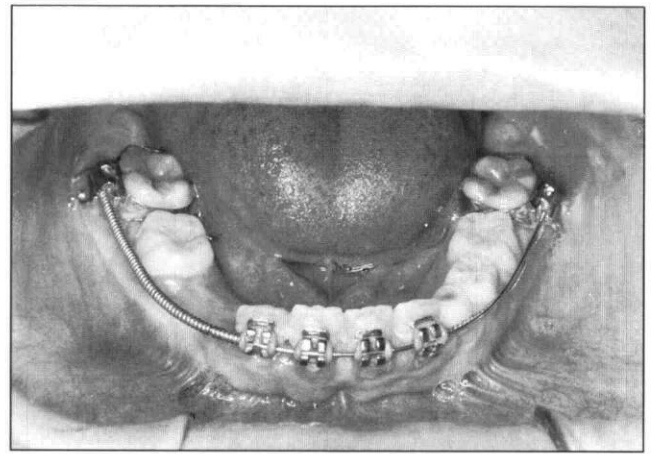


Fig. 2d

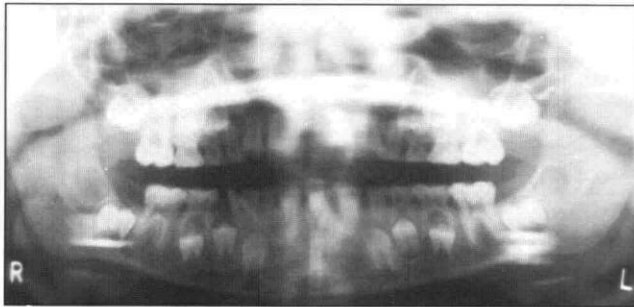


Fig. 2b

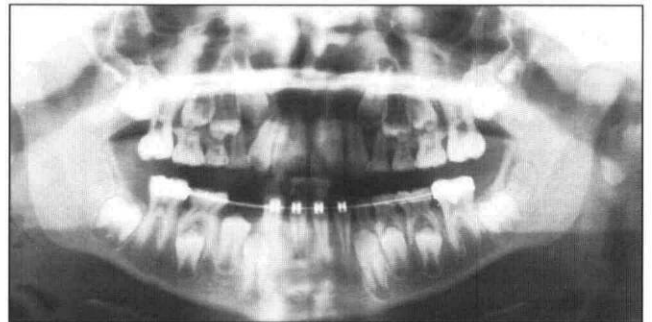


Fig. 2e

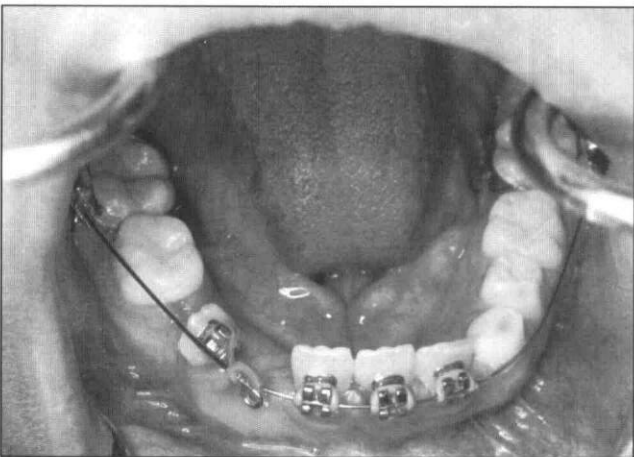


Fig. 2c

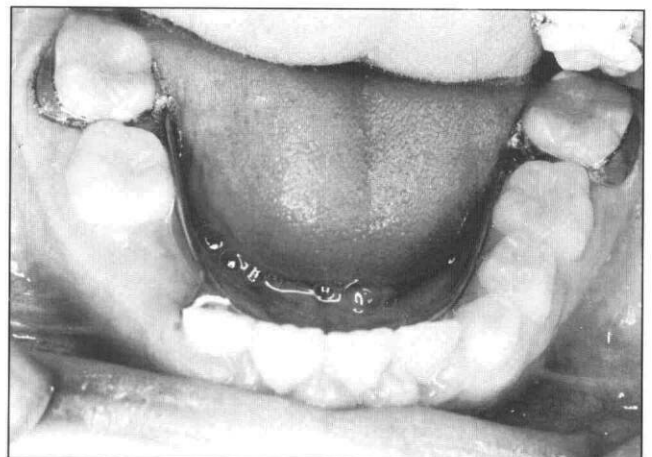

Fig. 2f

Fig 2. Pretreatment clinical view of case #2 with unilateral displacement of the right permanent mandibular lateral incisor (2a), and panoramic radiographic view (2b). Initial appliance placement using edgewise appliance and elastomeric chain (2c); appliance adjusted for midline shift with an open coil spring (2d); panoramic radiograph prior to retention phase (2e); post-treatment retainer using a modified lingual holding arch (2f).

distally malpositioned (Fig 2b). The developmental timing and sequencing of the permanent canines and premolars was within normal limits.

Treatment began with the extraction of the right primary canine and primary lateral incisor. The permanent mandibular first molars were banded, and all mandibular incisors were bonded with an edgewise 0.022 slot appliance. The initial arch wire, an 0.020 stainless steel with a loop bent distal to the right central incisor, was detailed for passive engagement of the right central, left central, and left lateral incisor. The loop was used to attach elastomeric chain to the right lateral incisor for movement toward the proper arch form position (Fig 2c). Once general alignment of the right lateral was obtained, the full segment of lower incisors were engaged with an 0.016 nickel titanium arch wire. Arch wire size was advanced progressively from the 0.016 nickel titanium to a 0.020 nickel titanium, and to an 0.020 stainless steel. An open coil spring was used on the 0.020 stainless steel arch wire from the right first molar to the lateral incisor to promote a dental midline shift to the left (Fig 2d). Upon proper alignment of the lower incisors on the facial midline, the edgewise appliances were removed and a lingual holding arch with a spur to the distal of the right lateral incisor was used as a retainer (Fig 2e and 2f). Active treatment time was nine months.

Case 3

A 9-year, 2-month-old Caucasian boy was referred to the Pediatric Dental Clinic at the Medical College of Georgia by the Public Health Department. The chief complaint was "painful, aching teeth." Clinical examination revealed eruption of mandibular permanent lateral incisors into the first premolar space, with labioversion and distobuccal rotation (Fig 3a). Both primary canines and primary lateral incisors were retained, with apparent early loss of the primary first molars. The permanent mandibular central incisors each were rotated mesially approximately 45°. The permanent first molars occluded end to end. Radiographic examination revealed severe distal tipping of the mandibular lateral incisors, and distal displacement of their root apices (Fig 3b). The unerupted, developing right and left first premolars, as well as the left permanent canine, were tipped distally. The right permanent canine appeared to be displaced mesially. Initiation of active eruption of the permanent canines in association with the lateral incisor displacement seemed to be the source of pain. Tooth size-arch size analysis revealed an overall arch length deficiency of 5 mm on the right side, and 4 mm on the left side.

The tooth-jaw size discrepancy, the active eruption of the canines, and the anomalous tooth positions led to a first recommendation of Phase I orthodontics to opti-

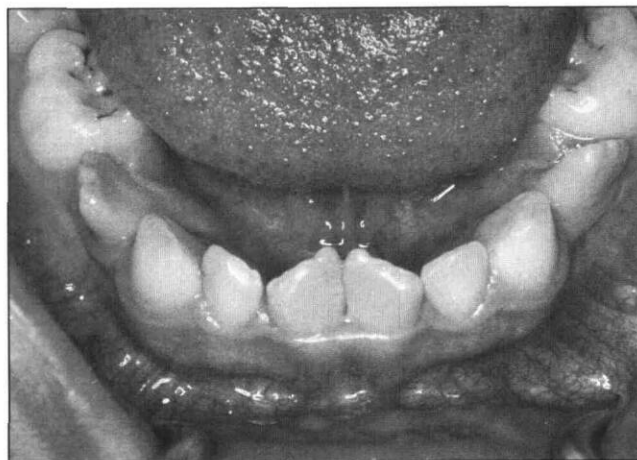


Fig. 3a

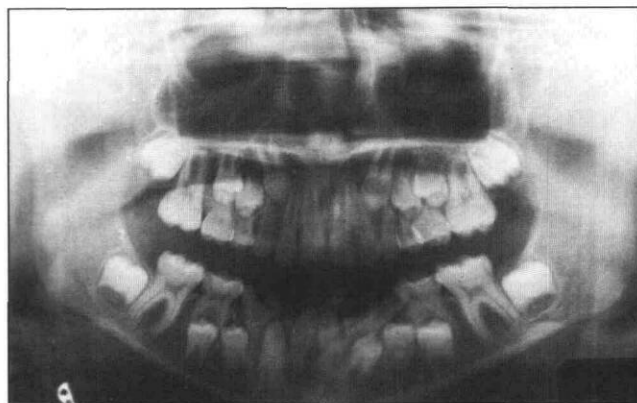


Fig. 3b

Fig 3. Bilateral displacement of permanent mandibular lateral incisors, case #3: pretreatment clinical view (3a) and panoramic radiographic view (3b).

mize alignment of the mandibular anteriors in preparation for comprehensive orthodontics. After parental consultation, a secondary option was chosen that involved extracting the malposed laterals, and future monitoring of eruption-alignment patterns. The patient never returned after the extractions; therefore, follow-up was not possible. While extraction was not the ideal choice, the severe crowding and eruption patterns, and the parental attitude toward orthodontic treatment, justified removing the severely malposed teeth (Schaad and Thompson 1974; Shapira and Kuflinec 1982).

Discussion

The normal developmental position of the mandibular permanent lateral incisor is lingual to its predecessor, with an expected lingual eruption pattern (Gellin 1961; Lee 1980; Gellin and Haley 1982). As a permanent tooth erupts, the eruptive pathway is delineated by

rapid osteoclastic activity along the cord of dental lamina connecting the fibrocellular follicle to the oral mucous membrane (ten Cate 1980). Most authors agree that labial migration upon eruption is inherent as long as the roots of the primary lateral incisors resorb and the functional forces of the perioral musculature are normal. The normal eruptive patterns may be influenced or altered by root development patterns, vascular and tissue fluid pressure, periodontal ligament contracture, deficient arch space, selective deposition and resorption of bone, and developmental anomalies (Sutton 1969; ten Cate 1980).

Migration caused by direct displacement may result from a local abnormality, such as the presence of a supernumerary tooth, an odontoma (Shapira et al. 1982), or a dentigerous cyst (Joshi and Bhatt 1971). However, these are very unlikely to occur in the anterior mandibular arch; whereas trauma, inflammatory lesions, or benign nonodontogenic neoplasms are more likely. The more common explanation is the occurrence of ankylosed or overretained primary teeth. Rose (1958) suggested that their retention could deflect successors from normal eruption paths. When considering mandibular permanent lateral incisors with their natural lingual positioning, the deep location and long slow path of eruption of the adjacent developing canine can provide ample opportunity for such deflection to occur. Each of the cases presented involved retained primary incisors and primary canines, along with the early loss of the first primary molar associated with the ectopic eruption of the mandibular permanent lateral incisor. Similar cases were reported by Dixon (1963) and Platzer (1968). In the cases described by Dixon (1963) however, only two of 15 had retained primary teeth. It is still unclear whether retained primary teeth may be the result, rather than the cause, of ectopic eruption of their successors. Resorption of a primary lateral may be delayed because its successor was not in the right position to provide the resorptive pressure; thus, the retention is a secondary feature. The rotations of the laterals observed by Dixon (1963) are noteworthy, as he described a pattern of mesiolingual rotation when the lower incisors are in linguoversion to the canines and distolingual rotation when in a labial position due to root morphology. An extreme distolingual displacement with a mesiolingual rotation may result in premature loss of the primary first molar and blockage of the first premolar (Dixon 1963; Platzer 1968). Similar rotational and eruption-exfoliation patterns were exhibited in each of the cases reported.

At the time the mandibular permanent central incisors erupt, space within the incisor segment can appear deficient (ten Cate 1980). With the eruption of the lateral incisors, however, the intercanine width increases an

average of 2–3 mm; this helps to relieve lower incisor liability (Baume 1950; Moorrees and Chadha 1965). If there is lingual malpositioning of the lateral with a reduced wedging effect during its eruption, the intercanine space may not develop to its usual potential. Severe crowding-arch length deficiency was ruled out as a probable cause in Shapira and Kuflinec's 1982 report of seven cases and Taylor and Hamilton's 1971 report of 16 cases, yet all 11 of Schaad and Thompson's (1974) cases exhibited crowding. Our first case exhibited excessive spacing, the second case presented normal arch circumference and tooth sizes, and the third case exhibited severe crowding with an obvious tooth size-arch size discrepancy.

Migration of a tooth from its normal path of eruption explains partial transposition and misplacement of a tooth more than one position away (Mader and Konzelman 1974). Mader and Konzelman (1974) argued that if two teeth were truly transposed, their anlagen had to be transposed during odontogenesis. Nolla (1960) observed that few corresponding teeth develop differently between right and left locations of the arch. Stafne (1985) suggested that a bilateral occurrence originated in the anlage stage of development and not a change in position in the course of eruption, while a bilateral occurrence in brothers reported by Allen (1967), Joshi and Bhatt (1971), and Newman (1977) are strongly suggestive of heredity. Marks and Cahill (1987) wrote of the genetic control within the dental follicle to explain eruption as a localized, bilaterally symmetrical series of events, and Sperber (1967) considered genetic intervention as a causative factor in eruption anomalies.

The prior discussion of possible etiological factors offers speculative explanations, but no firm conclusion can be drawn given the multifactorial possibilities and the sporadic, limited number of case reports. Independent of specific cause, there is the need for clinical management of the atypical eruption patterns. The choice of treatment approach depends upon the degree of displacement, the arch length discrepancy, location of the root apex, amount of eruption, overall dental development, and patient compliance. Options include no treatment, removal of malposed teeth, orthodontic intervention, occlusal equilibration, fixed prosthodontics with associated endodontics, and possible surgical transplantation. The latter has not been addressed specifically in association with this type of positional anomaly, but its potential seems feasible. When there is an arch length deficiency to the degree that a serial extraction protocol may be indicated, extraction of the displaced mandibular permanent lateral incisor may be a viable treatment option when it first erupts (Taylor and Hamilton 1971; Schaad and

Thompson 1974; Shapira and Kuftinec 1982). When the canine and lateral incisor are completely transposed, or demonstrate a great potential for transposition, no intervention may be a reasonable course of action, assuming acceptable function, periodontal health, and esthetics can be achieved with occlusal-incisal reduction and restoration. Extreme adjustments may involve endodontic treatment, crown restoration, and periodontal contouring.

Early diagnosis of the atypical eruption patterns usually offers the option of first choice — the orthodontic movement of the displaced teeth into normal arch alignment. Shapira and Kuftinec (1982) addressed the difficulty of orthodontic repositioning due to the high degree of distal displacement, severe rotation, and potential development of transposition with the erupting canine. If teeth are repositioned, there is a strong tendency for relapse requiring a long retention period. Early identification of the problem before the permanent canines and the first premolars erupt, however, tends to optimize tooth movements in achieving acceptable alignment, while minimizing severe arch collapse and asymmetry. In the two cases presented that involved orthodontic repositioning, simple labial arch wires and/or segmental molar-incisor edgewise appliances achieved acceptable arch alignments before final arch development.

Summary

Eruptive malpositioning, whether it involves ectopic eruption or transposition, can involve any tooth to some degree. The mandibular permanent lateral incisors ectopically erupt quite frequently with loss of the adjacent primary canines, yet their extreme distal malpositioning with transposition (partial or true) has been reported infrequently. Three cases were presented that illustrated various manifestations of these anomalous eruption and exfoliation patterns. Numerous theories exist to explain the etiology of anomalous eruption positions, but it is usually difficult to specify the primary etiological factor for a particular case because of its multifactorial basis.

Early intervention is recommended, with more limited treatment options available as time progresses. Orthodontic treatment before permanent canine eruption can reduce the time and complexity of treatment involved, and return the patient to normal arch alignment if teeth are not totally transposed or a severe arch perimeter deficiency exists.

This case report was conducted in partial fulfillment of residency requirements for the Pediatric Dentistry Department at the Medical College of Georgia, Augusta, GA.

The authors thank Ms. Bonita Rouse and Dr. Fouad Salama for their assistance.

Dr. Bradley is a dental consultant for the East Central District of the Georgia Public Health Department, Augusta, GA. Dr. Bell is professor, Department of Orthodontics and Pediatric Dentistry, College of Dental Medicine, Medical University of South Carolina, Charleston, SC.

- Allen WA: Bilateral transposition of teeth in two brothers. *Br Dent J* 123:439-40, 1967.
- Baume LJ: Physiological tooth migration and its significance for the development of occlusion. II The biogenesis of accessional dentition. *J Dent Res* 29:331-37, 1950.
- Buenviaje TM, Rapp R: Dental anomalies in children: a clinical and radiographic survey. *ASDC J Dent Child* 51:42-46, 1984.
- Byrd WM: Prevalence of ectopic eruption of the permanent teeth in children between 4 and 10 years of age. Master's thesis, University of North Carolina, 1954.
- Dixon DA: Ectopic eruption of the permanent lower lateral incisor. *European Orthodont Soc Tr*, pp 242-50, 1963.
- Gellin ME: A method of predicting the initial eruptive pattern of the mandibular permanent anterior teeth by radiographic analysis. *J Dent Child* 28:138-49, 1961.
- Gellin ME, Haley JV: Managing cases of overretention of mandibular primary incisors where their permanent successors erupt lingually. *J Dent Child* 49:118-22, 1982.
- Joshi MR, Bhatt NA: Canine transposition. *Oral Surg* 31:49-54, 1971.
- Kryshalskyj B: A rare case of bilateral mandibular canine-lateral incisor transposition. *Ontario Dentist* 59:31-35, 1982.
- Lee KP: Behavior of erupting crowded lower incisors. *J Clin Orthod* 14:24-33, 1980.
- Mader C, Konzelman JL: Transposition of teeth. *J Am Dent Assoc* 98:412-13, 1979.
- Maric D: Transposition of teeth. *Med Pregl* 40:297-300, 1987 (Eng. abstr.).
- Marks SC, Cahill DR: Regional control by the dental follicle of alterations in alveolar bone metabolism during tooth eruption. *J Oral Pathol* 16:164-69, 1987.
- Mollin AD: Transposition of teeth. *Quintessence Int* 8:45-51, 1977.
- Moorrees CFA, Chadha JM: Available space for the incisors during dental development — a growth study based on physiological age. *Angle Orthod* 35:12-22, 1965.
- Newman GV: Transposition: orthodontic treatment. *J Am Dent Assoc* 94:544-47, 1977.
- Nikiforuk G: Ectopic eruption: discussion and clinical report. *J Ont Dent Assoc* 25:241-46, 1948.
- Nolla CM: The development of the permanent teeth. *J Dent Child* 27:254-66, 1960.
- O'Meara WF: Ectopic eruption pattern in selected permanent teeth. *J Dent Res* 41:607-16, 1962.
- Pifer RG: Bilateral transposed mandibular teeth. *Oral Surg* 36:145, 1973.
- Platzer KM: Mandibular incisor-canine transposition. *J Am Dent Assoc* 76:778-84, 1968.
- Rose JS: Atypical paths of eruption: some causes and effects. *Dent P* 9:69-76, 1958.
- Ruprecht A, Sastry KARH, Batniji S: Transposition of teeth. *J Can Dent Assoc* 50:308-09, 1984.
- Ruprecht A, Batniji S, El-Neweihi E: The incidence of transposition of teeth in dental patients. *J Pedod* 9:244-49, 1985.
- Schaad TD, Thompson HE: Extreme ectopic eruption of the lower permanent lateral incisor. *Am J Orthod* 66:280-86, 1974.
- Shapira Y: Transposition of canines. *J Am Dent Assoc* 100:710-12, 1980.
- Shapira Y, Kuftinec M: The ectopically erupted mandibular lateral incisor. *Am J Orthod* 82:426-29, 1982.

- Shapira Y, Mischler WA, Kuftinec MM: The displaced mandibular canine. *ASDC J Dent Child* 49:362-64, 1982.
- Shapira Y, Kuftinec MM: Orthodontic management of mandibular canine-incisor transposition. *Am J Orthod* 83:271-76, 1983.
- Sperber GH: Genetic mechanisms and anomalies in odontogenesis. *J Can Dent Assoc* 33:433-42, 1967.
- Stafne EC: *Stafne's Oral Radiographic Diagnosis*. Gibilisco JA ed. Philadelphia: WB Saunders Co, 1985, p 28.
- Sutton PRN: Migration and eruption of non-erupted teeth: a suggested mechanism. *Aust Dent J* 14:269-70, 1969.
- Sweet CA: Ectopic eruption of permanent teeth. *J Am Dent Assoc* 26:574-79, 1939.
- Taylor GS, Hamilton MC: Ectopic eruption of lower lateral incisors. *J Dent Child* 38:282-84, 1971.
- ten Cate AR: *Oral Histology: Development, Structure, and Function*. St. Louis: The CV Mosby Co, 1980, pp 270-89.
- Vega JS: Transposed teeth: report of a case. *J Am Dent Assoc* 59:750, 1959.
- Wessels KE: Premature deciduous cuspid root resorption accompanying permanent lateral incisor eruption. Master's thesis, State University of Iowa, 1948.
- Winter AA: Pseudotranspositioning. *Oral Surg* 49:188, 1980.
- Woelfel JB: *Dental Anatomy: Its Correlation to Dental Health Service*. Philadelphia: Lea and Febiger, 1984, pp 242-43.

Hepatitis B as serious as AIDS

Americans need to take hepatitis B as seriously as they do HIV infection, according to Dr. Louis W. Sullivan, secretary of the Department of Health and Human Services.

Sullivan, speaking at the National Forum on AIDS and Hepatitis B, said, "Even health care workers, who should know better, have a problem taking hepatitis B seriously. A Centers for Disease Control survey of hospitals with vaccination programs found that only 36% of health care workers have received the vaccination."

As many as 12,000 health care workers contract hepatitis B annually while caring for patients, and as many as 300 of those die in a year of liver-related illnesses, according to research.

Both the AIDS virus and the hepatitis B virus can be spread through sexual intercourse, contact with infected blood, and the use of contaminated needles, and both can be transferred from mother to infant. Records indicate that approximately 300 million people carry the hepatitis B virus worldwide, compared with about 15 million carriers of the AIDS virus.