

## Immature primary molar in the newborn

Stephen K Brandt, DDS  
Steven D. Shapiro, MS, DMD  
Paul E. Kittle, DDS

### Abstract

*A clinical report of an erupted immature primary molar in a newborn is presented. The occurrence of a natal or neonatal molar can be considered a rare event since the majority of cases described are incisors. Clinical appearance, location, histological and radiographical examinations were used to establish the identity of the lesion. The literature related to natal and neonatal teeth is reviewed with emphasis on molars, and surgical management in the newborn is discussed.*

**T**eeth present in the oral cavity at or shortly after birth have been called natal or neonatal, fetal, congenital, predeciduous, and dentition praecox. The preferred terms are natal and neonatal; those teeth present at birth are termed natal and those that erupt within 30 days after birth are called neonatal.<sup>1</sup> Natal teeth are encountered more often than neonatal teeth in an approximate ratio of three to one.<sup>2</sup> Though the prevalence of natal and neonatal teeth reported varies,<sup>3,4</sup> a range of 1 in 2,000-3,500<sup>5</sup> is most widely accepted. A sexual predilection has been suggested with females thought to be affected more often than males.<sup>6</sup>

The majority of natal and neonatal teeth are immature microdonts that are conical and yellow-brown opaque. They contain hypoplastic enamel and dentin, and exhibit minimal root development.<sup>7</sup> Hypermobility is common and causes concern because of the likelihood of swallowing or aspirating the tooth. Sharp incisal edges may cause sublingual ulceration (Riga-Fede disease) which can result in the infant's refusing to nurse. Additionally, the erupted tooth may cause irritation of the nursing mother's nipples.

While the literature is replete with reports of erupted incisors, few reports have been published documenting the presence of erupted posterior teeth in the newborn. The purpose of this report is to present a case of an immature erupted maxillary molar in a newborn and to review the literature pertaining to natal and neonatal teeth with special emphasis on molars.

### Literature Review

A distinction exists in the literature between natal and neonatal teeth. These terms are well-accepted and probably will continue to be used. However, it has been suggested by Spouge<sup>5</sup> that such teeth also should be classified according to their degree of maturity. A mature natal or neonatal tooth is one that has achieved nearly complete development when compared to other primary teeth, while the term immature natal or neonatal tooth implies incomplete or substandard structure.

Several theories have been proposed as to the etiology of the premature eruption of these teeth: increased rate of eruption during or after febrile states, endocrine disturbances, dietary deficiencies, and the effects of congenital syphilis.<sup>1</sup> However, the most universally accepted theory attributes precocious eruption to superficial position of the tooth germ.<sup>7</sup>

Heredity may be an influence in the premature eruption of teeth as Massler and Savara<sup>1</sup> found siblings and parents with the same condition in 10 of 24 reported cases. Additional evidence of genetic contribution is seen in the association of natal or neonatal teeth with multisystem syndromes. These disorders include chondroectodermal dysplasia (Ellis-van Creveld syndrome), oculomandibulodyscephaly (Hallermann-Streiff syndrome) and pachyonychia congenita (Jackson-Lawler syndrome). In cleft lip and palate, a multifactorial genetic disease, a higher incidence of natal and neonatal teeth also has been reported.<sup>8</sup>

Histologically, abnormalities of all tooth structures have been reported. In the dentin, large interglobular spaces with abnormal cell inclusions have been found,<sup>3</sup> as well as an irregular pattern of the orientation of the dentinal tubules.<sup>2</sup> The enamel has been described as hypoplastic or hypomineralized with an absence of Hertwig's sheath.<sup>4</sup> This absence may explain why failure of root and cementum formation has been observed.<sup>2</sup> Other findings include absence of Weil's basal layer and the cell-rich zone in the pulp,<sup>4</sup> and an increase in the number of dilated blood vessels in the pulpal tissue.<sup>2</sup>

The majority of natal and neonatal teeth are true

**Table 1.** Data Summary of Documented Cases of Natal and Neonatal Molars

Author	Natal/ Neonatal	Site		Teeth Number	Teeth Identity	Histological Examination	Radiographs	Associated Findings
		Max.	Mand.					
Bartholin*	--	-	-	2	Molars	No	No	--
Thomas*	Natal	-	-	1	Molar	No	No	8 incisors
Bouchut*	Natal	-	1	1	Molar	No	No	2 mandibular incisors
Jacobi <sup>11</sup>	Neonatal	1	1	2	1st Molars	No	No	--
Kaufman <sup>12</sup>	Natal	4	4	8	1st & 2nd Molars	No	No	Child required resuscitation
M'Lin*	Natal	-	-	2	Molars	No	No	Cyclopien fetus
Oriola <sup>13</sup>	Natal	-	2	2	1st Molars	No	No	Fontanels completely ossified — died day 7
Allwright <sup>6</sup>	Natal	-	2	2	1st Molars	No	No	--
Bodenhoff <sup>9</sup>	Neonatal	-	4	4	1st & 2nd Molars	No	No	2 mandibular incisors
Wong <sup>14</sup>	Natal	-	2	2	1st Molars	No	Yes	4 mandibular incisors 2 maxillary incisors possible family history
Soni <sup>15</sup>	Natal	-	1	1	1st Molar	Yes	No	--
Tay <sup>16</sup>	Neonatal	1	-	1	2nd Molar	Yes	Yes	--
Bernick <sup>17</sup>	Natal	1	-	1	1st Molar	No	No	Congenital scalp defect
Ajagebe <sup>18</sup>	Natal	1	-	1	2nd Molar	No	No	Depressed reflexes, congenital laryngeal stridor, cavernous hemangioma of abdominal wall
Anderson <sup>19</sup>	Natal	2	-	2	1st Molars	Yes	No	2 mandibular incisors
Ronk <sup>20</sup>	Natal	-	-	Multiple	-	No	Yes	Multiple other incisors

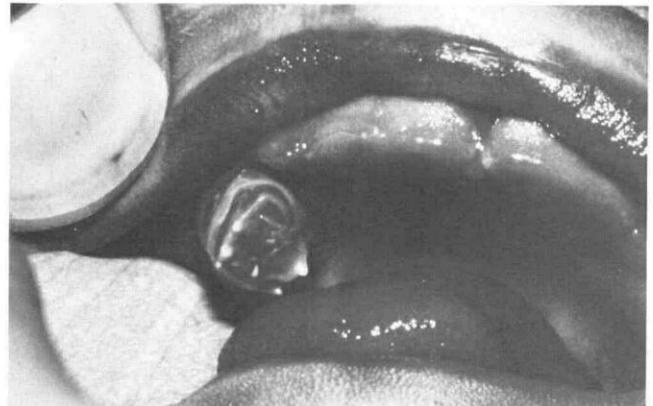\*Ballantyne<sup>10</sup> reported four cases from published reports in his review of congenital teeth.

primary teeth, not supernumeraries. Mandibular incisors are the teeth most often described in the literature with few posterior teeth reported. In fact, according to Bodenhoff,<sup>9</sup> 85% of such teeth are mandibular incisors, 11% are maxillary incisors, 3% are mandibular cuspids and molars, and only 1% are maxillary cuspids and molars. Therefore, the presence of a natal maxillary molar appears to be rare. To date, only 16 cases of natal or neonatal molars have been reported.<sup>9-20</sup> A summary of all known cases of natal and neonatal molars is presented in Table 1.

### Patient Presentation

R.L., a one-day-old black male, was examined in the newborn nursery at the request of his pediatrician. The infant was the product of an uneventful full-term pregnancy who had been delivered spontaneously the previous day. Immediate postpartum APGAR score was 9 and the 5-minute APGAR score was 10. The complete newborn history and physical examination was within normal limits with the exception of a fibroma that the physician noted on the maxillary right alveolar ridge.

Intraoral examination revealed a .5 x .4 x .3 cm firm, nodular, exophytic lesion with a variegated surface attached by a broad base to the maxillary right posterior alveolar ridge. Protruding from the otherwise convex and erythematous surface were what appeared to be multiple abortive mamelons with the color of normal tooth structure (Figures 1 & 2). The location of the lesion on the



**Figure 1.** Maxillary right natal molar.

alveolar ridge approximated the region into which the first primary molar would erupt normally.

After obtaining permission for surgery from the mother, the infant was placed on a circumcision table to maximize operator control. The tissue adjacent to the lesion was infiltrated with 0.3 cc 1% lidocaine and an excisional biopsy performed; no sutures were inserted. The hemostatic mechanism was not considered to be compromised because the infant had received the standard intramuscular dose of 1 mg vitamin K<sub>1</sub> the day of delivery. However, positive pressure with a sterile 2 x 2 gauze failed to control hemorrhage. A microfibrillar collagen hemostat<sup>a</sup> was placed over the surgical site and

<sup>a</sup>Avitene, Avicon, Inc.: Ft. Worth, Tex.

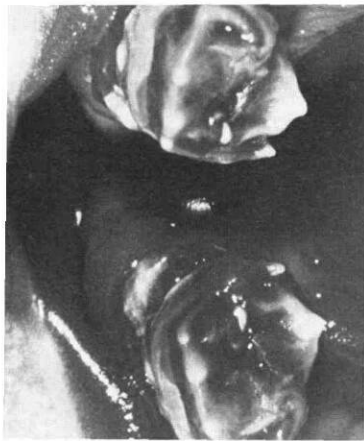

Figure 2. Close-up of natal molar. Note mamelons on the occlusal surface.

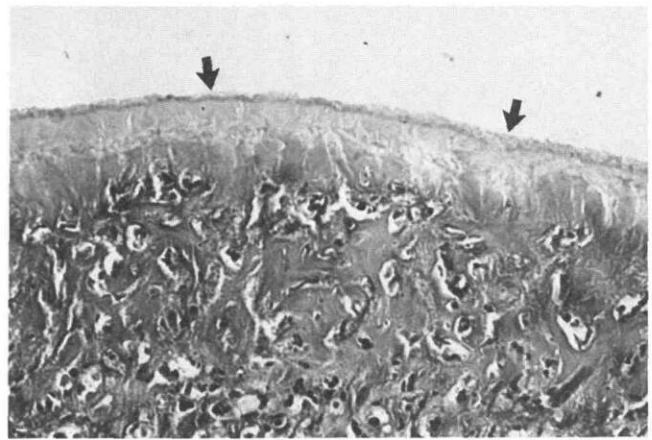


Figure 3. Photomicrograph of immature natal molar. Regular dentin (arrows) is present at the periphery of the specimen and dental tubules are visible (100x).

this in combination with direct pressure achieved adequate hemostasis. The specimen was preserved in 10% formalin and submitted for histological examination. The patient tolerated the procedure well and no subsequent hemorrhage was observed during the postoperative period.

Histopathological examination revealed primitive dental pulp with a layer of regular dentin at the periphery (Figure 3). Adjacent to this dentin was a layer of irregular cellular tertiary dentin containing bizarre distorted odontoblasts with altered polarity. In some areas a basophilic-staining material compatible with remnants of enamel matrix was identified. Two epithelium-lined cysts containing keratinaceous debris were noted in the lamina propria and there was a foreign body giant-cell response to extravasated keratin debris. The histological features were compatible with an immature natal tooth and associated dental lamina cysts.

A follow-up examination at nine months of age revealed that the maxillary and mandibular incisors had erupted into normal arch alignment. The remainder of the extraoral and intraoral examination was within normal limits. An occlusal radiograph revealed that the maxillary right first primary molar was missing (Figure 4); this confirmed the original impression of the identity of the lesion.

## Discussion

As previously mentioned, Spouge suggests classifying natal and neonatal teeth by degree of maturity rather than temporal distinctions. The natal molar reported here would be classified as immature because it contained only primitive and abortive signs of odontogenesis. This information is clinically important since immature natal and neonatal teeth present with a poorer prognosis than mature ones.<sup>5</sup> Hypermobility is a standard feature of immature natal and neonatal teeth and they should be extracted routinely to prevent swallowing or, more importantly, aspiration. The parents must be informed, however, that the extracted tooth may be part of the normal complement of primary teeth. This information can be confirmed radiographically between the ages of six months and one year.

Since facilities that would allow intraoral radiography rarely are available in the nursery, a clinical evaluation usually is relied upon to determine maturity and prog-

nosis. In addition to hypermobility, space loss is of concern in the case of a natal or neonatal molar. While true space loss normally is not encountered after extraction of a natal or neonatal primary incisor,<sup>3</sup> extraction of a natal or neonatal molar certainly will result in loss of arch length. Each case must be evaluated independently and sound clinical judgment must be used to decide whether to retain or extract the tooth in question.

Clinically it was not possible in this case to identify the nature of the lesion. It was speculated that this was an immature natal tooth by virtue of its position and the mamelons apparent on its surface. For this reason and because the identity of the lesion could not be confirmed without histological examination, excision of the lesion was considered the treatment of choice.

Surgical procedures on newborns should not present significant difficulties. These may be performed in the crib or in a separate surgical area such as a circumcision table. Several authors have reported that surgery should be postponed if possible until the tenth postpartum day to

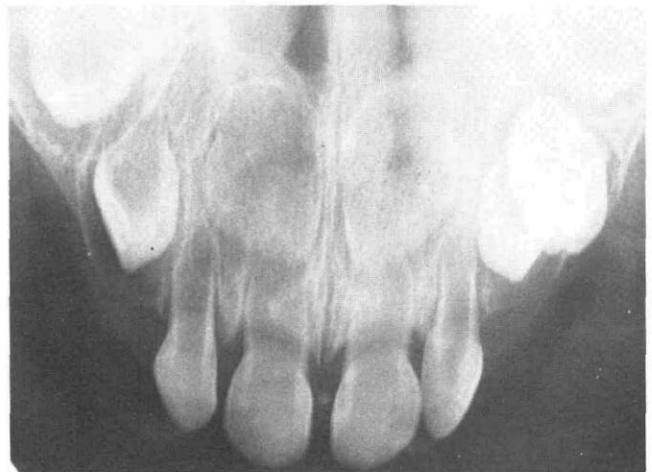

Figure 4. Occlusal radiograph of the patient at age nine months. The maxillary left primary first molar is visible but the right is missing.

avoid excessive hemorrhage.<sup>1,5,21</sup> This may have been necessary in the past, but current nursery protocols for newborns call for the routine prophylactic administration of 1.0 mg of vitamin K immediately after birth. This corrects coagulation defects related to vitamin K deficiency and prevents the usual neonatal decrease in plasma prothrombin levels.<sup>22,23</sup>

Extraction of natal or neonatal teeth or the excision of soft tissue lesions should not cause excessive hemorrhage (due to hypoprothrombinemia) if vitamin K has been administered. Unexpected bleeding was observed in this case immediately postoperatively in spite of vitamin K administration probably because the lesion had a broad base that did not lend itself well to primary closure. Direct pressure and the use of a topical hemostatic agent can be utilized effectively in such instances.

Histological examination of the specimen is compatible with the findings in other natal and neonatal teeth as described by Hals,<sup>4</sup> Spouge,<sup>5</sup> and Gardiner.<sup>3</sup> Only three cases of natal or neonatal molars have been studied histologically. Soni,<sup>15</sup> in a polarized light and microradiographic study, found defective enamel and dentin in occlusal areas and interglobular structures in the dentin of a mandibular primary molar. Dentin, predentin, enamel matrix, and pulpal tissue all were found in a maxillary primary molar reported by Bernick.<sup>17</sup> The cystic cavities found in the natal molar reported here also were identified by Anderson<sup>19</sup> in a histological examination of natal molars in a black female.

## Summary and Conclusions

The terms natal and neonatal most commonly are used to describe teeth that erupt at or shortly after birth; these distinctions are not nearly as important as determining degree of maturity. Most natal and neonatal teeth are immature, have little potential for developing normally, and should be removed. Natal and neonatal primary incisors present few problems if extracted, whereas loss of natal and neonatal primary molars will result in space loss. Such molars, if deemed immature, should be treated in the same manner as incisors. However, mature natal and neonatal molars should be retained if possible to allow complete development and avoid space loss. Orthodontic observation and follow-up care should be included in the treatment plan for patients who present with natal and neonatal teeth.

Delaying surgical procedures on newborns until after the tenth postpartum day no longer is considered necessary because of the prophylactic administration of vitamin K that is standard procedure in most hospitals. If necessary, hemostasis may be enhanced by using topical hemostatic agents in combination with direct pressure.

A case of an immature natal maxillary primary molar is reported. Histological examination of the specimen is in accordance with the findings of other natal and neonatal molars and does not differ significantly from histological reports of other natal and neonatal teeth. Radiographic documentation is presented confirming that this immature tooth-like structure was actually the maxillary right first primary molar.

Dr. Brandt is an assistant professor, Department of Pediatric Dentistry, and Dr. Shapiro is an assistant professor, Division of Clinical Genetics, Department of Pediatric Dentistry, University of Texas Health Science Center at San Antonio, San Antonio, Tex. 78284. Dr. Kittle, a major in the U.S. Army Dental Corps, is chief, Pediatric Dentistry, 766 Medical Detachment, D.S., APO, N.Y. 09304. Requests for reprints should be sent to Dr. Brandt.

1. Massler, M.M., Savara, B.S. Natal and neonatal teeth. *Pediatrics* 36:349-59, 1950.
2. Bodenhoff, J., Gorlin, R.J., Natal and neonatal teeth. *Pediatrics* 32:1087-93, 1963.
3. Gardiner, J.H. Erupted teeth in the newborn. *Proc R Soc Med* 54:504-6, 1961.
4. Hals, E. Natal and neonatal teeth. *Oral Surg* 10:509-21, 1957.
5. Spouge, J.D., Feasby, W.H. Erupted teeth in the newborn. *Oral Surg* 22:198-208, 1966.
6. Allwright, W.C. Natal and neonatal teeth: a study among Chinese in Hong Kong. *Br Dent J* 105:163-72, 1958.
7. Wei, S.H.Y. *Pediatric Dental Care*, American Academy of Pedodontics Monograph. New York: Medcom, 1978.
8. Gorlin, R.J., Pindborg, J.J., Cohen, M.M. *Syndromes of the Head and Neck*. New York: McGraw-Hill, 1976, pp 82, 560, 602.
9. Bodenhoff, J. *Dentitio connatalis et neonatalis*. *Odont Tskr* 67:645-93, 1959.
10. Ballantyne, J.W. Congenital teeth. *Edinburgh Med J* 41:1025-38, 1896.
11. Jacobi, A. *Irregular dentition*. *Dent Cosmos* 24:267-68, 1882.
12. Kaufman, J. An infant born with teeth. *Med Rec* 42:589, 1892.
13. Oriola, J.P. The presence of teeth at birth. *Dent Cosmos* 49:1104, 1907.
14. Wong, H.B. Natal and neonatal teeth in Singapore. *J Singapore Pediatr Soc* 4:74-82, 1962.
15. Soni, N.N., Silberkweit, M., Brown, C.H. Polarized light and microradiographic study of natal teeth. *J Dent Child* 34:433-37, 1967.
16. Tay, W.M. Natal canine and molar in an infant. *Oral Surg* 29:598-602, 1970.
17. Bernick, S.M., Schut, L. *Neonatal maxillary molar in conjunction with a congenital scalp defect*. *J Dent Child* 37:435-37, 1970.
18. Ajagebe, H.A., Daramola, J.O. Natal teeth: a report of five cases. *Nigerian Med J* 4:381-83, 1978.
19. Anderson, R.A. Natal and neonatal teeth: histological investigation of two black females. *J Dent Child* 49:300-3, 1982.
20. Ronk, S.L. Multiple immature teeth in a newborn. *J Pedo* 6:254-60, 1982.
21. Chow, M.H. Natal and neonatal teeth. *JADA* 100:215-16, 1980.
22. Nelson, W.E., Vaughan, V.C., McKay, R.J., Behrman, R.E. *Textbook of Pediatrics*, 11th Ed. Philadelphia: W.B. Saunders Co., 1979, pp 303,395.
23. Holder, T.M., Ashcraft, K.W. *Pediatric Surgery*. Philadelphia: W.B. Saunders Co. 1980, p 67.