

Peripheral calcifying odontogenic cyst in a child: case report of an unusual lesion

Lewis J. Claman, DDS, MS Karen M. Rossie, DDS, MS
Linda E. Records, MA, DDS Gerald Colbert, DDS

Abstract

A peripheral calcifying odontogenic cyst (COC) was observed in a seven-year-old male. The patient presented to his dentist with a bluish soft tissue swelling on the facial aspect of the gingiva overlying the area of an unerupted maxillary left permanent central incisor. Based on the clinical presentation, the lesion was thought to be an eruption cyst; however, histologic examination showed it to be a COC. The COC is a relatively uncommon lesion which may be located peripherally, but more frequently occurs within bone. The patient was followed for 15 months during which time normal tooth eruption occurred and no recurrence of the cyst was apparent.

The calcifying odontogenic cyst (COC) is an uncommon lesion which occurs both peripherally, in the gingiva, and centrally, in alveolar bone (Freedman et al. 1975). Since the COC was defined by Gorlin in 1962, there have been numerous reports of the central COC in the literature, but relatively few of the less common peripheral form. In either location they have a characteristic histologic appearance which includes keratinized "ghost" epithelial cells, odontogenic epithelium which can assume a range of forms from a simple cyst to a solid tumor, and varying amounts of calcified material (Gorlin 1962; Praetorius et al. 1981). This lesion may occur at any age, but is seen most frequently in the second decade.¹ The present case report is of particular interest to the pediatric dentist because the cyst occurred in the first decade of life and resembled an eruption cyst clinically.

Case Report

Clinical Description

A seven-year-old white male presented with a soft tissue lesion on the facial aspect of the gingiva covering an unerupted maxillary left central incisor. The patient had been seen by his dentist at six-month intervals during the

three previous years. The medical history was negative except for infectious mononucleosis and scarlatina at age five years. The patient was seen two months earlier for routine dental restorations. At that time the right central incisor had erupted while the left central incisor was still covered by normal-appearing gingival tissue.

The general dentist described the enlargement as being a smooth, bluish purple, dome-shaped nodule measuring approximately 1 cm in diameter which was confined to the facial aspect of the attached gingiva (Fig 1). The lesion was fluctuant to palpation but not tender,

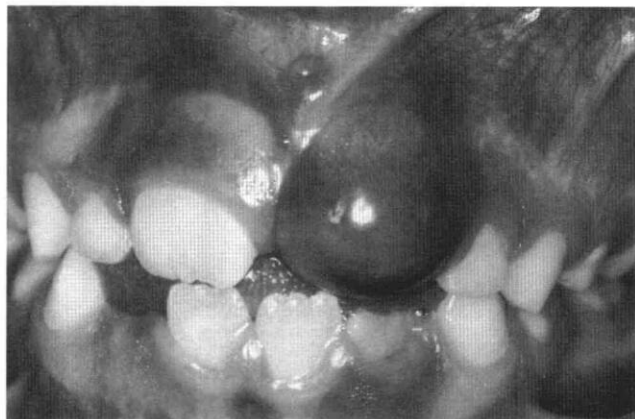


FIG 1. Facial aspect of the anterior segment. The lesion, which completely covered the crown of the maxillary left central incisor, was bluish purple in color, dome shaped, and smooth.

and there was no bony expansion evident. According to the patient's mother, the lesion had been present and slowly enlarging for about two months, but it had turned blue only three days previously. A periapical radiograph revealed no bony abnormalities; however, it showed an apparently normal left permanent central incisor with development and eruption slightly delayed compared to the adjacent right central incisor (Fig 2). All other teeth showed normal formation and eruption. The patient was referred to an oral surgeon for excisional biopsy of the lesion, which was thought to represent an eruption cyst.

¹ Altini and Farman 1975; Nagao et al. 1983; Praetorius et al. 1981.

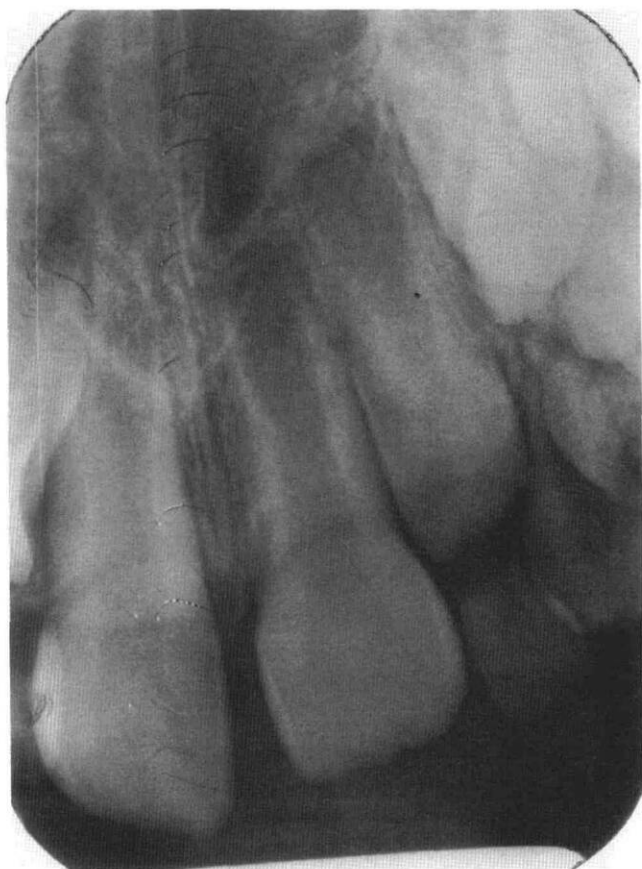

FIG 2. Periapical radiograph of the maxillary central incisors. Formation of the crown and root of the left incisor appears to be normal, although eruption is slightly delayed. Note that the tooth and bone appear uninvolved and no unusual radiopacities are present.

An excisional biopsy resulted in exposure of the clinical crown of the maxillary left central incisor. Only a small area of the lesion was overlying bone, the majority of it covering the tooth. The small amount of bone that was exposed clinically showed no resorptive changes. When the resected tissue was hemisected, a fluid-filled cyst occupying approximately half of the nodule was revealed. The tissue was submitted for histologic evaluation.

Histology

Histologic examination revealed a unilocular cyst

surrounded by a fibrous connective tissue capsule. The lining of the cyst consisted partially of low columnar, hyperchromatic, basal epithelial cells which supported epithelium resembling stellate reticulum and numerous, pale eosinophilic cells with faint nuclear outlines (ghost cells) as shown in Figures 3a and 3b. A few of the ghost cells appeared to be calcified. The remaining portion of the cyst lining consisted of stratified squamous epithelium which also contained ghost cells. Ghost cells surrounded by a granulomatous foreign body reaction also were located in the cyst wall. In multiple histologic sections, the cyst lining did not appear to be continuous with the reduced enamel epithelium of the dental follicle. There was no evidence of any calcified tissue resembling dentin, cementum, or osteoid. Based on the clinical and microscopic findings, a diagnosis of peripheral COC was made.

Clinical Follow-Up

Healing was uneventful, and at three months following surgery, the area was clinically normal with the involved tooth almost fully erupted. The gingiva was healthy and exhibited a normal band of keratinized tissue. The patient was followed for a total of 15 months following removal of the cyst with no evidence of recurrence. At that time the tooth had attained a normal position in the arch and gingival tissues were clinically normal except for marginal gingivitis (Fig 4, next page).

Discussion

A report of peripheral calcifying odontogenic cyst in a seven-year-old male is presented. Few cases of COC, whether peripheral or central, have been reported in patients this young. In a review of the 70 published cases, Freedman et al. (1975) found 4.3% of COCs occurred in the first decade of life and 28.6% of the cases in the second decade. While the peak incidence is in the second decade, it can occur at any age (Freedman et al. 1975; Nagao et al. 1983). In addition, they reported that the majority of COCs in all age groups combined are located anterior to the first permanent molar. The lesion in this case was located in the anterior maxilla, the most frequent location for COC in young patients (Freedman et al. 1975).

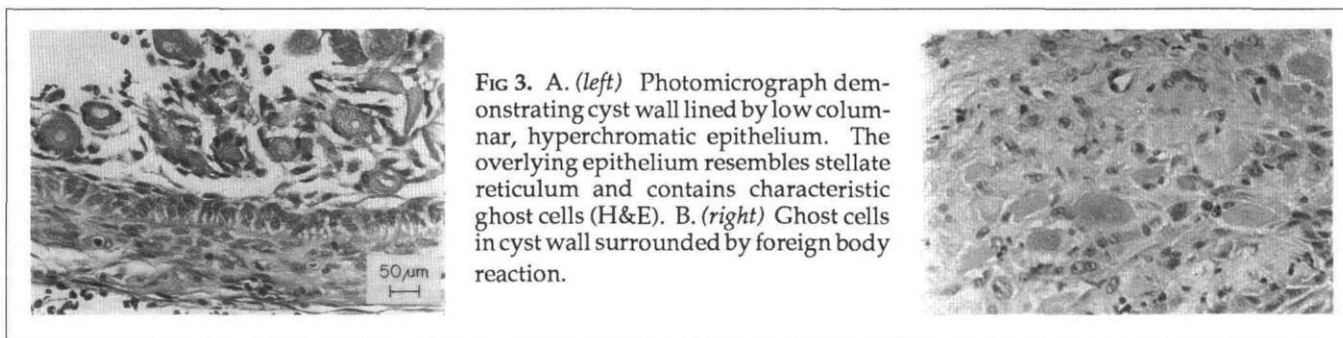


FIG 3. A. (left) Photomicrograph demonstrating cyst wall lined by low columnar, hyperchromatic epithelium. The overlying epithelium resembles stellate reticulum and contains characteristic ghost cells (H&E). B. (right) Ghost cells in cyst wall surrounded by foreign body reaction.

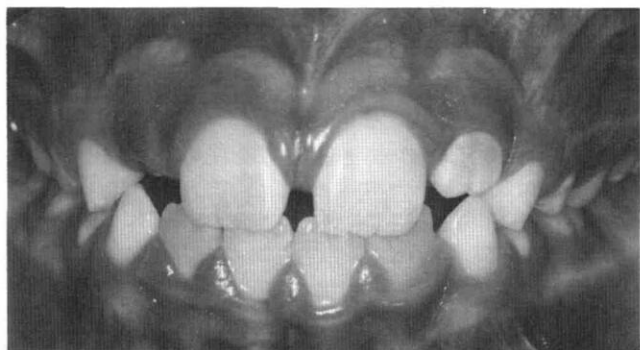


FIG 4. Facial aspect of the anterior segment 15 months following biopsy. Eruption appears to be proceeding normally with no clinical recurrence of the cyst.

A diagnosis of eruption cyst was considered in this patient because of the bluish color, the fluctuant consistency, and the relationship to an erupting tooth. The typical clinical appearance of an eruption cyst is a thin-walled, almost translucent, bluish cyst overlying an unerupted tooth (Shafer et al. 1983). Eruption cysts, which are a type of dentigerous cyst, are formed by the accumulation of fluids within the normal tooth follicle space (Shafer et al. 1983). However, the oral surgeon reported that the cyst was separate from the dental follicle space which made it incompatible with a diagnosis of an eruption cyst. The source of odontogenic epithelium for this peripheral COC may have been the epithelial odontogenic rests normally found in the gingiva, rather than the reduced enamel epithelium lining of the dental follicle. In addition, the two-month duration of this lesion was atypically long for an eruption cyst. They usually resolve as the tooth erupts (Shafer et al. 1983), whereas peripheral COCs typically enlarge slowly over a period of months (Freedman et al. 1975).

Other lesions that can cause gingival swellings include peripheral giant cell granuloma, peripheral ossifying fibroma, pyogenic granuloma, and other less common peripheral odontogenic tumors. However, none of these lesions are cystic, and therefore would not be fluctuant. Blue coloration has been reported in at least one other peripheral COC (Praetorius et al. 1981). Swan et al. (1984), however, reported that most of the lesions are the color of normal gingiva.

The lack of bony involvement in the lesion in this case is consistent with the behavior of peripheral COCs. While central COCs typically cause expansion rather than erosion of bone, peripheral COCs usually do not involve bone or they produce only a saucerization of the underlying bone (Swan et al. 1984).

The histologic findings of the lesion described in this

report are consistent with a diagnosis of peripheral COC. Central or peripheral location of COC does not appear to have any relation to histologic features (Praetorius et al. 1981). The COC has been subdivided into cystic and neoplastic histologic subtypes by Praetorius et al. (1981). They further divided the cystic subtype according to the amount of epithelium, ghost cells, and calcified dental tissues. Those lesions which contain more dentinoid material may show flecks of calcification on the radiograph. The lesion in this case report falls into the cystic subtype 1A, which includes unilocular cysts with moderate mural proliferations of epithelium and little or no dysplastic dentin. The clinical significance of these subtypes is yet to be established.

Treatment for peripheral COCs is conservative surgical excision. The lesions have very little tendency to recur (Swan et al. 1984); however, aggressive behavior of central COCs has been reported (Ellis and Shmookler 1986). The lesion in this report has not recurred during 15-month follow-up.

Dr. Claman is an assistant professor, periodontics, The Ohio State University; Dr. Rossie is an assistant professor, diagnostic services, University of Pittsburgh School of Dental Medicine; Dr. Records is in private general practice and Dr. Colbert is in private oral surgery practice, both in Columbus, Ohio. Reprint requests should be sent to: Dr. Lewis J. Claman, Section of Periodontics, The Ohio State University, College of Dentistry, 305 W. 12th Ave., Columbus, OH 43210.

Altini M, Farman AG: The calcifying odontogenic cyst: eight new cases and a review of the literature. *Oral Surg* 40:751-58, 1975.

Ellis GL, Shmookler BM: Aggressive (malignant?) epithelial odontogenic ghost cell tumor. *Oral Surg* 61:471-78, 1986.

Freedman PD, Lumerman H, Gee G: Calcifying odontogenic cyst: A review and analysis of seventy cases. *Oral Surg* 40:93-106, 1975.

Gorlin RJ: The calcifying odontogenic cyst — a possible analogue of the cutaneous calcifying epithelioma of Malherbe: an analysis of fifteen cases. *Oral Surg* 15:1235-43, 1962.

Nagao T, Nakajima T, Fukushima M, Ishiki T: Calcifying odontogenic cyst: a survey of 23 cases in the Japanese literature. *J Maxillofac Surg* 11:174-79, 1983.

Praetorius F, Hjorting-Hansen E, Gorlin R, Vickers RA: Calcifying odontogenic cyst: range, variations, and neoplastic potential. *Acta Odontol Scand* 39:227-40, 1981.

Shafer WG, Hine MK, Levy BM: *A Textbook of Oral Pathology*, 4th ed. Philadelphia; WB Saunders Co, 1983 p 261.

Smith RM, Turner JE, Robbins ML: *Atlas of Oral Pathology*. St. Louis; CV Mosby Co, 1981 p 74.

Swan RH, Houston GD, Moore SP: Peripheral calcifying odontogenic cyst (Gorlin cyst). *J Periodontol* 56:340-43, 1984.