



Lingual Epidermoid Cyst: Case Report in an Infant

Maria Saete Nahás Pires Corrêa, DDS, PhD Ricardo De Nardi Fonoff, DDS, MS, PhD
Henrique Castilhos Ruschel, DDS, MS Symonne Pimentel Castro de Oliveira Lima Parizotto, DDS, MS
Fernanda Nahás Pires Corrêa, DDS

*Dr. Maria Corrêa is professor, Department of Orthodontics and Pediatric Dentistry, School of Dentistry, University of São Paulo; Dr. Fonoff is professor, Department of Pediatric Dentistry, School of Dentistry, Paulista University (UNIP), Sorocaba, Brazil; Dr. Ruschel is professor, Department of Pediatric Dentistry, School of Dentistry, Lutheran University of Brazil (ULBRA), Canoas, Brazil; Dr. Parizotto is professor, Department of Pediatric Dentistry, School of Dentistry, University for the Development of the State of Mato Grosso do Sul and the Pantanal Region (UNIDERP), Campo Grande, Brazil. Dr. Fernanda Corrêa is intern, Department of Orthodontics and Pediatric Dentistry, School of Dentistry, University of São Paulo, São Paulo, Brazil.
Correspond with Dr. Ruschel at henrirus@zaz.com.br*

Abstract

The purpose of this article was to present a rare case of epidermoid cyst on the ventral region of the tongue in a 15-month-old child. During clinical examination, a sessile, yellowish lesion measuring approximately 0.5 cm was noticed. The lesion had existed since the child's birth and was causing discomfort due to friction of the tongue against the alveolar ridge during mastication. The chosen treatment was total removal of the lesion. The histopathological findings confirm the diagnosis of an epidermoid cyst, characterized by the presence of: (1) a cyst cavity lined by stratified squamous epithelium with keratinization on the surface; and (2) connective tissue with a mild inflammation. The proposed treatment was considered successful as the case was solved and there was no recurrence. (*Pediatr Dent.* 2003;25:591-593)

KEYWORDS: LINGUAL EPIDERMOID CYST

Received December 16, 2002 Revision Accepted April 25, 2003

Epidermoid and dermoid cysts are nonodontogenic cyst lesions.¹ They are rare lesions derived from germinal epithelium. While a dermoid cyst has an epidermal lining with skin adnexa such as hair follicles and sebaceous and sudoriparous glands, the epidermoid cyst contains no such adnexa. These cysts are usually sole lesions.²⁻⁵

It is suggested that these cysts are derived from epithelial remains from the closure process of the first and second branchial arches.⁴ Particularly in the tongue region, these lesions may be formed by remains of the tuberculum impar, which, together with the lateral lingual prominences, form the body of the tongue and floor of the mouth.⁶

In the oral cavity, these cysts occur most frequently in the area of the floor of the mouth and may also occur on the tongue, lips or the interior of the bone.^{4,7,8-12} Reports of cases in the lingual area are very uncommon.^{13,14} The majority of cases in this area or combined with cysts in the sublingual area are diagnosed early, generally in the first few months of life. On the other hand, the isolated form in the sublingual area is usually diagnosed during the second decade of life.^{3,5,13}

Clinically, these lesions are characterized by the slow growth of a normal- or yellow-reddish-colored painless

swelling with soft consistency on palpation. The diameter can vary from a few millimeters to even 10 centimeters. The clinical diagnosis should be confirmed with the histological examination.¹

In making a differential diagnosis, the clinician should consider a broad variety of conditions that include ranula, mucocele, lymphangioma, lymphoepithelial cyst and thyroglossal duct cyst.^{1,7}

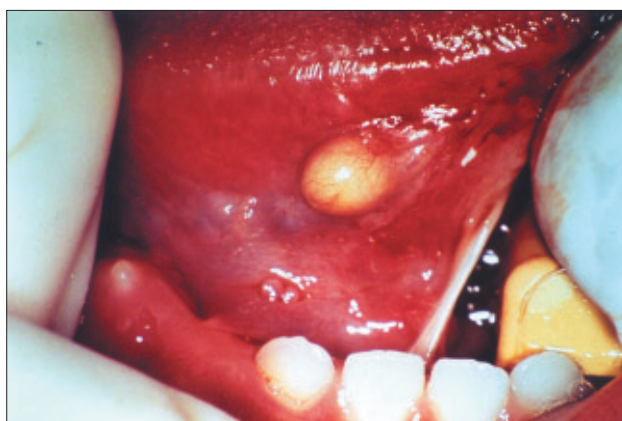

Figure 1. Clinical aspect of the lesion.

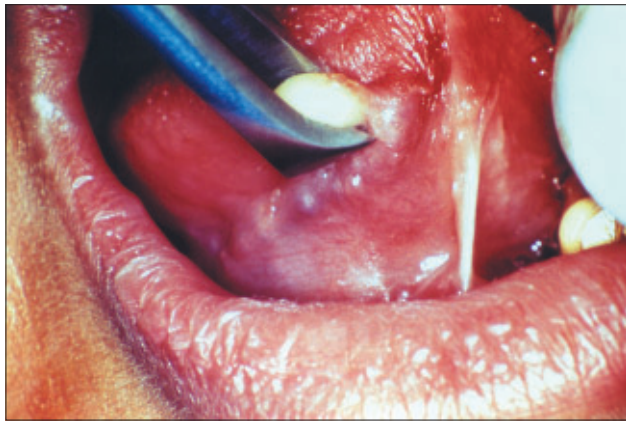


Figure 2. Nipping the lesion during the surgery.

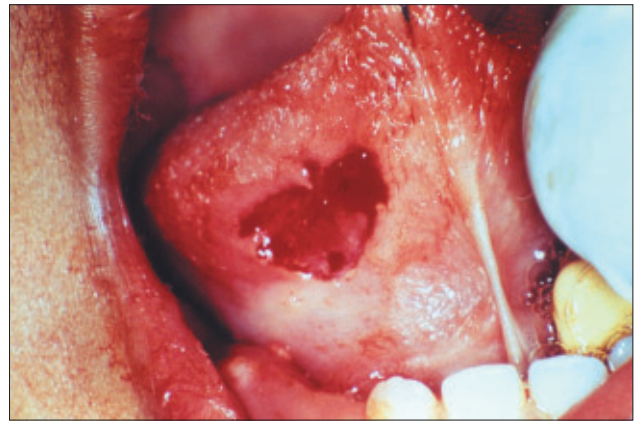


Figure 3. Aspect of the ventral region of the tongue after the removal of the cyst.

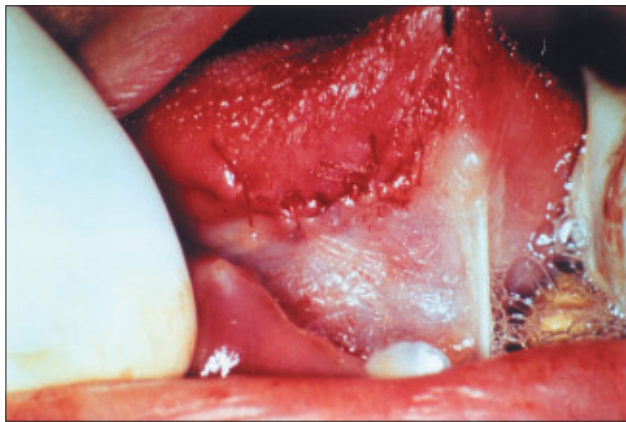

Figure 4. Suture of the region.

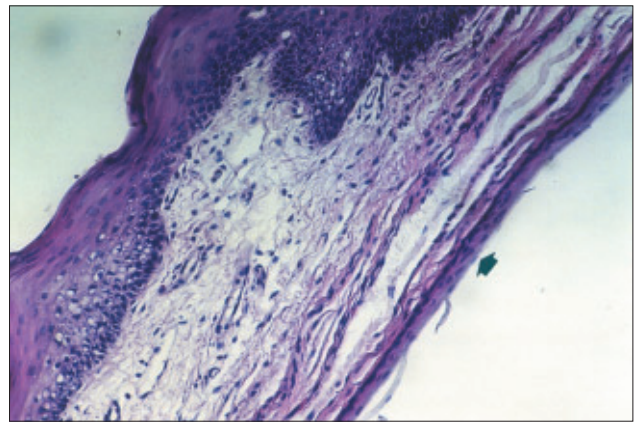


Figure 5. Photomicrograph showing the cystic cavity covered by stratified squamous epithelium (arrow) supported by a connective loose tissue. The epithelium of the oral mucosa that was removed with the cyst during surgery can also be observed (HE; $\times 200$).

Epidermoid cysts are rare lesions in young children. They occur mainly in young adults and are not sex linked.⁷ This article describes a rare case of an epidermoid cyst on the ventral region of the tongue of a 15-month-old child.

Case report

The patient was a 15-month-old black male weighing 2,900g at birth. The child was delivered by C-section at 39 weeks of pregnancy. The child's medical history reported only the occurrence of broncho-pneumonia in the first month of life. He was brought by his guardian to the Pediatric Dentistry Clinic at University of São Paulo (São Paulo, Brazil). The reason for the appointment was the presence of a sessile and yellowish lesion, located on the left side of the ventral part of the tongue, measuring approximately 0.5 cm (Figure 1).

The patient's mother stated that the child had presented this lesion since birth and recently there was a discomfort caused when the alveolar ridge touched the lesion during mastication. It was noticed that the first inferior primary molar was erupting at the respective alveolar area.

A preliminary diagnosis of mucocele, epidermoid cyst, dermoid cyst, or lymphoepithelial cyst was proposed. The treatment consisted of total surgical removal of the lesion by local anesthesia in the Pediatric Dentistry Clinic. A 2%

Lidocaine anesthetic solution with adrenaline was infiltrated around the lesion. Next, the nipping of the lesion and an elliptical incision on its bottom were performed (Figures 2-4).

The macroscopic biopsy of the lesion consisted of a fragment of soft, round tissue with a rubbery surface and consistency, measuring 8×5×5 mm, which was cut in half and sent to be processed in the laboratory.

Histopathological examination confirmed the diagnosis of an epidermoid cyst by the presence of 3 to 4 layers of stratified squamous epithelial tissue covering the cyst cavity, with laminas of parakeratin on the surface and supporting connective tissue showing no epithelial adnexa. Oral mucosa epithelium was noticed on the surface of the section (Figure 5).

The patient was followed-up during the next 6 months, and no recurrence of the lesion was observed.

Discussion

Epidermoid cysts are rare lesions of questionable etiology.⁴ These lesions occur rarely in infants and are more common in young adults.⁷ The clinical case related in this article presented an isolated cyst on the ventral region of the tongue in an infant.

At first, analyzing only the clinical aspects, the suggested differential diagnosis was mucocele or lymphoepithelial cyst. The mucocele is a common oral lesion caused by trauma and disruption of the minor salivary glands. However, considering the history of the lesion and that it was presented since birth and without trauma report, the mucocele hypothesis was excluded. The lymphoepithelial cyst is due to a cystic degeneration of the mucosa or glandular surface of the epithelium. Lymphoepithelial cysts are rare lesions that usually appear after 40 years of age on the posterior lateral or ventral part of the tongue or palatum molle. Hence, it is not related to an early age. The differential diagnosis excluded the lesions ranula, lymphangioma, and thyroglossal duct cyst because their occurrence on the ventral region of the tongue is not related in the literature.¹

The diagnosis of an epidermoid cyst was initially considered and later confirmed through histopathological examination of the surgical fragment. The cyst's aspect determines the histological classification, characterized by stratified squamous epithelium with laminae of keratinization on the surface and lumen of the cyst cavity. The lack of epithelial adnexa excludes the diagnosis of dermoid cyst.

An untreated epidermoid cyst can achieve large proportions, causing discomfort during mastication, swallowing, and speaking.^{4,5,7}

The proposed treatment was the surgical removal of the lesion.^{1,4,5,7} The cyst removal procedure was simple and effective and its success was confirmed by the lack of postsurgical alterations and no recurrence of the lesion.

Acknowledgements

The authors would like to thank Márcia Rodrigues Gorisch, DDS, MS, professor, Department of Oral Pathology, School of Dentistry, University for the Development of the State of Mato Grosso do Sul and the Pantanal Region—UNIDERP—Campo Grande, Brazil, for help with this research.

References

1. Laskaris G. Atlas colorido de doenças bucais na infância e da adolescência. 1st ed. Porto Alegre/São Paulo. Artes Médicas Sul/Livraria Santos Editora. 2000;1-338.
2. Brown CA, Barker RD. Dermoid cyst: Report of case. *J Oral Surg.* 1972;30:55.
3. Rajayogeswaran V, Everson JW. Epidermoid cyst of buccal mucosa. *Oral Surg Oral Med Oral Pathol.* 1989;67:181.
4. Worley CM, Laskin DM. Coincidental sublingual and submental epidermoid cysts. *J Oral Maxillofac Surg.* 1993;51:787-790.
5. Calderon S, Kaplan I. Concomitant sublingual and submental epidermoid cysts: A case report. *J Oral Maxillofac Surg.* 1993;51:790-792.
6. Meyer I. Dermoid cyst (dermoids) of the floor of the mouth. *Oral Surg Oral Med Oral Pathol.* 1955;8:1149.
7. Walstad WR, Solomon JM, Schow SR, Ochs MW. Midline cystic lesion of the floor of the mouth. *J Oral Maxillofac Surg.* 1998;56:70-74.
8. Saez-de-Ocariz MM, Dominguez-Cherit J, Garcia-Corona C. Subungual epidermoid cysts. *Int J Dermatol.* 2001;40:524-526.
9. Rapidis AD, Angelopoulos AP, Scouteris C. Dermoid cyst of the floor of the mouth: Report of a case. *Br J Oral Surg.* 1981;19:43.
10. Mathur SK, Menon PR. Dermoid cyst of the tongue. Report of a case. *Oral Surg Oral Med Oral Pathol.* 1980;50:217.
11. Rule DC. Dermoid cyst of the lower lip: A case report. *Br J Oral Surg.* 1976;12:116.
12. Craig GT, Holland CS, Hindle MO. Dermoid cyst of the mandible. *Br J Oral Surg.* 1980;18:230.
13. Valtoneu H, Nuutinen J, Krja T et al. Congenital dermoid cysts of the tongue. *J Laryngol Otol.* 1986;100:965.
14. Floom GS. Congenital dermoid cyst of the anterior tongue. *Otolaryngol Head Neck Surg.* 1989;101:88.