

Primary identification of an abused child in a dental office: a case report

Theodore P. Croll, DDS
Vincent J. Menna, MD
Cheryl A. Evans, BSW

Abstract

Dental practitioners are able to identify physical evidence of injuries to children, especially in the regions of the head and neck and oro-facial structures. When such injuries are of suspicious origin, the dentist has an obligation to document and report his/her findings to appropriate authorities so that proper action may be taken to protect the child while the problem is investigated and resolved. A case is presented in which a male child was first identified as a child abuse victim at a routine dental office visit.

Introduction

Physical abuse of children has been the subject of much dental and medical literature in recent years.¹⁻⁴⁵ This complex problem raises medical, legal, moral, cultural, and psychological issues, all of which must be addressed by the health professional responsible for the medical welfare of the child. Dental practitioners are in a unique position to identify and report suspicious findings which may give evidence of physical abuse of children.^{1,4,7,13-17,35} Many cases of battered child syndrome⁴ involve injury to the oro-facial structures or head and neck region in general.¹⁵ Comprehensive oral and head and neck examination as performed by dentists can document physical evidence of nonaccidental injuries.

Abuse of children is not limited to battering. Reports of sexual abuse,^{9,10,23,26,40} poisoning,^{33,37} intentional burning,^{30,39} and other forms^{22,25} of child abuse portray the extent and diversity of the problem.

The effects of child abuse are not ephemeral. Numerous reports in the literature document severe physical injuries and medical problems associated with child abuse. Ophthalmological damage is cited,^{21,27,46} along with skeletal and orthopedic injuries,^{29,34} and irreversible injury to internal organs.³¹ Cerebral injury from physical abuse can result in mental retardation,²⁰ and intentional burning of children results in scarring that provides visible evidence of abuse for the victim's lifetime.^{30,39} Death may also result from child abuse if

appropriate intervention is not timely.

Long term sequela of abuse is not limited to bodily injury. Psychopathological disturbances are extremely common in children who are continually battered, sexually molested, and subjected to emotional abuse.^{19,20,28,32,38}

Becker et al. in 1978 reported that in a five-year period at Children's Hospital Medical Center in Boston, 65 percent of 260 documented cases of child abuse involved oro-facial and/or head trauma.¹⁵ They also noted that a majority of dentists who answered a survey were not aware of the legal obligations of a health practitioner to report cases with suspicious findings. Such obligations, and legal implications of a health practitioner not reporting suspected child abuse, have been reviewed in recent literature.^{6,24,35}

Dentists are apparently reluctant to report suspected cases of child abuse for several reasons,^{11,12,15} including ignorance of the magnitude of the child abuse problem, lack of knowledge about reporting abuse, inadequate histories in patient files, imagined potential effects upon a private practice as a result of reporting a case of abuse, and fear of confronting parents. Positive identification of child abuse victims may sometimes be difficult, causing practitioners to avoid involvement in suspicious but uncertain cases. In addition, there are reports of conditions which perfectly mimic physical abuse, but prove to result from other causes.^{36,42}

Becker et al. cited the scarcity of literature by dentists reporting personal experiences with cases of child abuse.¹⁵ It is the purpose of this paper to describe the entire course of events of a case, commencing with identification of a young abuse victim who was brought to a private pedodontic office for routine restorative dental care.

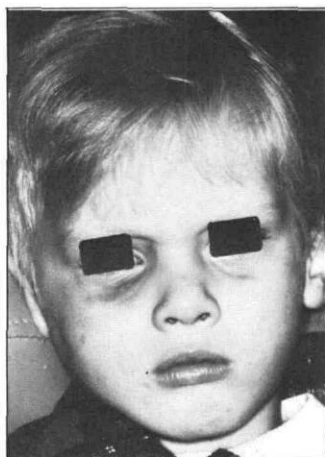
Case Report

A 34-month-old Caucasian male, R. T., was brought to a private pedodontic office in Pennsylvania in November of 1979 for a scheduled appointment for

amalgam restorations. He had been examined six weeks earlier at the same office, and all oro-facial and head and neck findings were nonremarkable with the exception of Class I carious lesions of several primary second molars. The patient lived with his maternal grandparents and biological mother, and the whereabouts of his father was unknown. The medical history included a hospital stay in the spring of 1979 for severe lacerations of the left foot associated with a power mower accident. The boy's grandfather reportedly struck the patient while mowing the lawn.

While seated in the children's play area during the November office visit, the patient was seen to have bilateral periorbital ecchymosis, with the right side more severely affected than the left (Figure 1). On

Figure 1. The patient exhibited bilateral periorbital ecchymosis.

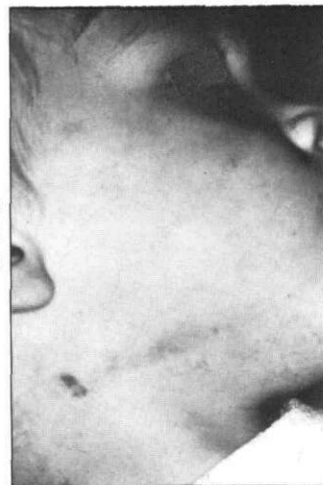

questioning the mother and grandmother, who had accompanied the patient, the mother said that the patient was bruised "when he fell at the playground," while simultaneously the grandmother claimed, "he plays with crayons and rubs them in his eyes."

The patient was taken to a private isolated dental operatory while the grandmother and mother remained in the reception area. Using the method of Croll et al. the patient was evaluated and found to be free of obvious neurological impairment.⁴⁷ His Glasgow Coma Score^{47,48} was 15 and he freely responded to all commands although he displayed moderate situational anxiety.

On physical examination, the boy was found to have multiple areas of ecchymosis including the skin surface of the angle and inferior border of the right side of the mandible (Figure 2), the right cervical region (Figure 2), the periorbital areas (Figures 1,2), within the concha of the right ear (Figure 3), and a large ecchymotic lesion about 15 cm in diameter on the right side of the chest, superior and lateral to the sternum (Figure 2). The only other noteworthy physical finding was extensive scarring of the left foot associated with the lawn mower injury. The genitalia and buttocks were not examined. All visible evidence of

Figure 2. Ecchymosis of the skin surface of the angle and inferior border of the right side of the mandible.



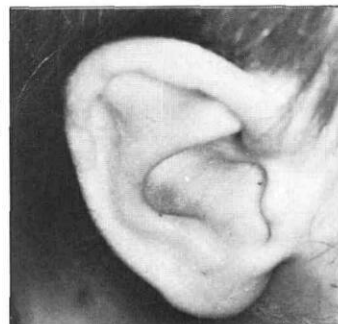
physical injury was photographed using 35 mm color slide film (Figures 1-3).

The patient was asked about the injuries, including the question "Who hit you?" His only response to any verbal communication about his bruises from that time on was an emphatic "No!"

It was felt that the child should be evaluated by a physician to assure the boy's medical status. A pediatrician on emergency call at the local hospital was contacted by telephone after it was discovered that the family physician was not available (the family physician's name and telephone number is recorded on the patient's office folder, so the mother did not have to be consulted). The pediatrician requested that the patient be brought to the emergency division of the hospital as soon as possible.

Since the child was cooperative and in no distress, a single dental restoration was performed. The patient was then returned to the reception area by the pedodontist. The dentist questioned the mother as to the frequency and ease with which the patient developed bruises while at play. When she related that the boy bruised very easily, the dentist explained that certain disorders such as hemophilia and leukemia may be responsible for such bleeding, and for safety's sake an examination by a physician would be prudent. The mother responded "I didn't hit him, I would never hit him!" After she was reassured that the medical evaluation was to verify that the patient was not seriously ill or injured, she accepted the suggestion of medical consultation. Both the pedodontist and two

Figure 3. Area of ecchymosis within the concha of the right ear.



office staff members observed that the mother became eager to leave for the hospital and seemingly grateful for the idea. The pedodontist planned to call Child Line, a toll free child abuse hotline in Pennsylvania, had the pediatrician not confirmed the hospital arrival within 30 minutes.

The patient was immediately taken to the emergency department and upon medical evaluation was admitted to the hospital. The local county youth social services agency was contacted by the pediatrician, and by that evening legal proceedings were initiated to place the patient in protective custody of the county. Within several days the social worker assigned to the case requested the pedodontist's color slides for use in legal proceedings. The photographs, along with the pediatrician's photographs and recorded findings, were instrumental in convincing judicial authorities to place the child in a foster home while the family situation was investigated.

The pedodontist and pediatrician were subpoenaed to testify at a hearing several weeks later, but were never called into the discussions.

According to the social worker, ten months after identification of the problem the patient had been returned to his home. He had stayed with several sets of foster parents during the time that he and his family had undergone psychological counseling. It was discovered that all of the three adults probably had been involved in physically abusing the boy in varying degrees. To the satisfaction of the psychologists and social workers, however, circumstances had improved sufficiently for the boy to return home with assurance of safety. Periodic monitoring of the patient by the youth agency will continue for an indefinite time period.

A letter was written to the mother advising her that she would be welcome to return the patient for continuing dental care. The social worker also encouraged the mother to seek continuing dental care for the boy. Fifteen months after the letter was sent, the mother had not arranged for further appointments with the pedodontist, and it is not known if the child has been treated elsewhere.

Discussion

R. T.'s case history is interesting in several respects. Rapid communication among the pediatric dentist, the pediatrician, and the children's social service agency resulted in immediate identification of an abused child and in prompt action. If medical consultation had not been feasible, or if the boy's mother had refused to see the physician, the pedodontist would have phoned Child Line in Pennsylvania. The Child Line telephone service takes information from the caller and contacts local authorities to act in a case of suspected child abuse. According to the Penn-

sylvania Child Line service (1-800-932-0313), a similar telephone line is available in most of the United States.

The role of the color slide photographs in this case cannot be overstated. Evidence of physical abuse provided by the pictures was vivid and complete, and legal and judicial authorities had no doubts as to the nature and extent of injuries described in the medical report. The senior author believes that a versatile intra-oral and extra-oral photographic system is essential in a dental office not only for routine documentation of certain dental cases, but also for documentation of unusual findings such as child abuse.

Due to human nature and the personal feelings which surface upon identification of a child abuse victim, it is not surprising that a patient may not be returned to the health practitioner who reported the case. R. T.'s return to the pedodontic practice has not been ruled out however. The letter to the patient's mother provided an invitation for her to re-establish contact with the office in the future, hopefully without feelings of embarrassment.

Conclusion

It is apparent from this case history that active communication among health professionals and a youth social service agency can be most beneficial in initiating action to investigate and resolve a child abuse case. A dentist can play a primary role in detecting evidence of child abuse, documenting such evidence, and reporting all findings to appropriate medical and social service personnel.

Dr. Croll is in private practice, Doylestown, Pennsylvania, clinical assistant professor, department of orthodontics/pedodontics, University of Pennsylvania School of Dental Medicine, and staff pedodontist, Children's Hospital of Philadelphia. Dr. Menna is in private practice in Doylestown also, and on the associate staff, St. Christopher's Hospital for Children, Philadelphia, Pennsylvania. Ms. Evans is a social worker, Bucks County Child and Youth Social Service Agency, Bucks County, Pennsylvania. Requests for reprints should be sent to Dr. Croll, East Street Center, East Street and N. Main Street, Doylestown, Pennsylvania 18901.

References

1. Kershon, H. et al. Child abuse and the dentist, *Ont Dent*, 54:11-2, 1972.
2. Jackson, A. D. Non-accidental injuries to children, *Pro Br Paedod Soc*, 6:11-3, 1976.
3. Schwartz, S. et al. The role of the dentist in child abuse, *Quintessence Int*, 7:79-81, 1976.
4. Sopher, I. M. The dentist and the battered child, *Dent Clin North Am*, 21:113-22, 1977.
5. Baetz, K. et al. Recognition and management of the battered child syndrome, *J Dent Assoc S Afr*, 32:13-8, 1977.
6. ten Bensel, R. W. et al. Neglect and abuse of children: historical aspects, identification, and management, *J Dent Child*, 42:348-58, 1975.

7. Teuscher, G. W. Editorial: the battered child: a social enigma, *J Dent Child*, 41:335-6, 1974.
8. Pascoe, J. M. Patterns of skin injury in nonaccidental and accidental injury, *Pediatrics*, 64:245-7, 1979.
9. Tidelli, J. A. et al. Sexual abuse of children: clinical findings and implications for management, *N Engl J Med*, 302:319-23, 1980.
10. Walters, D. R. *Physical and Sexual Abuse of Children*: Bloomington and London, Indiana U. Press, 1975.
11. Silver, L. B. et al. Child abuse syndrome: the "gray areas" in establishing a diagnosis, *Pediatrics*, 44:594, 1969.
12. Sanders, R. W. Resistance to dealing with parents of battered children, *Pediatrics*, 50:853, 1972.
13. Journal of the American Dental Association. Dentists Should be Alert for Child Abuse Evidence. 99:116-7, 1979.
14. Smith, J. et al. The dentist's role in combating child abuse, *Va Dent J*, 55:18-21, 1978.
15. Becker, D. B. et al. Child abuse and dentistry: Orofacial trauma and its recognition by dentists, *JADA*, 97:24-8, 1978.
16. Scholle, R. H. Sobs in silence? (Editorial), *JADA*, 97:153-4, 1978.
17. Laskin, D. M. The recognition of child abuse, *J Oral Surg*, 36:349, 1978.
18. Benusis, K. Child abuse: what the dentist should know, *Northwest Dent*, 56:260-3, 1977.
19. Green, A. H. Self-destructive behavior in battered children, *Am J Psychiatry*, 135:579-82, 1978.
20. Buchanan, A. et al. Abuse and neglect as a cause of mental retardation: a study of 140 children admitted to subnormality hospitals in Wiltshire, *Brit J Psychiatry*, 131:458-67, 1977.
21. Bacon, C. J., et al. Extensive retinal hemorrhages in infancy . . . an innocent cause, *Brit Med J*, 1:281, 1978.
22. Baer, A. M. Covert forms of child abuse: a preliminary study, *Child Psychiatry Hum Dev*, 8:115-28, 1977.
23. Gentry, C. E. Incestuous abuse of children: the need for an objective view, *Child Welfare*, 57:355-64, 1978.
24. Malecz, R. E. Child abuse, its relationship to pedodontics: a survey, *J Dent Child*, 46:193-4, 1979.
25. Roberts, I. F., et al. Malnutrition in infants receiving cult diets: a form of child abuse, *Brit Med J*, 1:296-8, 1979.
26. Schultz, L. G. The sexual abuse of children and minors: a bibliography, *Child Welfare*, 58:147-63, 1979.
27. Eisenberg, A. B. Retinal hemorrhage in the battered child, *Childs Brain*, 5:40-4, 1979.
28. Solomons, G. Child abuse and developmental disabilities, *Dev Med Child Neurol*, 21:101-5, 1979.
29. Dickson, R. A., et al. Spinal injuries in child abuse: case report, *Trauma*, 18:811-2, 1978.
30. Ayoub, C., et al. Burns as a manifestation of child abuse and neglect, *Am J Dis Child*, 133:910-4, 1979.
31. Halsted, C. C., et al. Child abuse: acute renal failure from ruptured bladder, *Am J Dis Child*, 132:1045, 1978.
32. Lewis, D. O., et al. Perinatal difficulties, head and face trauma, and child abuse in the medical histories of seriously delinquent children, *Am J Psychiatry*, 136:419-23, 1979.
33. Watson, J. B., et al. Nonaccidental poisoning in childhood, *Arch Dis Child*, 54:143-4, 1979.
34. MacFarlane, I. J. Hip problems in a battered child: a case report, *Aust NZ J Surg*, 49:107-8, 1979.
35. Davis, G. R., et al. The dentist's role in child abuse and neglect. Issues, identification, and management, *J Dent Child*, 46:185-92, 1979.
36. Primosch, R. E. and Young, S. K. Pseudobattering of Vietnamese children (*cao gio*), *JADA*, 101:47-8, 1980.
37. Hvizdala, E. V., et al. Intentional poisoning of two siblings by prescription drugs: an unusual form of child abuse, *Clin Pediatr (Phila.)*, 17:480-2, 1978.
38. Green, A. H. Psychopathology of abused children, *J Am Acad Child Psychiatry*, 17:92-103, 1978.
39. Lenoski, E. F., et al. Specific patterns of inflicted burn injuries, *J Trauma*, 17:841-6, 1977.
40. James J., et al. Physician reporting of sexual abuse of children, *JAMA*, 240:1145-6, 1978.
41. Wilson, E. F. Estimation of the age of cutaneous contusions in child abuse, *Pediatrics*, 60:750-2, 1977.
42. Carpentieri, U., et al. Misdiagnosis of neglect in a child with bleeding disorder and cystic fibrosis, *South Med J*, 71:854-5, 1978.
43. Leake, H. C. 3rd, et al. Preparing for and testifying in a child abuse hearing. Much of the anxiety associated with court hearings on child abuse can be lessened if the physician is properly prepared and understands what the court is expecting, *Clin Pediatr (Phila.)*, 16:1057-63, 1977.
44. Cameron, J. M., et al. The battered child syndrome, *Med Sci Law*, 6:2, 1966.
45. O'Neill, J. et al. Patterns of injury in the battered child syndrome, *Trauma*, 13:332, 1973.
46. Diamond, G. Personal Communication. August, 1980.
47. Croll, T. P., et al. Rapid Neurologic assessment and initial management for the patient with traumatic dental injuries, *JADA*, 100:530-4, 1980.
48. Teasdale, G., Jennett, B. Assessment of coma and impaired consciousness. A practical scale, *Lancet*, 2:81-4, 1974.

Information for Authors

All manuscripts must be accompanied by the following written statement, signed by one author: "The undersigned author transfers all copyright ownership of the manuscript entitled (name of the article) to the American Academy of Pedodontics should the work be published. The undersigned author warrants that the article is original, is not under consideration by another journal, and has not previously been published. I sign for and accept responsibility for releasing this material on behalf of any and all co-authors." Authors will be consulted, when possible, regarding republication of their material.