



Oral findings in asymptomatic (P-1) and symptomatic (P-2) HIV-infected children

Agnes Del Toro, DDS Robert Berkowitz, DDS Cyril Meyerowitz, DDS, MS Lisa M. Frenkel, MD

HIV infection has significant and well-described oral manifestations in adults.¹ By comparison, information regarding oral findings in pediatric HIV infection is limited.²⁻⁶ The association between risk for oral complications and HIV disease progression has not been clearly demonstrated in pediatric HIV infection.²⁻⁶ To address this issue, we assessed the relationship between HIV-related oral findings and HIV disease progression in perinatally HIV-infected children.

Methods

Patient population

The patient population consisted of 28 HIV-infected children who presented to Strong Memorial Hospital (SMH) in Rochester, New York, between April 1993 and December 1994. All were patients of the Pediatric HIV Clinic at SMH. Infectivity was defined as positive ELISA (HIV) confirmed by Western Blot for patients 15 months or older and positive HIV culture or polymerase chain reaction for patients younger than 15 months of age. The patient population comprised 13 females and 15 males ranging in age from 2 months to 13.5 years. All of the patients acquired HIV via maternal transmission and were taking antiretroviral drugs at the time of oral examination. CDC classification of the patient population indicated that 10 patients were P-1 and 18 patients P-2.

Oral examinations

Comprehensive medical management of the patient cohort included an oral examination at least once every 6 months. On this basis, IRB approval was not required. Oral ex-

aminations consisted of palpation and inspection of the mouth and facial structures with appropriate lighting and tongue blade retraction in a medical examination room. Each oral examination was performed by two of the authors. There were no interexaminer disagreements. Twenty of the patients received two or more oral examinations during the study period; eight patients were examined only once. The prevalence and type of HIV-related oral findings were determined for the study population.

Findings

Findings are summarized in the Table. Eleven of the 28 patients (39.3%) had an oral finding associated with HIV infection. None of these 11 patients had more than one oral finding. Distribution of oral findings relative to CDC classification indicated that 10% (1/10) of the P-1 patients and 56% (10/18) of the P-2 patients had an oral finding (Fisher's exact test: $P = 0.04$).

The most common oral finding, pseudomembranous candidiasis (PC), was found in five P-2 patients. A diagnosis of PC was based on the presence of creamy white or yellowish plaques overlying an erythematous mucosal surface coupled with a positive clinical response to antifungal therapy.⁷

TABLE. ORAL FINDINGS RELATIVE TO CDC CLASSIFICATION

Types of oral findings	Frequency of oral findings relative to CDC classification		
	P-1 (N=10)	P-2 (N=18)	P-1 & P-2 (N=28)
Pseudomembranous candidiasis	0% (0/10)	27.8% (5/18)	17.8% (5/28)
Minor aphthous ulceration	10 (1/10)	5.5 (1/18)	7.1 (2/28)
Delayed dental development	0 (0/10)	11.1 (2/18)	7.1 (2/28)
Parotid swelling	0 (0/10)	5.5 (1/18)	3.6 (1/28)
Petechiae	0 (0/10)	5.5 (1/18)	3.6 (1/28)
Total	10% (1/10)*	55.5% (10/18)*	39.3% (11/28)

* (10% v. 55% is significant; Fisher's Exact Test: $P = 0.04$)

The second most frequent oral soft tissue lesion was minor aphthous ulceration (MiAU). A diagnosis of MiAU was based on the following: the lesion was < 10 mm in diameter with a shallow yellow-grey central area surrounded by an erythematous halo; healing had to occur within 14 days. Based on these criteria, two patients (one P-1 and one P-2) had MiAU. Both cases were characterized by a single lesion on the buccal mucosa. Two of the authors observed that these two lesions resolved in 7 and 14 days.

Two of the patients (both P-2) appeared to have delayed dental development. One 37-month-old patient had 12 erupted teeth, consisting of eight primary incisors and four primary first molars. Another patient, 13.5 years old, had eight permanent incisors, four primary canines, four primary first molars, four primary second molars, and four permanent first molars erupted.

Bilateral swelling of the parotid glands, which caused facial disfigurement, was present in one P-2 patient. The swellings were firm, painless, and not associated with xerostomia. One other patient (P-2) presented with palatal petechiae, which represented an oral complication of this patient's thrombocytopenia. Features of linear gingival erythema (LGE) or mucosal lesions characteristic of viral infection were not observed among this patient cohort.

Discussion

This report found that 39.3% (11/28) of the patients had an oral finding associated with HIV infection. An earlier study, reported that 44.1% (15/34) of the P-1 and P-2 subjects had an oral complication.³ Extrapolation of data published in an Italian study indicated that oral lesions were present in 53.8% (21/39) of the P-1 and P-2 patients.⁴ Recently, Jandinski and colleagues reported oral lesions in 41.8% of 101 HIV-infected children enrolled in the Children's Hospital AIDS Program (CHAP) in Newark, New Jersey.⁶ Collectively, these studies indicate that oral findings are common in pediatric HIV infection.

This study found that the P-2 patients had a significantly higher occurrence of oral findings than the P-1 patients ($P = 0.04$). Extrapolation of data from the Italian study⁴ indicated that 14.3% (3/21) of the P-1 patients and 100% (18/18) of the P-2 patients presented with an oral lesion.⁴ These observations support the concept that as HIV disease progresses in children, risk increases for developing oral complications.

Earlier studies indicate that oral candidiasis is one of the most common oral complications of pediatric HIV infection.²⁻⁶ This study found that candidiasis was the most frequent oral finding and occurred in 17.8% (5/28) of the patients. In addition, MiAU, parotid swelling, and oral petechiae were present in 7.1% (2/28), 3.6% (1/28), and 3.6% (1/28) of the patients, respectively. These lesions have been reported previously to occur in pediatric HIV infection less frequently than

oral candidiasis.²⁻⁶ Finally, two of the 28 (7.1%) patients appeared to have delayed dental development based on chronology of dental eruption data.^{8,9}

None of the patients presented with LGE. Information regarding LGE frequency in HIV-infected pediatric patients is limited and confounding. An earlier study reported that LGE was present in one of 34 HIV-infected children.³ Another report, which examined findings in 72 HIV-seropositive children, found that only one patient presented with LGE.¹⁰ In contrast, Jandinski and colleagues reported that LGE was present in 28% of the 101 HIV-infected children in their study population.⁶ Together, these studies indicate that LGE is a potential complication of pediatric HIV infection with variable frequency among different populations.

None of the patients in this study had oral mucosal lesions characteristic of viral infection. In particular, lesions characteristic of herpes simplex virus infection or Epstein Barr virus infection (e.g. hairy leukoplakia) were not identified in any of the patients. The relatively infrequent presentation of oral viral infection in pediatric HIV infection has been reported in earlier studies.²⁻⁶ These observations, coupled with other clinical reports on adults¹ suggest that these types of oral lesions occur less frequently in HIV-infected children than in infected adults. It is possible that these observations in part reflect differences in exposure to viral agents.

In summary, this study supports earlier reports that indicate that oral complications are a common finding in pediatric HIV infection, and that these oral manifestations of HIV infection in young children are different from adults. Finally, this study supports the finding that as HIV disease progresses in children, risk increases for developing oral complications.

Dr. Del Toro is second-year resident in pediatric dentistry, Eastman Dental Center, University of Rochester Medical Center. Dr. Berkowitz is associate professor and director, pediatric residency program, Eastman Dental Center, and chief, division of pediatric dentistry, University of Rochester Medical Center. Dr. Meyerowitz is professor and chair, department of clinical dentistry, University of Rochester Medical Center. Dr. Frenkel was assistant professor, department of pediatrics, and director, pediatric HIV clinic, University of Rochester and is now assistant professor, division of infectious diseases, department of Pediatrics, University of Washington, Seattle.

1. Robertson PR, Greenspan JS, Eds: Perspectives on Oral Manifestations of AIDS. Littleton, MA: PSG Pub, 1988.
2. Ketchem L, Berkowitz RJ, McIlveen L, Forrester D, Rakusan T: Oral findings in HIV seropositive children. *Pediatr Dent* 12:143-46, 1990.
3. Berkowitz RJ, McIlveen L, Ketchem L, Rakusan T: Oral findings in HIV seropositive children. *J Dent Res (IADR Abstracts)* 70:372, 1991 (Abstract 853).
4. Moniaci D, Cavallari M, Greco D, Bruatto M, Raiteri R, Palombo E, Toro PA, Sinicco A: Oral lesions in children born to HIV-1 positive women. *J Oral Pathol Med* 22:8-11, 1993.
5. Ramos-Gomez FJ, Petru A, Hilton JF, Maldonado I, Greenspan D, Greenspan JS: Orofacial manifestations, caries, and periodontal status in pediatric HIV infection. *Pediatr Dent (AAPD abstracts)* 16:159, 1994.

6. Jandinski JJ, Catalanotto F, Murray P, Katz R, Varagiannis E: Oral pathology and pain in pediatric AIDS. *J Dent Res* (AADR Abstracts) 74:137, 1995 (Abstract 1003).
7. EC-Clearinghouse on oral problems related to HIV infection and WHO Collaborating Centre on oral manifestations of the immunodeficiency virus. Classification and diagnostic criteria for oral lesions in HIV infection. *J Oral Pathol Med* 22:289-91, 1993.
8. Lunt R, Law D: A review of the chronology of the eruption of deciduous teeth. *J Am Dent Assoc* 89:872-79, 1974.
9. Logan WHG, Kronfeld R: Development of the human jaws and surrounding structures from birth to age fifteen. *J Am Dent Assoc* 20:379-427, 1933.
10. Leggott PJ: Common oral manifestations and progression of oral disease in HIV infected children. In: *Oral Implications of HIV Infection in the Pediatric Population*, conference proceedings. Washington, DC. 1989, pp 17-21.

Future Annual Sessions of the American Academy of Pediatric Dentistry

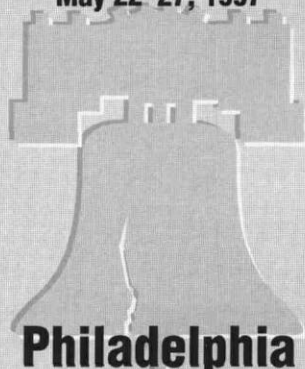
49th Annual Session
May 24-28, 1996



Chicago

Chicago Marriott Hotel


50th Annual Session
May 22-27, 1997



Philadelphia

Philadelphia Marriott Hotel


51st Annual Session
May 21-26, 1998



San Diego

San Diego Marriott Hotel & Marina

52nd Annual Session
May 27-June 1, 1999



Toronto

Sheraton Centre of Toronto Hotel & Towers