



Compound odontoma – diagnosis and treatment: three case reports

Branca Heloísa de Oliveira DDS, MS Vera Campos DDS, MS Sonia Marçal DDS, MS

Dr. Oliveira and Dr. Campos are assistant professors, and Dr. Marçal is associate professor, Department of Community and Preventive Dentistry, Faculty of Dentistry, Rio de Janeiro State University, Brazil. Correspond with Dr. Oliveira at branca@uerj.br

Abstract

Odontomas are the most common type of odontogenic tumors and generally they are asymptomatic. This paper describes three cases of compound odontomas diagnosed in children due to dislodgement or over-retention of primary anterior teeth and/or swelling of the cortical bone. In all cases, the surgical excision of the lesions was performed and, in one case, orthodontic treatment was adopted in order to move an impacted permanent tooth to its normal position. The results achieved indicate that the early diagnosis of odontomas allows the adoption of a less complex and expensive treatment and ensures better prognosis. (Pediatr Dent 23:151-157, 2001)

Oodontomas are considered to be developmental anomalies resulting from the growth of completely differentiated epithelial and mesenchymal cells that give rise to ameloblasts and odontoblasts. These tumors are basically

formed of enamel and dentin but they can also have variables amounts of cement and pulp tissue.¹ During the development of the tumor, enamel and dentin can be deposited in such a way that the resulting structures show an anatomic similarity to normal teeth, in which case the lesion is classified as a compound odontoma. However, when the dental tissues form a simple irregular mass occurring in a disorderly pattern, it is described as a complex odontoma.² Compound odontomas appear more frequently than complex odontomas.^{3,4}

These odontogenic tumors can be found anywhere in the dental arches. The majority of odontomas which are located in the anterior region of the maxilla are compound, while the great majority of odontomas located in the posterior areas, especially in the mandible, are complex odontomas.^{1,5,6}

The etiology of the odontoma is unknown.⁷ However, it has been suggested that trauma and infection at the place of the

Table 1. Major Characteristics of Compound and Complex Odontomas

Major Characteristics	Compound Odontoma	Complex Odontoma
Frequency	The relative frequency among odontogenic tumors varies between 9% and 37%. It's considered the commonest odontogenic malformation.	The relative frequency among odontogenic tumors varies between 5% and 30%.
Age	The majority of cases appear before the age of 20, making it a lesion of childhood/adolescence.	The majority of cases occur before the age of 30 with a peak in the second decade of life.
Gender	Male and female subjects are equally affected.	Male and female subjects are equally affected.
Sites	Maxillary anterior region is the most frequent site.	Posterior mandibular followed by anterior maxilla are the most frequent sites.
Clinical presentation	Painless, non-aggressive lesion, with a more limited potential growth than the complex odontoma. Often associated with an unerupted permanent tooth.	Painless, slow-growing and expanding lesion. Often associated with an unerupted permanent tooth.
Radiological features	Radiopaque mass of multiple, small, calcified structures with an anatomical similarity to normal teeth usually surrounded by a narrow radiolucent zone.	More or less amorphous mass of calcified material with the radiodensity of tooth structure, which bears no anatomical resemblance to tooth, surrounded by a narrow radiolucent rim.
Treatment	Conservative surgical enucleation.	Conservative surgical enucleation.

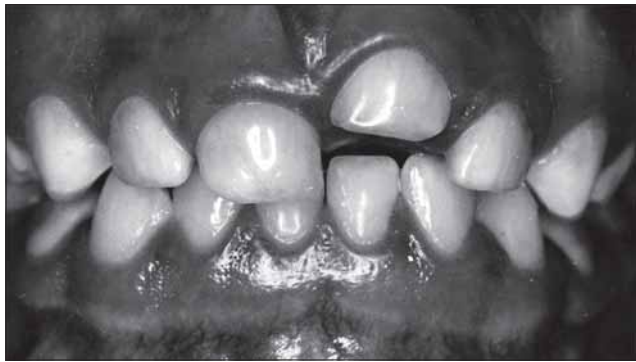

Fig 1. Case 1. Clinical aspect showing dislodgement of the upper left primary central incisor.

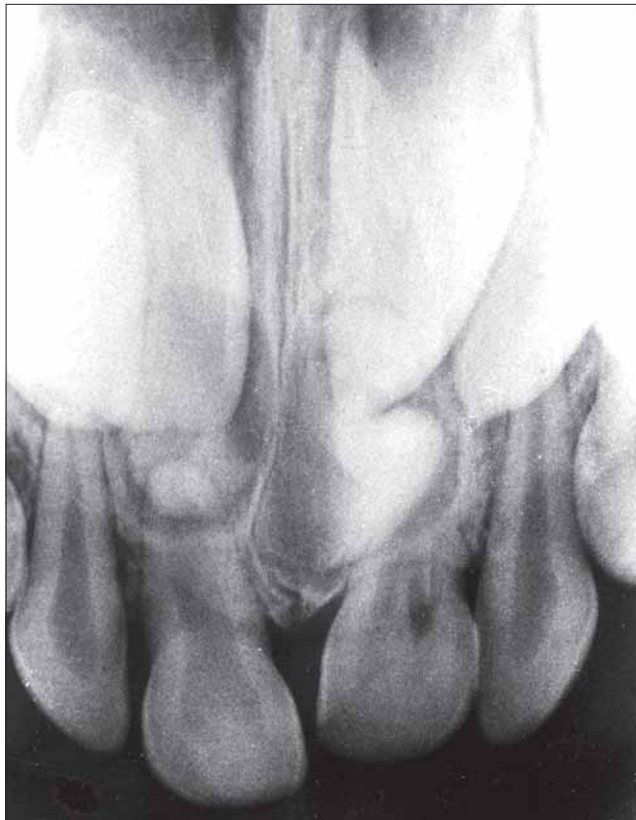

Fig 2. Case 1. Periapical radiograph showing two lesions of compound odontoma.

lesion can offer ideal conditions for its appearance.^{7,8} In general they are asymptomatic, have slow growth,¹ and seldom exceed the size of a tooth, but when large can cause expansion of the cortical bone.^{1,2}

Odontomas may be diagnosed at any age but they are usually detected during the first two decades of life.^{1,3} One study analyzed 396 cases and showed that diagnosis usually happens between ages 11 and 15 years.⁴ Another study comprising 149 cases concluded that the lesions are detected most often during the second decade of life.⁵ Many times odontomas are found associated with unerupted teeth.^{1,6,9,10-14} The canines, followed by upper central incisors and third molars, are the most frequent teeth impacted by odontomas.⁴ In a very few instances odontomas are related to missing teeth.⁸ Generally these malformations are intraosseous, but occasionally they may erupt into the oral cavity.^{8,14}

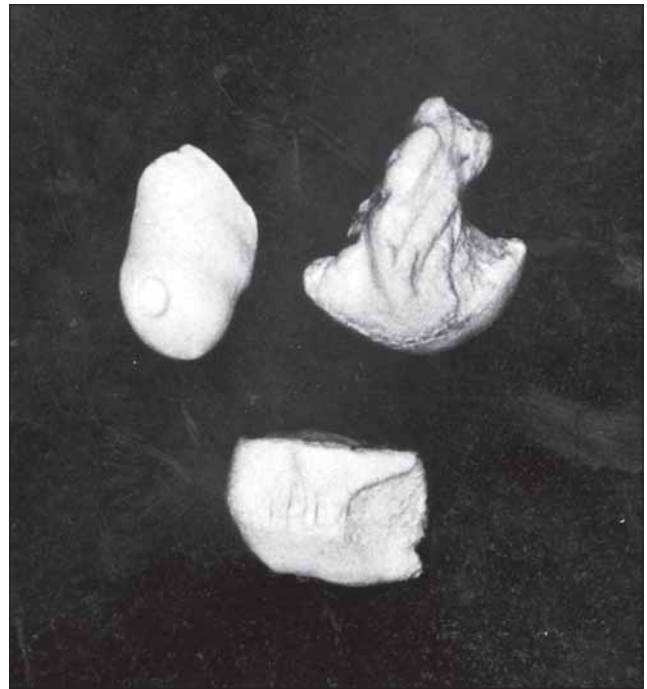


Fig 3. Case 1. Three mineralized structures removed from the interior of the lesion.

Radiographic aspects of odontoma are characteristic. The complex odontoma appears as an irregular mass of calcified material surrounded by a thin radiolucent area with smooth periphery, and the compound type shows calcified structures resembling teeth in the center of a well-defined radiolucent lesion. A periodontal and pericorony space characteristic of unerupted teeth is seen around each tooth.^{3,7} A developing odontoma can be discovered by routine radiography, but may cause difficulty in identification due to lack of calcification.⁷

The histological examination of odontomas often shows the presence of enamel matrix, dentin, pulp tissue, and cementum that can, but need not, exhibit a normal relationship.^{1,7} Compound odontomas are formed by tooth-like structures which resemble pulp tissue in the central portion surrounded by a dentin shell and partially covered by enamel. Complex odontomas are conglomerates without orientation of dentin, enamel, enamel matrix, cementum, and areas of pulp tissue. The capsule of connective tissue that surrounds an odontoma is similar to the follicle that covers a normal tooth.⁷

Odontomas are treated by conservative surgical removal and there is little probability of recurrence.^{1,8} Ameloblastic fibro-odontomas and odontoameloblastomas show a great resemblance to common odontomas, especially in the radiographic examination. Therefore, it has been suggested that all specimens should be sent to an oral pathologist for microscopic examination.^{7,8} Besides, proper patient care should include careful clinical and radiographical follow-up.¹⁵

The ameloblastic fibro-odontoma is defined as a tumor with the general features of an ameloblastic fibroma but that also contains enamel and dentin.^{1,16} It is usually encountered in children with an average age of 10 years.¹ It has been suggested that ameloblastic fibro-odontomas should not be considered as true neoplastic odontogenic lesions, but rather as a stage preceding the complex odontoma which would be the final

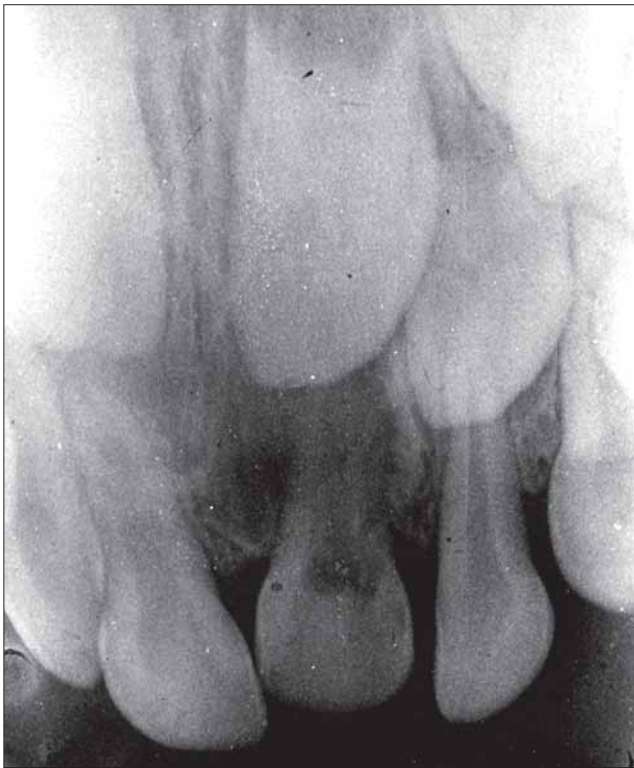


Fig 4. Case 1. Periapical radiograph post surgery.

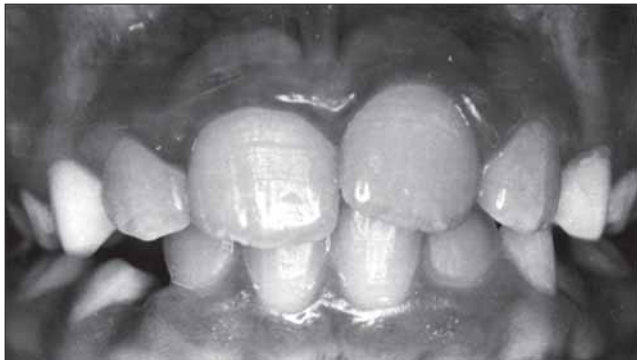

Fig 5. Case 1. Intraoral view 3 years after surgery.

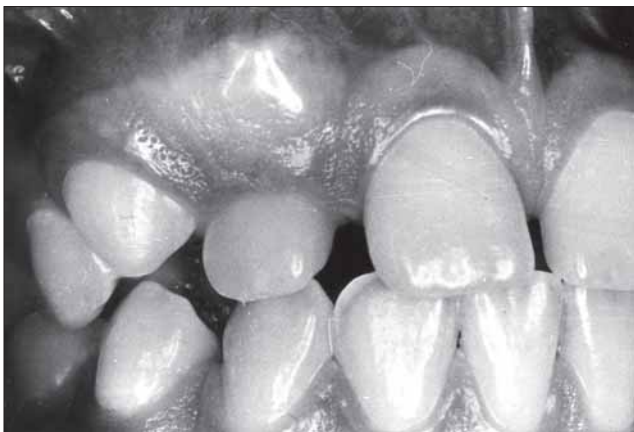


Fig 6. Case 2. Intraoral view before surgery.

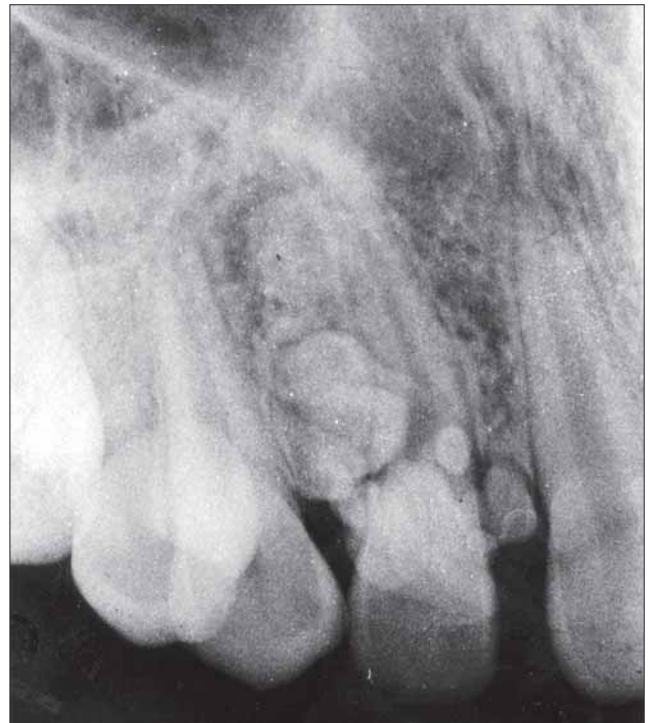


Fig 7. Case 2. Periapical radiograph showing the presence of a compound odontoma.

stage in this line of development of hamartomatous lesions.¹⁵ Other authors consider that, despite the fact that some lesions diagnosed as ameloblastic fibro-odontomas can be developing odontomas, all cases of ameloblastic fibro-odontomas should not be considered as hamartomatous in nature since there are rare cases of ameloblastic fibro-odontomas showing true neoplastic behavior.¹⁶ The majority of the ameloblastic fibro-odontomas are found in the posterior region of the mandible. These lesions seem to be exclusively central or intraosseous tumors. They are also characterized by being painless and slow-growing.¹⁵ Radiographically, the tumor shows a well-defined unilocular or, rarely, multilocular radiolucent defect that contains a variable amount of calcified material with the radiodensity of dental hard tissues. The calcified material within the lesion may appear as multiple, small radiopacities or as a solid conglomerate mass.^{1,15} It can be differentiated from the odontoameloblastoma by the fact that it is well circumscribed and usually separates easily from its bony bed.² The treatment of choice is conservative surgical enucleation and prognosis is excellent.^{1,15} However, development of an ameloblastic fibrosarcoma after curettage of an ameloblastic fibro-odontoma has been reported.¹

The ameloblastic fibrosarcoma is considered to be the malignant counterpart of the ameloblastic fibroma and often represents a recurrence of a tumor previously diagnosed as an ameloblastic fibroma or an ameloblastic fibro-odontoma.¹ It is characterized by a malignant transformation of the ectomesenchymal component of the tumor and not the odontogenic epithelium.¹⁶ The average age at time of diagnosis for the ameloblastic fibrosarcoma is 27.5 years, as opposed to 14.8 years for the ameloblastic fibroma and 9 years for the ameloblastic fibro-odontoma. This age difference supports a step-wise progression of a benign to a malignant tumor.¹⁵ Ra-

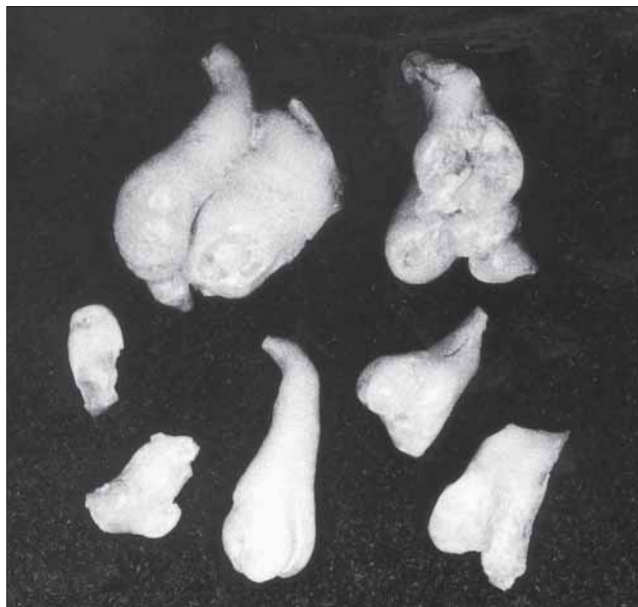


Fig 8. Case 2. Seven mineralized structures with tooth-like appearance removed from the interior of the lesion.

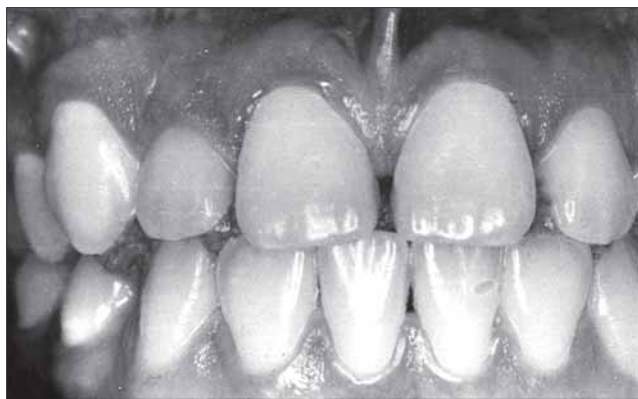

Fig 9. Case 2. Intraoral view 1 year after surgery.

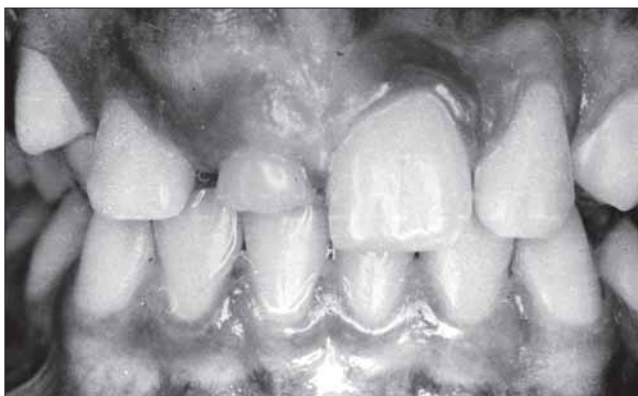

Fig 10. Case 3. Intraoral view showing overretention of the primary upper right central incisor.

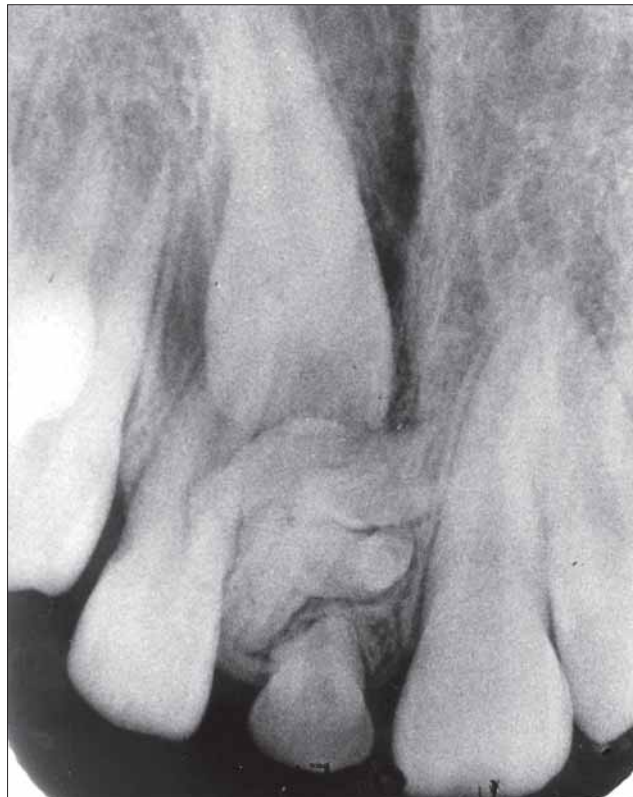

Fig 11. Case 3. Periapical radiograph showing the presence of a compound odontoma blocking the eruption of the permanent upper right central incisor.

diographically, the ameloblastic fibrosarcoma shows an ill-defined destructive radiolucent lesion that suggests a malignant process. Pain and swelling associated with rapid clinical growth are common complaints. Patients diagnosed with this condition should be treated by radical surgical excision, since the tumor is locally aggressive and infiltrates adjacent bone and soft tissues. Long-term prognosis is uncertain because of the few reported cases with adequate follow-up.¹

The odontoameloblastoma is an extremely rare odontogenic tumor that contains an ameloblastomatous component together with odontoma-like elements. This lesion appears to occur more often in the mandible of young patients. Radiographically, this tumor shows a radiolucent, destructive process that contains calcified structures. These have the radiodensity of tooth structure and may resemble miniature teeth or occur as larger masses of calcified material similar to a complex odontoma. Multiple recurrences of odontoameloblastomas have been reported after local curettage and it appears that this tumor has the same biologic potential as the ameloblastoma. So, it is considered wise to treat a patient with an odontoameloblastoma in the same manner as one with an ameloblastoma. However, because of the rarity of odontoameloblastomas, there are no valid data on the long-term prognosis.^{1,2}

When the odontomas are associated with unerupted teeth, orthodontic traction of the impacted tooth soon after removal of the lesion may be needed, especially if it is not diagnosed and treated early.^{5,12}

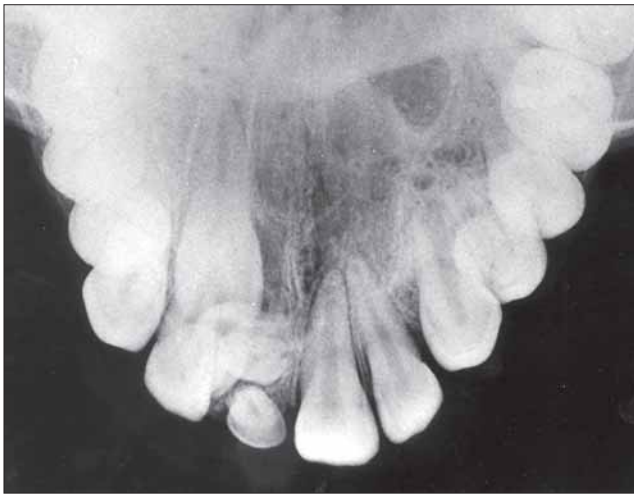


Fig 12. Case 3. Occlusal radiograph showing small mineralized structures in the interior of the lesion.

Case reports

Case 1

A 5-year-old white female presented to the pediatric dental clinic with a chief complaint of changing position of the upper left primary central incisor. During the examination, the upper left primary incisor crown revealed a labial displacement and showed an intrusion when compared to the crowns of the neighboring teeth (Fig 1). According to the mother there was no previous dental trauma.

Radiographic examination (Clark's Technique) revealed the presence of two lesions of compound odontomas in the palatal region of the upper primary central incisors (Fig 2). Surgery was performed to remove the two lesions and three mineralized structures showing a tooth-like appearance were found within them (Fig 3). The surgical procedure was performed by an oral surgeon assisted by a pediatric dentist. The patient was treated under local anesthesia, without any premedication and the patient's behavior during the procedure was classified as definitely positive, according to Frankl Behavior Rating Scale.¹⁷ Postoperative oral and written instructions specifically related to the maintenance of an appropriate oral hygiene, ingestion of cold and soft meals, refraining from physical exercise during 48 hours, and management of pain were given to the patient's mother. The primary incisors were left in the arch and buccal reduction of the position of the upper left primary lateral incisor was observed (Fig 4). When the upper permanent central incisors erupted into the oral cavity, their crowns were proclined. A removable appliance was used to improve their position. Three years after the surgery all permanent anterior teeth were present in the maxillary dental arch, but a discrepancy in the upper midline could be noticed (Fig 5).

Case 2

A 12-year-old female patient presented to the pediatric dental clinic complaining about an increased volume of gingiva in the root region of the upper right permanent central and lateral incisors and upper right permanent canine, and also a proclined labial crown of the upper right permanent lateral incisor (Fig 6). The patient reported no trauma in the upper region of the

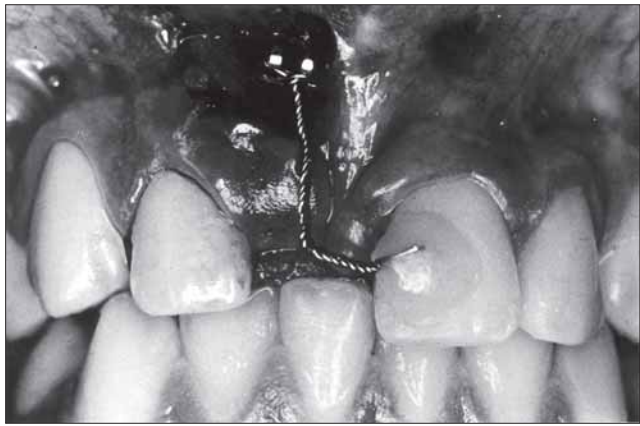


Fig 13. Case 3. Bracket bonded to the crown of the impacted tooth.

mouth. Intraoral radiographic examination showed a compound odontoma-like lesion, located buccally to the root of the upper permanent lateral incisor (Fig 7). The lesion containing seven structures like small teeth in different developing stages was removed surgically (Fig 8). One year after the surgery it was verified that the permanent lateral incisor had returned to its normal position and that there was no recurrence of the lesion (Fig 9).

Case 3

An 11-year-old male patient presented to the pediatric dental clinic for routine dental care. He was worried about the presence of an upper primary central incisor, although the neighboring teeth were all permanent. The mother reported that when the child was five months old he fell hitting his mouth on the floor and after that the primary teeth erupted with a dark discoloration. Clinical examination showed an overretention of the tooth and an increased volume next to the distal area of the root of the primary upper right central incisor (Fig 10).

Radiographic examination (Clark's and Occlusal Technique) revealed the presence of an odontoma-like lesion in the buccal region of the primary incisor root. The lesion caused an impacted position of the corresponding permanent incisor (Fig 11). Due to its complexity, the case was managed by a multidisciplinary team including a pediatric dentist, an orthodontist and an oral surgeon. Afterward, a periodontist was also consulted. Surgical removal of the odontoma was performed and a number of calcified small structures looking like teeth were found in it, as was anticipated from the occlusal radiograph (Fig 12). The surgery was performed by an oral surgeon assisted by a pediatric dentist. The patient was treated under local anesthesia, without any premedication.

Because the impacted permanent tooth showed a fully formed root resulting in little spontaneous eruption potential, it was decided that an orthodontic device would have to be placed in order to guide the impacted tooth into its position. So, at the time of the surgery, a bracket was bonded to the labial surface of the crown (Fig 13). After healing of the soft tissues, traction of the unerupted maxillary right central incisor was initiated (Figs 14 and Fig 15). Later, it was decided that, in order to achieve a better control of the movement of the tooth, the palatal bar should be replaced by a partial fixed appliance (Fig 16). All orthodontic procedures were performed

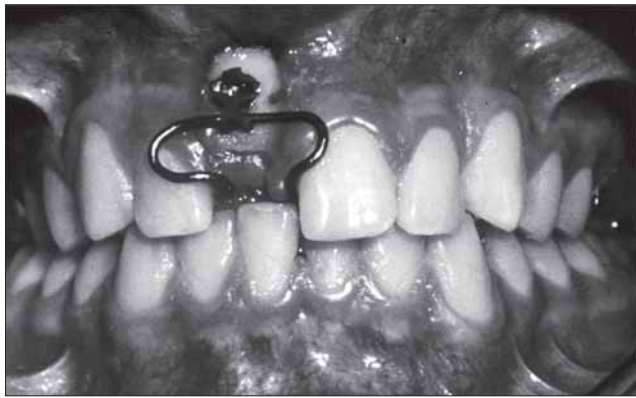

Fig 14. Case 3. Appliance initially used for traction of the impacted tooth (front view).

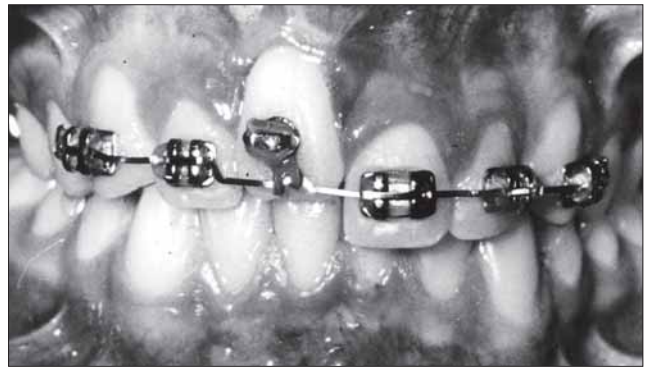

Fig 16. Case 3. Appliance used for final traction of the impacted tooth .

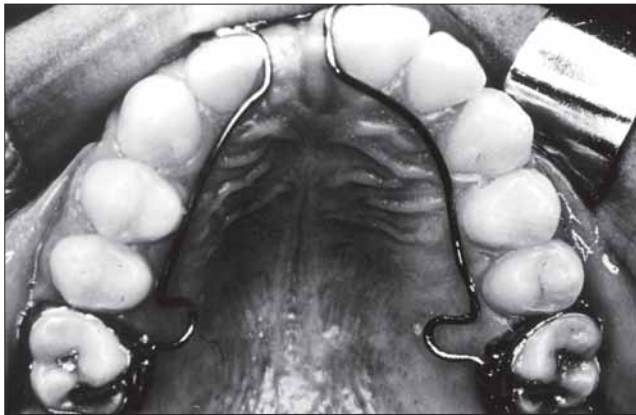


Fig 15. Case 3. Appliance initially used for traction of the impacted tooth (occlusal view).

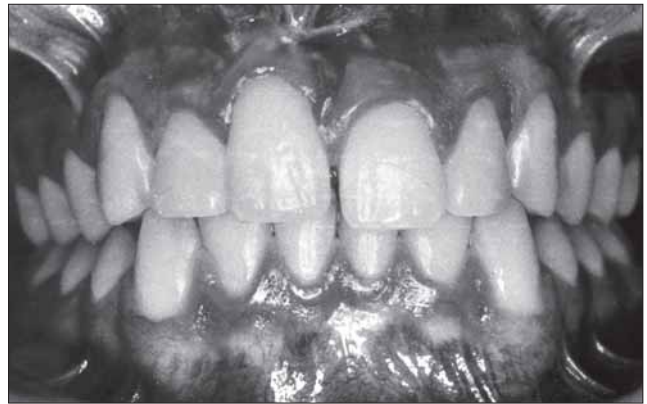

Fig 17. Case 3. Intraoral view three years after surgery .

by a post-graduate student under the supervision of an orthodontist at the Orthodontics Department. After three years, the permanent maxillary right central incisor was finally brought into the dental arch but uneven gingival margins and clinical crowns of the upper incisors could be noticed (Fig 17). Upon reevaluation of the case, the dental team decided that the patient should be submitted to full fixed orthodontic treatment.

Discussion

Odontomas are relatively common odontogenic lesions, generally asymptomatic, and are rarely diagnosed before the second decade of life. They frequently lead to impaction or delayed eruption of permanent teeth.^{1,2}

The three cases described in this study were initially diagnosed as compound odontomas since the radiographic examination of the lesions showed a variable number of calcified interior structures anatomically similar to small teeth.^{1,2,8,9} This diagnosis was later confirmed by histological examination of the lesions after their surgical removal.

All tumors were found on the anterior region of the maxilla, which, according to many researchers^{5,6,7} is the most common location. One of the patients had suffered a trauma in the region where the lesion developed. According to the literature, the development of the odontoma could be related to this trauma.^{7,8} In two cases the odontoma produced a small swelling of the cortical bone and in Case 2 this occurrence contributed to the discovery of the lesion. In both cases the

observed swelling was possibly related to the size of the lesions, since one of them showed seven and the other nine small tooth-like interior structures. In Case 1, although there were only three tooth-like interior structures in the lesion, they were large enough to dislodge the primary incisor, which prompted the mother of the child to seek dental treatment.

The third case showed a large odontoma causing impaction of a permanent tooth. Delayed diagnosis of the lesion resulted in complete root formation of the unerupted upper central incisor, making it necessary to use orthodontic traction of the affected tooth in order to guide it to an adequate position in the dental arch. This therapeutic approach is recommended by Bengston et al.⁵ and Oliver and Hodges.¹² When the impacted tooth came into the dental arch, it was observed that the same crown length for the upper right and left central incisors was not achieved. According to Kajiyama and Kay¹⁸ this kind of problem is often encountered following the traction of unerupted teeth, but it may be prevented by minimizing the trauma to the gingiva and surrounding tissues during the surgical procedures using a "closed eruption technique," which guides the tooth to the alveolar crest and pulls it in a backward-downward direction. In this technique, the surgical flap is repositioned and sutured in place in a way that only the ligating wire attached to the bracket, which is bonded to the palatal surface of the unerupted tooth, is exposed into the oral cavity. Although it would have been better if gingival recession had been avoided in Case 3, it is still possible to restore an adequate gingival margin appearance by performing periodontal surgery.

In Case 1, the diagnosis was done during the period of primary dentition, and surgical removal of the lesion was effected before the exfoliation of the primary teeth. Ideally, odontomas should be removed when the permanent teeth adjacent to the lesion exhibit about one half of their root development because this ensures safety of the normal permanent teeth and prevents interference with their eruption. Kaban¹⁹ states that odontomas are easily enucleated and adjacent teeth that may have been displaced by the lesion are seldom harmed by the excision since they are usually separated from the lesion by a septum of bone. In Case 1, early treatment could be performed because the lesion was localized close to the incisal edge of the upper permanent incisor crowns, which were already fully formed. For the same reason, iatrogenic damage to the root formation of these teeth was very unlikely. The early diagnosis and treatment of the pathology in this case probably prevented the impaction of the permanent upper incisors. However, upon eruption the upper left permanent central incisor was labially and mesially inclined while the upper right permanent central incisor was distally and lingually inclined. After being treated with removable appliances for one year, the child had her four upper permanent incisors aligned in the maxillary arch. Although a discrepancy in the upper midline could be easily noticed, it could not be attributed solely to the presence of the odontoma in the past, since the child had habits such as fingernail biting and chewing pencils.

Clinical experience suggests and the dental literature supports that an individualized radiographic examination of any pediatric patient that presents clinical evidence of delayed permanent tooth eruption or temporary tooth displacement with or without a history of previous dental trauma should be performed. As was demonstrated by this report, early diagnosis of odontomas allows adoption of a less complex and less expensive treatment and ensures better prognosis.

The authors are grateful to Dr. Hannelore T. Loevy, Professor, Department of Pedodontics, University of Illinois, and Hilton Souchois de Mello, Professor, Department of Community and Preventive Dentistry, Rio de Janeiro State University, for reviewing this manuscript.

References

1. Neville BW, Damm DD, Allen CM, Bouquot JE: Oral and Maxillofacial Pathology. Philadelphia: Saunders, 1995, pp 531-33.
2. Cawson RA, Binnie WH, Eveson JW: Color Atlas of Oral Disease. Clinical and Pathological Correlations. Hong Kong: Mosby-Wolfe, 1993, pp 6-19.
3. Owens BM, Schuman NJ, Mincer HH, Turner JE, Oliver FM: Dental odontomas: a retrospective study of 104 cases. *J Clin Pediatr Dent* 21:261-64, 1997.
4. Katz RW: An analysis of compound and complex odontomas. *ASDC J Dent Child* 56:445-49, 1989.
5. Bengston AL, Bengston NG, Benassi, LRDC: Odontomas em pacientes pediátricos. *Revista de Odontopediatria* 2:25-33, 1993.
6. Budnick SD: Compound and complex odontomas. *Oral Surg Oral Med Oral Pathol* 42:501-506, 1976.
7. Shafer WG, Hine MK, Levy BM: A Textbook of Oral Pathology, 4th Ed. Philadelphia: Saunders, 1983, pp 308-11.
8. Areal-López L, Silvestre DF, Gil LJ: Compound odontoma erupting in the mouth: 4 year follow-up of a clinical case. *J Oral Pathol* 21:285-88, 1992.
9. Shulman E, Corio RL: Delayed eruption associated with an odontoma. *ASDC J Dent Child* 54:205-207, 1987.
10. Brunetto AR, Turley PK, Brunetto AP, Regattieri LR, Nicolau GV: Impaction of a primary maxillary canine by an odontoma: surgical and orthodontic management. *Pediatr Dent* 13:301-302, 1991.
11. Gallien GS, Schuman NJ, Sharp HK, McIlveen LP: Odontoma of a maxillary central incisor in a 10-year-old black male. *J Pedod* 10:352-55, 1986.
12. Oliver RG, Hodges CGL: Delayed eruption of a maxillary central incisor associated with an odontome: report of case. *ASDC J Dent Child* 55:368-71, 1988.
13. Thwaites MS, Camacho JL: Complex odontoma: report of case. *ASDC J Dent Child* 54:286-88, 1987.
14. Giunta JL, Kaplan MA: Peripheral, soft tissues odontomas. *Oral Surg Oral Med Oral Pathol* 69:406-11, 1990.
15. Philipsen HP, Reichart PA, Praetorius F: Mixed odontogenic tumours and odontomas. Considerations on interrelationship. Review of the literature and presentation of 134 new cases of odontomas. *Oral Oncology* 33:86-99, 1997.
16. Takeda Y: Ameloblastic fibroma and related lesions: current pathology concept. *Oral Oncology* 35:535-40, 1999.
17. Wright, G, Starkey, PE, Gardner, DE: Child Management in Dentistry. Bristol: Wright, 1987, pp 81-82.
18. Kajiyama, K, Kai, H: Esthetic management of an unerupted maxillary central incisor with a closed eruption technique. *Am J Orthod Dentofacial Orthop* 118:224-28, 2000.
19. Kaban, LB: Pediatric Oral and Maxillofacial Surgery. Philadelphia: Saunders, 1990, pp 111-12.