

Clinical evaluation of a restoration containing fluoride: two-year results

Gary D. Derkson, DMD Alan S. Richardson, DDS, MSc Gordon M. Jinks, DDS

Abstract

Fluoride-containing restorations were placed on the distal surface of primary second molars to evaluate their effectiveness in controlling caries on the mesial surface of the approximating permanent first molars. A half-mouth study design was used with the control primary second molars in the same arch, either restored with amalgam or left sound. After two years, radiographs of 56 pairs of permanent first molars in 48 children were evaluated independently by three examiners blind to whether they were examining study or control surfaces. In 15 matched pairs, the study restoration had the effect of preventing a carious lesion on the mesial surface of a permanent first molar. In six matched pairs, the study restoration had the effect of not preventing progression of a carious lesion on the mesial surface of a permanent first molar. In 35 matched pairs, there was no effect observed. At the two-year evaluation, the study restorations with added fluoride controlled caries progression significantly on the adjacent mesial surfaces of permanent first molars when compared to the controls using the Sign test ($P < 0.05$).

The clinical management of caries-susceptible children continues to be a problem. Having restored the occlusal surface of a permanent first molar, it is frustrating to both the clinician and child to find caries on the mesial surface of the same permanent first molar at a subsequent examination. This problem can develop despite the most diligent use of preventive procedures.

Jinks (1963) reported on a study where a silicate cement with added fluoride was placed in primary second molars adjacent to the mesial surfaces of permanent first molars. This was done by placing the silicate cement in a "tunnel" preparation, through to the distal surface of the primary second molar. Caries was reduced by 70% compared to the control teeth after three years. The problem with the "tunnel" preparation was the frequent breakdown of the marginal ridge of the primary second molar. Even though the principle of

making fluoride available at the mesial of permanent first molars had proved to be sound, an alternate approach was developed by Jinks. The "tunnel" was replaced with standard distal-occlusal preparations. The cement with fluoride added was placed in the distal boxes and covered with silver amalgam. The purpose of this study was to measure this test restoration's effectiveness in preventing the development and progression of caries on the mesial surface of first permanent molars and to record the restoration's longevity. The tunnel-restoration has been re-introduced recently (Hunt 1984).

Method

After clinical and radiographic examination, children with primary second molars demonstrating at least one carious lesion were selected to participate in the study. The primary second molar in the adjacent quadrant was designated as the control area and restored, if indicated, with amalgam (Dispersalloy, Johnson & Johnson). The mesial surfaces of the permanent first molars were free of restorations and caries requiring treatment. Distal restorations containing silicophosphate cement with fluoride added were placed in one of each pair of primary second molars. At the time of cavity preparation, neither topical fluoride nor remineralizing solution was placed on the mesial surfaces of the permanent first molars.

All restorations were prepared in the following way by senior dental students. After rubber dam placement a standard DO amalgam cavity was prepared in the primary second molar. The matrix band was placed and wedged. A stiff mix of silicophosphate cement (Petalit-Howmedica International Ltd., Dental Fillings Division, London, England) with fluoride and alloy fillings added was placed in the distal step. Amalgam was hand-condensed immediately on the still soft cement

(Fig 1). The matrix was removed, amalgam carved, rubber dam removed and occlusion checked.

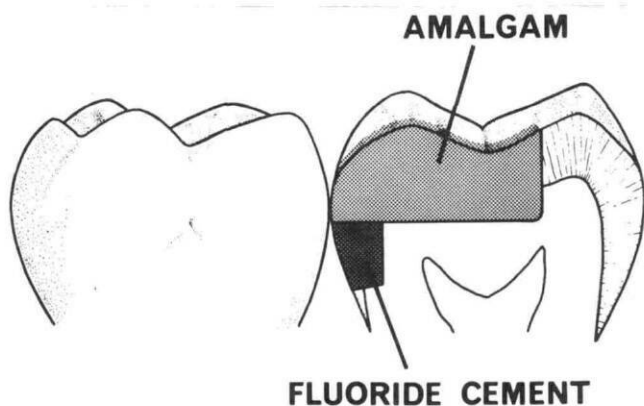


Fig 1. Relationship of fluoride-containing cement to silver amalgam in the test preventive restoration.

The cement for the restoration was prepared by placing two drops of silicophosphate liquid (Petalit-Howmedica International Ltd., Dental Fillings Division London, England) on a glass slab. Beside the liquid was placed as much alloy filings as would fit into a 2 mm diameter circle (35 mg), and as much sodium silica fluoride as would fit into a 2 mm diameter circle (15 mg). The purpose of the alloy filings is to make the restoration radiopaque. A large amount of silicophosphate powder was placed to one side on the glass slab. The alloy filings and sodium silicofluoride were mixed homogeneously with the silicophosphate liquid. Then, a large amount of silicophosphate powder was incorporated into the liquid mixture. Smaller amounts of powder were added until the mix was thick and curled on the slab. The cement mixture was gathered into one ball and was rolled with the fingers, placed on the end of a plastic instrument, and placed in the distal of the cavity preparation to the level of the pulpal floor. At this point the amalgam was condensed.

A total of 111 children received at least one DO restoration containing silicophosphate cement with fluoride added by mid-July, 1981. At one year and two year intervals the condition of the restoration was evaluated clinically and radiographically using the criteria listed in Table 1. Also, the condition of the mesial surface of the study and control permanent first molars was

TABLE 1. Condition of Restoration

1. Intact
2. Chipped margin
3. Fractured restoration
4. Needs replacing
5. Replaced
6. Exfoliated
7. Some cement loss
8. Other

scored (Table 2). In order to prevent possible bias during the evaluation of the permanent first molars, the study

TABLE 2. Criteria for the Radiographic Condition of the Mesial Surfaces of First Permanent Molars

- | |
|--------------------------|
| 1. Sound |
| 2. Initial Enamel Caries |
| 3. Caries to DEJ |
| 4. Caries in Dentin |
| 5. Restored |
| 6. Other |

and control primary second molars were masked as illustrated in Fig 2. Three examiners evaluated the radiographs independently. Disagreements occurred in only six instances and were resolved by consultation.

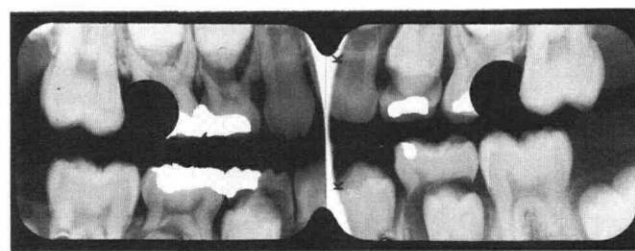


Fig 2. Masking of test and control restoration to prevent bias in evaluating the mesial surfaces of permanent first molars.

Results

At the one year examination 67 restorations in 56 children were evaluated clinically. Also, radiographs of 67 pairs of permanent first molars were evaluated for the presence of caries. After two years, 48 children who had 58 study restorations placed were available for examination. Twenty-five study teeth had exfoliated; 25 restorations were sound; four had chipped margins; one was fractured; and three had been replaced (Table 3). Twenty-two of 30 restorations showed some loss of cement radiographically. Twelve per cent of the study restorations had failed. Of these, 9% (three) had been replaced and were considered to have failed.

TABLE 3. Condition of the Restorations 24 Months After Replacement

	N	%
Sound	25	43
Chipped margin	4	7
Fractured	1	2
Replaced	3	5
Exfoliated	25	43
Total	58	100

At the two-year examination, 56 pairs of permanent first molars were evaluated radiographically for mesial caries. Two pairs were not evaluated because stainless

steel bands had been placed as part of space maintenance therapy. These results were compared to the condition recorded at the initial examination (Table 4).

TABLE 4. Changes in Radiographic Conditions of the Mesial Surface of First Permanent Molars: After Two Years

	Control	Study
Initial caries(°) becoming sound (1)	1	8
Initial caries(°) becoming restored (5)	0	3
Sound (°) becoming carious. (2) or initial caries (°) progressing (3,4)	11	3
No change	44	42
	56	56

After two years, the radiographic condition of the matched pairs of mesial surfaces of permanent first molars was compared (Table 5). In 15 matched pairs, the

TABLE 5. Comparison of the Matched Pairs of Mesial Surfaces of First Permanent Molars for Radiographic Caries Progression After Two Years

	N	%
Caries not prevented	6*	11
Caries prevented	15**	27
Neutral	35	62
	56	100

* Includes three teeth where initial caries had been restored.

** Difference significant $P < 0.05$ level, Sign test.

study restoration had the effect of preventing a carious lesion; that is, the control surface became carious and the study surface remained healthy. In three of the matched pairs, caries progressed on the study permanent first molar relative to the control. Three of the study permanent first molars had received MO amalgam restorations. All had had radiographically detected enamel caries at the time of the placement of the study restoration. It was assumed that caries had progressed. Thirty-five of the matched pairs remained neutral showing no effect from either the control or study restoration. Using statistical analysis by the Sign test (Siegel 1956), caries progression on the mesial surfaces of permanent first molars was controlled significantly by the study restoration ($P < 0.05$).

Discussion

Fluoride has proven to be the most effective agent for the prevention of caries. Populations where fluoridated water is consumed have a significant reduction in caries (Duxbury et al. 1985). Alternate methods of fluoride therapy also are successful. For example, systemic administration with tablets (Fejerskov et al. 1987), professional topical application (Clark et al. 1987), home

application with toothpastes (Glass 1986), mouthrinses (Corpron et al. 1986), and fluoride gel application (Goorhuis et al. 1986). With the exception of water fluoridation, all the methods of making fluoride available to the teeth involve the cooperation of the child or parent. Having fluoride available to the teeth continuously through a slow release mechanism in the oral cavity would seem to be an ideal to strive for (Mirth et al. 1978; Hanes 1986). The preventive restoration described in this paper has demonstrated potential as another method for controlling caries.

In spite of extensive study, neither the caries process nor the action of fluoride is understood completely. Silverstone (1977) has shown that initial enamel caries involves a demineralization of the sub-surface, leaving the surface enamel intact. The demineralized area on the mesial surface of the permanent first molars exposed by the DO cavity preparation in the second primary molar shown in Fig 3 is an example of the situation frequently observed in clinical practice. Presumably, there is a dynamic equilibrium established across this intact enamel surface. When the pH is lowered by acid-producing plaque, the equilibrium is pushed towards calcium and phosphate ions coming out across this intact enamel layer. The role of fluoride in this process may be to either act in a manner similar to a catalyst favoring mineralization, or as a stabilizing influence preventing the movement of calcium and phosphate ions out of the enamel subsurface.

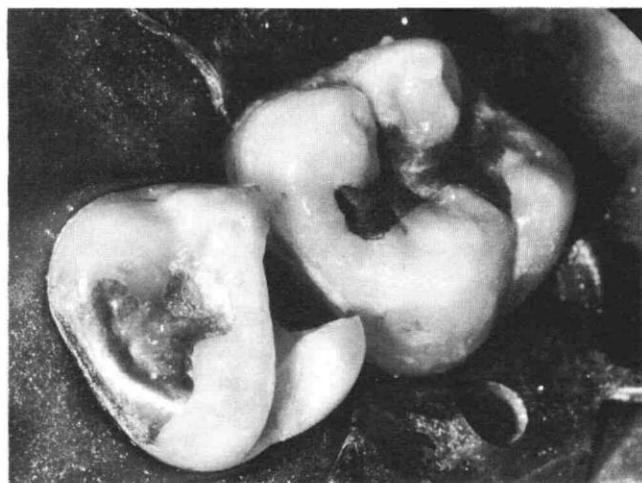


Fig 3. Demineralized area on the mesial surface of the permanent first molar frequently encountered in clinical practice.

Fluoride release from restorative materials has been studied (Skartveit et al. 1986). A report of an in vitro study of various restorative materials including silicate and silicophosphate cement showed that silicophosphate cement released significantly greater quantities of fluoride than the other materials studied (Forsten

et al. 1976). The preventive restoration described in this report may provide a continuous elevated source of fluoride ions (Derkson et al. 1982). This fluoride availability may be responsible for the control of caries observed in this study.

During this study the preventive restoration's durability was comparable to amalgam restoration (Dawson et al. 1981). (Here, durability indicates that the teeth were restored to function while being free of disease and symptoms.) This should not be a surprise, since clinical trials have demonstrated that silicophosphate cements have superior durability in both nonabrasive and abrasive areas (Kuhn et al. 1982; Phillips et al. 1987). However, it is possible that the physical and chemical properties are altered as a result of the addition of sodium silicofluoride and alloy filings. This possible alteration does not seem to be clinically significant at the two year evaluation. Also of interest is the possible effect on the health of the pulps of the second primary molars. *In vivo* and *in vitro* studies indicate that silicophosphate cement might be harmful to the pulp (Dahl et al. 1975; Meryon and Brown 1983). It was not the aim of this study to determine whether silicophosphate cement with sodium silicofluoride and alloy filings added had any effect on the pulp of the covering of the axial and gingival floor. However, within the limitations of the study (radiographs and clinical records), none of the second primary molars observed exhibited furcation radiolucencies, required pulp therapy or extraction as a result of the placement of the silicophosphate cement with fluoride added. The reason for this is open to speculation but may be due to the relative maturity of the tooth at the time of cement placement.

The results of the present study indicate that this preventive restoration merits the consideration of dental practitioners who treat children. It may be considered an alternative to the amalgam restoration in situations where a distal surface of a second primary molar requires restoration. Under the conditions of this study, the silicophosphate cement with fluoride restoration added performs with acceptable durability and helps to control the progress of caries on the mesial surfaces of permanent first molars.

This study was designed to compare matched pairs of permanent first molars. It is well known that even in nonfluoridated communities caries rates are significantly lower in the 1980s. In this study it was not always possible to select patients who had caries on the distal of a pair of primary second molars. Therefore, teeth were included in the study where only one primary second molar had a carious lesion. The study restoration was placed, and the contralateral tooth designated as the control. The alternative could have been to restore the control side even though caries was not detected.

Human experiment guidelines would not allow such a plan.

In several instances the preventive restoration was placed adjacent to permanent first molars with initial enamel caries on the mesial surface. As shown in Table 4, eight reversals occurred with the study teeth compared to only one on the control teeth. This observation points to perhaps the greatest utility of this preventive restoration. That is, it may be possible to influence the caries progression of an existant carious lesion, and prevent the need for a mesial restoration of a permanent first molar.

Dr. Derkson is an associate professor; Dr. Richardson is a professor, and at the time of writing Dr. Jinks was clinical professor, Dept. of Clinical Dental Sciences, Faculty of Dentistry, the University of British Columbia. At present, Dr. Jinks is a pediatric dentist in private practice. Reprint requests should be sent to Dr. Gary Derkson, Dept. of Clinical Dental Sciences, Faculty of Dentistry, the University of British Columbia, 2199 Wesbrook Mall, Vancouver, BC V6T 1Z7 Canada.

Clark DC et al: The final results of the Sherbrooke-Lac Megantic fluoride varnish study. *J Can Dent Assoc* 12:919-22, 1987.

Corpron RE et al: *In vivo* remineralization of artificial enamel lesions by a fluoride dentifrice or mouthrinse. *Caries Res* 20:48-55, 1986.

Dahl BL et al: Biological tests of a silicophosphate cement. *J Oral Rehabil* 2:249-57, 1975.

Dawson LR et al: Use of amalgam and stainless steel restorations for primary molars. *ASDC J Dent Child* 48:420-22, 1981.

Derkson GD et al: Fluoride release from a silicophosphate cement with added fluoride. *J Dent Res* 61:660-64, 1982.

Duxbury JT et al: Differences in caries levels in 5-year-old children in Newcastle and North Manchester in 1985. *Br Dent J* 162:457-58.

Fejerskov O et al: Combined effects of systemic and topical fluoride treatments on human deciduous teeth—case studies. *Caries Res* 21:452-59, 1987.

Forsten L et al: Fluoride uptake from restorative dental materials by human enamel. *Scand J Dent Res* 84:391-95, 1976.

Glass RL: Fluoride dentifrices: the basis for the decline in caries prevalence. *J R Soc Med* 79(Suppl. No. 14):15-17, 1986.

Goorhuis J, Purdell-Lewis DJ: 0.25% and 0.4% amine fluoride gel for weekly topical application: an *in vivo* study on human dental enamel. *Caries Res* 20:458-64, 1986.

Hanes CM, Hanes PJ: Effective delivery systems for prolonged fluoride release: review of literature. *J Am Dent Assoc* 113:431-36, 1986.

Hunt, PR: A modified Class II cavity preparation for glass ionomer restorative materials. *Quintessence Int* 10:1011-18, 1984.

Jinks GM: Fluoride-impregnated cements and their effects on the activity of interproximal caries. *ASDC J Dent Child* 30:87-92, 1963.

Kuhn AT et al: Dissolution rates of silicate cements. *Biomaterials* 3:136-44, 1982.

Phillips RW et al: In vivo disintegration of luting cements. *J Am Dent Assoc* 114:489-92, 1987.

Meryon SD, Browne RM: Evaluation of the cytotoxicity of four dental materials in vitro assessed by cell viability and enzyme cytochemistry. *J Oral Rehabil* 10:362-72, 1983.

Siegel S: *Nonparametric Statistics for the Behavioural Sciences*. New York: McGraw-Hill, 1956, pp 68-75.

Mirth DB et al: Inhibition of experimental dental caries using an intraoral fluoride-releasing device. *J Am Dent Assoc* 107:55-58, 1983.

Silverstone LM: Remineralization phenomenon. *Caries Res* II (Suppl. No.1) 59-84, 1977.

Skartveit L et al: Clinical assessment of a fluoride-containing amalgam in vivo. *Scand J Dent Res* 93:448-52, 1985.

Full text of AIDS, HIV policy statement

The dental profession in the United States has a long tradition of providing appropriate and compassionate care to the public, including special groups with special needs.

The American Dental Association believes that it has the responsibility to articulate a clear position on issues related to acquired immune deficiency syndrome (AIDS) and human immunodeficiency virus (HIV) infection and to formulate policy based on current scientific knowledge and accepted legal, moral, and ethical imperatives.

This policy statement will be reviewed on a regular basis and may be modified as new information and developments become available.

- **National Policy**—The Association is supportive of initiatives to develop a national policy on HIV infection that can become the basis for coordinated efforts by the public and private sectors. The oral health aspects of HIV infection and issues related to the practice of dentistry should be included in national policies as they are developed.

- **Legal Issues**—Antidiscrimination laws and regulations should be clarified or amended, either legislatively or through the courts, in consideration of the rights of the patient to be free from acts of prejudice and the rights of others to be protected against an unreasonable risk of disease.

- **Public Information**—The healthcare and communications communities should work together, in consultation with government agencies, to develop public service announcements and other educational messages regarding AIDS. Public education to increase awareness of how AIDS is transmitted should include information that will diminish irrational fears about transmission of the disease through dental treatment.

- **Professional Considerations**—The Association believes that HIV-infected individuals should be treated with compassion and dignity. Current scientific and epidemiologic evidence indicates that there is little risk of transmission of infectious diseases through dental treatment *if recommended infection control procedures are routinely followed*. Patients with HIV infection may be safely treated in private dental offices when appropriate infection control procedures are employed. Such infection control procedures provide protection both for patients and for dental personnel.

A sound approach to the treatment of infectious patients requires an assessment of the patient's condition based on reasonable and informed medical judgments, given the state of medical knowledge at the time. Informed and sensitive referrals to environments equipped to serve medically compromised patients may be advisable in some instances.

Dentists should be alert to signs and symptoms of HIV infection that may be identified during the provision of dental care. Patients with histories or conditions possibly indicative of HIV infection should be referred to their physicians for diagnostic procedures, counseling, and medical follow-up. The referring dentists should be notified of test results and should protect the confidentiality of such information.

The Association believes that individuals with HIV infection should have access to dental treatment, and that treatment considerations should provide for a judicious balance between the well-being of these patients and the protection of the health of the public as well as the dental care providers.

ADA News, November 2, 1987