
Class IV preparation design for microfilled and macrofilled composite resin

Kevin J. Donly, DDS, MS Randall Browning, DDS

Abstract

The current standard preparation for Class IV composite restorations is the placement of a bevel on all enamel margins. This study evaluated chamfered and beveled preparations for Class IV restorations of lesions with microfilled and macrofilled composite resin. Forty incisors were obtained and standardized lesions for Class IV restorations were formed. Twenty teeth had a 1.5-mm bevel placed and 20 had a 1.5-mm chamfered preparation placed. Half of the beveled and chamfered preparations were restored with microfilled composite resin; the remaining were restored with macrofilled composite resin. All restorations were fractured with an Instron Testing Machine. The mean force (lbs \pm SD) to fracture the restorations were: (beveled, microfilled composite 16.0 \pm 4.4); (chamfered, microfilled composite 30.6 \pm 20.0); (beveled, macrofilled composite 34.9 \pm 18.6); (chamfered, macrofilled composite 48.8 \pm 14.3). The chamfered preparations provided greater restoration fracture resistance than beveled preparations, for both microfilled and macrofilled composite restorations. Scheffe's test indicated traditional beveled, microfilled Class IV composite resin restorations significantly decreased fracture resistance compared to chamfered, macrofilled composite restorations ($P < 0.001$). (Pediatr Dent 14:34-36, 1992)

Introduction

Composite resin has become an integral part of contemporary restorative dentistry. Due to improvements in materials, conservative concepts in restorative dentistry, and clinical successes, composite resin has become the material of choice for Class IV restorations.

Microfilled composite resin traditionally has been recommended for anterior restorations because of the high luster when polished.¹ The low filler particle percentage of microfilled resins gives a translucent appearance following restoration completion; the outline of the restoration can be apparent.² To aid in camouflaging this effect, opaquers were developed, but they often created an artificial opaque image, making it difficult to obtain a natural tooth appearance. Another concern associated with microfilled composite resin, as a Class IV restorative material, is the secondary fracture potential. When the shear fracture strength of composite resin to etched enamel was evaluated, fracture was found to occur within the composite itself.^{3, 4}

To increase restoration fracture resistance, posterior composite resins have been recommended for anterior restorations.⁵ Although the posterior composite resin cannot be polished quite as well as a microfilled resin, the wetting effect of saliva makes this concern clinically insignificant. The high filler loading by weight (75%) of macrofilled composites, compared to 50% for microfilled composites, increases the strength of the material and decreases the translucency.^{2, 6-8}

As the restorative material strength increases, an appropriate preparation design must be evaluated. One might expect that a traditional cavosurface bevel preparation, the current standard Class IV preparation,^{9, 10}

would not provide sufficient resin/tooth interface strength to match the increased durability of the composite resin. A chamfer preparation has been recommended for composite restorations.^{5, 11} Marzouk and Bhajji found a hollow ground bevel cavosurface enamel margin (which resembles a chamfer) to be more effective in preventing microleakage in Class V restorations than a long or short beveled preparation.¹² Perhaps this preparation will provide additional fracture resistance as stronger and higher filler loaded composite resins become more prevalent in contemporary restorative dentistry.

The purpose of this study was to compare the Class IV restoration fracture resistance of microfilled and macrofilled composite resin, using beveled or chamfered preparation designs.

Materials and Methods

Forty permanent incisors were obtained and stored in sterile saline. The teeth were mounted in 2.5 cm retention tubes with acrylic, then standardized artificial Class IV restoration preparations were made. Twenty of these teeth had a 1.5-mm bevel placed on the enamel margins (Fig 1, next page), while the remaining 20 teeth had a 1.5-mm chamfer placed on the enamel margins (Fig 2, next page). The enamel margins were acid-etched with 35% phosphoric acid gel (Atzgel®/Etching Gel, ESPE-Premier, Norristown, PA) for 60 sec, then thoroughly rinsed with water. An unfilled resin (Visio® Bond, ESPE-Premier, Norristown, PA) was placed and polymerized (Prema Light®, ESPE-Premier, Norristown, PA) for 20 sec. Half of the beveled and chamfered

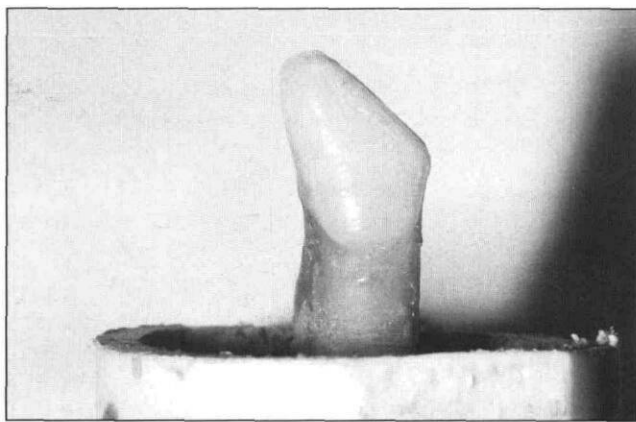


Fig. 1. An example of a 1.5-mm bevel preparation.

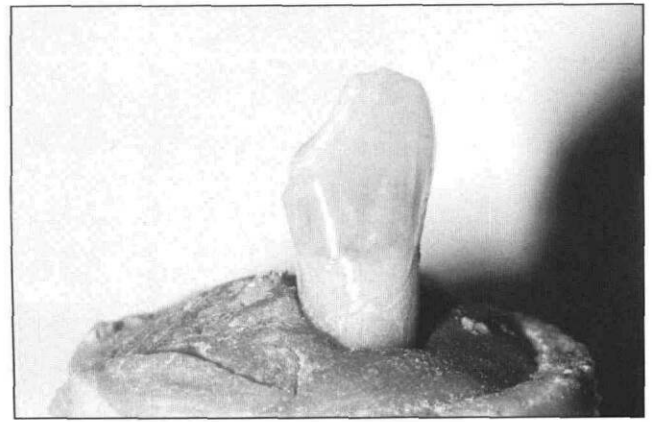


Fig. 2. An example of a 1.5-mm chamfer preparation.

preparations were restored with a microfilled composite resin (Visio[®] Dispers, ESPE-Premier, Norristown, PA). The remaining samples were restored with a macrofilled composite resin (Visio[®] Molar, ESPE-Premier, Norristown, PA).

The restored teeth were stored in a humidified environment for 24 hr, then all restorations were fractured with an Instron Testing Machine (Instron[®] Testing Machine, Instron Engineering Corp., Canton, MA). All data were recorded and the specific fracture site location was identified.

Results

The mean force (lbs \pm SD) to fracture the restorations was: 16.0 \pm 4.4 (beveled preparations restored with microfilled composite); 30.6 \pm 20.0 (chamfered preparations restored with microfilled composite); 34.9 \pm 18.6 (beveled preparations restored with macrofilled composite); and 48.8 \pm 14.3 (chamfered preparations restored with macrofilled composite resin). The fracture sites of each restoration are presented in the Table. The chamfered preparations provided greater restoration fracture resistance than beveled preparations, for both microfilled and macrofilled composite restorations. An analysis of variance (ANOVA) was calculated, using a randomized block design for data evaluation. ANOVA demonstrated statistical significance at $P < 0.001$. A Scheffe's test indicated that traditional beveled, microfilled composite resin restorations significantly decreased fracture resistance compared to chamfered, macrofilled composite resin restorations ($P < 0.001$). The chamfered, microfilled composite resin restorations also demonstrated less fracture resistance than chamfered macrofilled restorations ($P < 0.1$) and the beveled, microfilled composite restorations showed less fracture resistance than beveled, macrofilled restorations ($P < 0.1$).

Table. The fracture of composite resins

	Fracture Site		Mean Fracture Force (Lbs \pm SD)
	Within Resin	Within Enamel	
Bevel/microfill	6	4	16.0 \pm 4.4
Chamfer/microfill	8	2	30.6 20.0
Bevel/macrofill	2	8	34.9 18.6
Chamfer/macrofill	7	3	48.8 \pm 14.3

Discussion

The chamfered preparations provided greater restoration fracture resistance than beveled preparations for both microfilled and macrofilled composite restorations. Restorations with a chamfered preparation margin might be expected to have greater fracture resistance due to the larger volume of composite resin available at the restoration margin. The chamfer would allow a "bulk" of composite resin to be present at the restoration/tooth surface interface, thereby decreasing the probability of fracture within the bond site of the restoration. Previous studies have indicated that often, the fracture of a composite resin restoration is caused by failure within the resin itself, rather than at the etched enamel bond site.^{3, 4} We obtained the same results. Seventy per cent of the microfilled composite restorations fractured within the composite resin.

It is possible that the bulk of composite resin at a chamfered margin may not blend in color match with the natural tooth as well as a beveled margin. Should this become a factor in esthetics, the chamfered margin can have a bevel placed at the gingival seat, similar to a porcelain-fused-to-metal crown preparation described by Shillingburg et al.¹³ This may allow the composite resin restoration have a better color match.

Dr. Donly is an associate professor in the Center for Clinical Studies and the Department of Pediatric Dentistry, University of Iowa College of Dentistry, Iowa City, IA. Dr. Browning is in private practice in pediatric dentistry, Amarillo, TX.

1. Vanherle G, Lambrechts P, Braem M: Overview of the clinical requirements for posterior composites. In International Symposium on Posterior Composite Resin Dental Restorative Materials. G Vanherle, DC Smith eds. Minneapolis: 3M Co, 1985, pp 21-40.
2. Jordan RE, Suzuki M, Boksman L, Skinner DF: Labial resin veneer restorations using visible light cured composite materials. *Alpha Omegan* 74:30-39, 1981.
3. Boyer DB, Chan KC, Torney DL: The strength of multilayer and repaired composite resin. *J Prosthet Dent* 39:63-67, 1978.
4. Chan KC, Boyer DB: Repair of conventional and microfilled composite resins. *J Prosthet Dent* 50:345-50, 1983.
5. Donly KJ: Posterior composite resin: use for anterior restorations. *J Dent Child* 5:260-62, 1990.
6. Söderholm KJM: Filler systems and resin interface. In International Symposium on Posterior Composite Resin Dental Restorative Materials. G Vanherle, DC Smith eds. Minneapolis: 3M Co, 1985, pp 139-59.
7. Smith DC, Pilliar RM, Maric B: Fracture toughness and in-vitro wear characteristics of dental composite resins. *J Dent Res* 62:646 (Abstr S16), 1983.
8. Lloyd CH, Mitchell L: The fracture toughness of tooth coloured restorative materials. *J Oral Rehabil* 11:257-272, 1984.
9. Sockwell CL, Heymann HO: Tooth-colored restorations. In *The Art and Science of Operative Dentistry*. 2nd ed, CM Sturdevant ed. St. Louis: CV Mosby Co, 1985, pp 292-95.
10. Reinhardt JW: Esthetic restorative dentistry for the adolescent. In: *Pediatric Dentistry — Infancy Through Adolescence*. JR Pinkham ed. Philadelphia: WB Saunders Co., 1988, pp 487-88.
11. Jordan RE, Suzuki M, Gwinnett AJ, Hunter JK: Restoration of fractured and hypoplastic incisors by the acid etch resin technique: a three year report. *J Am Dent Assoc* 95:795-803, 1977.
12. Marzouk MA, Bhaiji AHF: Influence of enamel cavosurface configuration on marginal leakage in Class V composite resin restorations. *Am J Dent* 2:165-69, 1989.
13. Shillingburg HT, Hobo S, Whitsett LD: Preparations for porcelain fused to metal crowns. In: *Fundamentals of Fixed Prosthodontics*. Chicago: Quintessence Publishing Co., Inc., 1978, pp 103-11.

Denial of care rarely is justified

Physicians may, in limited situations, deny treatment to difficult, noncompliant patients, according to an article published in the *Journal of the American Medical Association*. Though patients must assume a share of the responsibility for their health care, disagreement exists on whether a patient can be denied medical treatment because of noncompliant behavior, according to David J. Orentlicher, MD, JD, ethics and health policy counsel in the AMA's Office of the General Counsel. The views in the article are Orentlicher's; they do not represent AMA policy.

In the past, courts have found for the physician in cases in which a patient was seriously noncompliant, disruptive of other patients' care, and abusive of staff. However, the 1990 Americans With Disabilities Act may limit physicians' choices to deny a patient treatment because of the patient's noncompliant behavior. "If a patient's noncompliance reflects psychiatric dysfunction, then a denial of treatment because of the noncompliance would in effect be a denial of treatment based on a psychological disorder." Under the Disabilities Act, such a denial apparently would be prohibited.

However, health care providers may invoke a necessity defense if they can demonstrate that the behavior of a difficult, noncompliant patient makes it impossible to provide appropriate care to other patients, even after reasonable attempts to accommodate the particular patient, Orentlicher noted. "To ensure that the Disabilities Act fully realizes its goal of protecting the disabled, courts should construe the necessity defense narrowly. A disruptive patient may be very difficult to take care of, but often the disruptiveness is a product of the patient's illness."

He indicated that there is a difference between a disruptive, willfully noncompliant patient and a patient whose informed care choice differs from the physician's recommendation. To deny treatment in the latter case "would effectively vitiate the patient's right to refuse medical care...If a physician could respond to a patient's refusal of some treatment recommendations by denying treatment altogether, then patients would have little choice in their care."