

Odontoma attached to an unerupted maxillary central incisor

Franka C. Dubbelman-Falcon, DMD
Edward M. Sonnenberg, DDS
David Goteiner, DDS

Abstract

Clinical and roentgenographic examination revealed an odontoma on the mesial aspect of an impacted maxillary incisor in an eight-year-old black male with an unerupted maxillary central incisor. An attached compound odontoma was surgically excised and after seven months, the impacted central incisor had not erupted. Orthodontic treatment was initiated but, as movement occurred, a second surgical procedure was required to restore the maxillary central incisor. A small portion of the odontoma remained and prevented proper eruption and alignment. Classification, diagnosis, and treatment of odontomas are reviewed.

Odontomas, slow-growing asymptomatic neoplasms, represent 22% of the odontogenic tumors found in jaws.¹ Odontomas are tumors that develop from epithelial and mesenchymal components of the dental apparatus, producing enamel and dentin.² They can occur anywhere in the mandible or maxilla without apparent predilection for age or sex, although they usually are found in conjunction with primary teeth. Odontomas frequently can inhibit the eruption of adjacent teeth.³

Odontomas are classified as complex, compound, and cystic. Complex odontomas appear on roentgenographs as irregular calcified masses that bear no similarity to teeth. They are more commonly seen in the molar region. The compound odontoma represents 60% of all odontomas. They have a highly differentiated enamel and dentin laid down in an orderly fashion and, therefore, can resemble normally developed teeth. The majority occur in the incisor-cuspid region with a tendency to occur more frequently in the maxilla.⁴ A cystic odontoma or odontodentigerous cyst appears as a calcified mass within a dentigerous cyst that surrounds the crown of a mature but unerupted permanent tooth.⁵ The differential diagnosis of odontoma is made by roentgenographic examination, followed by surgical removal and histological examination.⁶

Treatment of odontomas is by surgical enucleation. This is accomplished easily, since the tumor is generally attached to the surrounding bone by connective tissue only. These lesions do not recur after excision.⁷

The purposes of this paper are to present an atypical odontoma which was fused to a maxillary central incisor and the clinical technic used to treat the lesion.

Case Report

An eight-year-old black male came to the Pedodontic Clinic at the New Jersey Dental School for routine dental care. The medical and dental histories were unremarkable.

Oral examination revealed a mixed dentition with multiple carious lesions, and without a maxillary right central incisor. The vestibular fornix in the area of the unerupted incisor had an asymptomatic expansion of the buccal plate.

An occlusal radiograph showed an impacted maxillary right central incisor (Figure 1). Periapical films indicated a possible odontoma adjacent to the mesial surface of the unerupted tooth. It was not possible to determine from roentgenographs whether the odontoma was totally

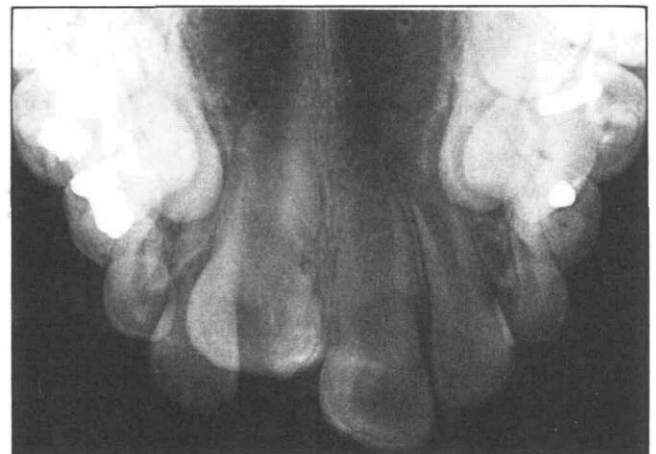

Figure 1. Occlusal radiograph of unerupted incisor.

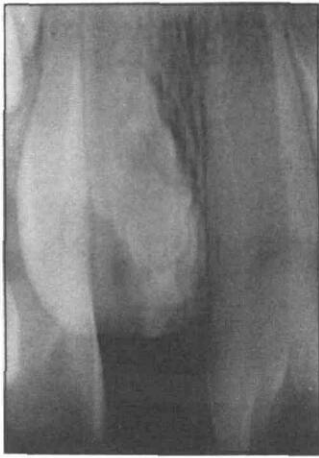

Figure 2. Periapical view of unerupted incisor with radiopaque mass adjacent to crown.

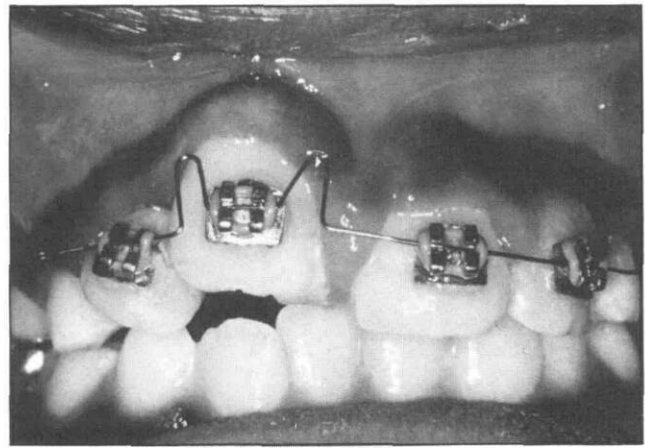


Figure 3. The day of placement of orthodontic appliance.

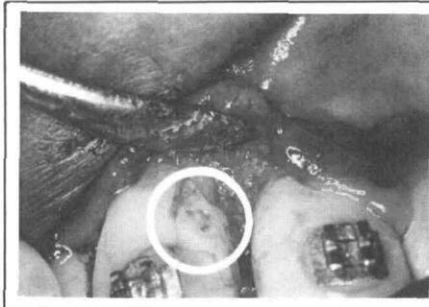
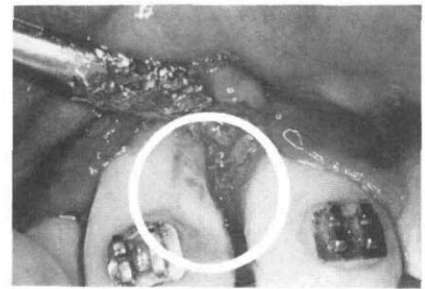


Figure 4 (left). During second showing attached piece of odontoma to tooth.

Figure 5 (right). Reshaped tooth after complete removal of odontoma fragment.



surrounded by connective tissue or fused to the impacted tooth (Figure 2).

Under local anesthesia a mucoperiosteal flap was raised, revealing a calcified lesion fused to the maxillary right central incisor. The mass was removed from the tooth with a bur and placed in 10% formalin. A portion of the buccal plate was removed to facilitate eruption of the impacted tooth. The flap was replaced and sutured, and healing was unremarkable.

The specimen, which measured 1.5x0.8x0.3 cm was determined to be a compound odontoma consisting of carious dentin, enamel, immature connective tissue, epithelial strands, and dense collagen.

The patient was observed for seven months but the surgically exposed tooth did not erupt. Edgewise brackets were bonded to the four maxillary incisors and a 0.012 stainless steel arch wire was inserted to facilitate movement (Figure 3). During forced eruption, the patient experienced sensitivity of the dentin at the site of the excised odontoma. The exposed dentin was covered with calcium hydroxide and a layer of pit and fissure sealant. As the tooth erupted, the bracket was repositioned gingivally to facilitate alignment.

After four more months, it became apparent that proper alignment of the tooth could not be accomplished because a small portion of the odontoma had not been removed from the mesiobuccal line angle of the incisor. A second surgical procedure to remove the remnants of the odontoma was performed using a mucoperiosteal flap on the buccal and palatal sides of the maxillary right central incisor. The remaining attached portion of the

odontoma (Figure 4) was removed with a bur, the tooth reshaped and another layer of sealant applied (Figure 5). The flap was readapted and sutured and healing was unremarkable.

Three months later orthodontic alignment of the tooth was completed (Figures 6 & 7). Retention using a 0.020 stainless steel wire followed for six months. At the completion of treatment, the patient was comfortable, esthetics were acceptable, and the tooth was vital (Figure 8).

Discussion

This case was unusual for two reasons. First, there is usually only connective tissue between odontoma and the adjacent teeth making removal by enucleation relatively easy.² In this case, the odontoma was fused to the permanent central incisor and required surgical separation. Second, when the exposed tooth failed to erupt after seven months, ankylosis was suspected. An attempt to position the tooth orthodontically was only partially successful until a second surgical procedure was performed. This procedure was necessary to remove a small amount of remaining odontoma which prevented complete eruption of the incisor.

We recommend that a periapical radiograph be taken during the surgical phase of treatment to ensure complete removal of the odontoma fused directly to the tooth. Although it is advisable to keep radiation exposure to a minimum, the radiograph may prevent future surgical intervention. The surgical sites may fill with blood making visualization of the area difficult and part of the

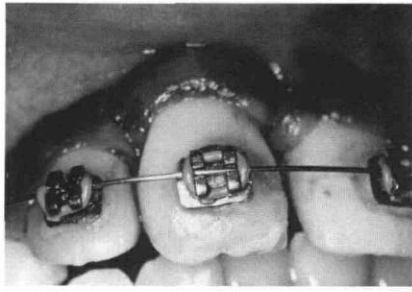
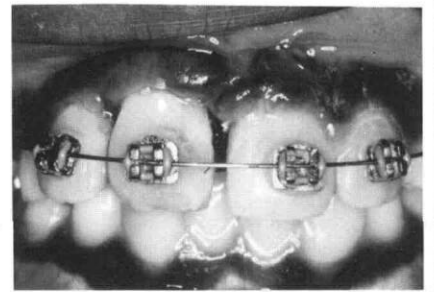


Figure 6. Closeup of repositioned tooth before removal of appliance.

Figure 7. General view of repositioned tooth before removal of appliance.



odontoma could remain. In this particular case, additional roentgenographs would have prevented the delay in orthodontic movement and the second surgery.

Conclusion

If enucleation is a satisfactory means of removing an odontoma, routine surgical and postsurgical procedures can be followed. If an odontoma is found to be attached to an adjacent tooth, a periapical radiograph during the surgical phase is advisable since surgical sites can be obscured and the attachment may extend farther than first imagined. The single additional periapical radiograph should prove preventive, i.e., preventing additional surgery and/or extended orthodontic treatment.

We wish to thank Mr. Joshua Johnson, Ms. Lois Massenberg, and Ms. Felicia M. Capuno for their help in preparing this manuscript.

Dr. Dubbelman-Falcon was an undergraduate student at the time of this study, Dr. Sonnenberg is clinical associate professor, and Dr. Goteiner is clinical associate professor, UMD-New Jersey Dental School, 100 Bergen St., Newark, NJ 07103. Requests for reprints should be sent to Dr. Sonnenberg.

1. Bhaskar, S.N. Oral pathology in the dental office: survey of 20,575 biopsy specimens. *JADA* 76:761-766, 1968.
2. Shafer, W.G., Hine, M.H., and Levy, B.M. *A Textbook of Oral Pathology*, 3rd ed. Philadelphia, W. B. Saunders Co., 1974, pp 276-278.
3. Baden, E. Odontogenic tumors. *Pathology Annual* 6:475-568, 1971.
4. Zegarelli, E.V., Kutscher, A.H., and Hyman, G.A. *Diagnosing Diseases of the Mouth and Jaws*, 2nd ed. Lea & Febiger, Philadelphia, 1978, pp 232-235.
5. Gorlin, R.J. and Goldman, H.M. *Thomas' Oral Pathology*, 6th ed., St. Louis, C.V. Mosby Co., 1970, pp 481-515.
6. Barr, G.S., Zweig, B., and Lapeyrolerie, F.M. Compound composite odontoma. *J New Jersey Dent Assoc* 27-30, Fall 1973.
7. Ridley, M.T., Jones, R.S., and Ingraham, G.B. Odontoma compound and complex: a case report of each. *J Kentucky Dent Assoc* 19-20, April 1979.

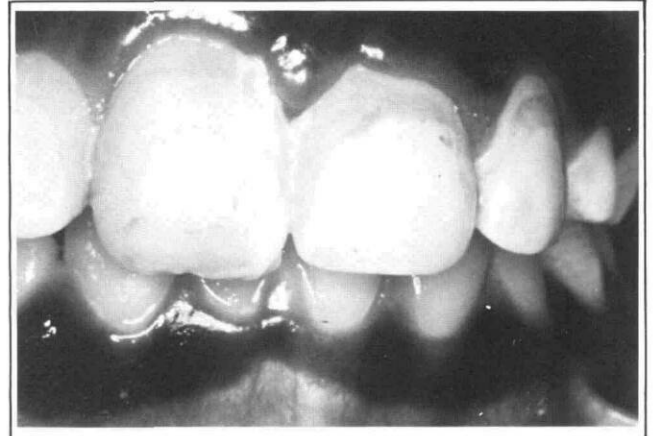

Figure 8. Repositioned tooth six months after appliance was removed (note marginal inflammation and plaque accumulation).

8. Wright, G. Z., Coleleugh, R. G., and Davidge, L. K. Electrical burns to the commissure of the lips. *J Dent Child* 44:377-381, 1977.
9. Coleleugh, R. G. and Ryan, J. E. Splinting electrical burns of the mouths in children. *Plast Reconstr Surg* 58:239-241, 1976.
10. Larson, T. H. Splinting oral electrical burns: report of two cases. *J Dent Child* 44:382-384, 1977.
11. Richardson, D. S. and Kittle, P. E. Extraoral management of a lip commissure burn. *J Dent Child* 48:352-356, 1981.
12. Goldberg, M. H. Electrical trauma to the oral cavity. *J Oral Surg* 27:190-193, 1969.
13. *Accepted Dental Therapeutics*, Chicago, American Dental Association, 1979, pp 192-193, 210.
14. Gormley, M. B., Marshall, J., Jarrett, W., and Bromberg, B. Thermal trauma: a review of 22 electrical burns of the lip. *J Oral Surg* 30:531-533, 1972.
15. Feign, R. D. *Nelson Textbook of Pediatrics*. Philadelphia, W.B. Saunders Co., 1979, pp 752-757.
16. Ryan, J. E. Prosthetic treatment for electrical burns to the oral cavity. *J Prosthet Dent* 42:434-435, 1979.