
A clinical study of ferric sulfate as a pulpotomy agent in primary teeth

Ay-Luen Fei, BDS, MS Richard D. Udin, DDS
Ronald Johnson, DDS

SCIENTIFIC ARTICLES

Abstract

Pulpotomies were performed on 83 primary molars in 62 patients. Ferric sulfate or formocresol was placed on the pulpal stumps, and teeth were followed for 3-, 6-, and 12-month periods. After the one-year follow-up, 28 of 29 teeth treated with ferric sulfate (FS group) were considered successful and 21 of 27 teeth treated with formocresol (FC group) were judged to be successful. The FS group demonstrated greater combined clinical and radiographic success than the FC group at the one-year recall ($P < 0.05$). Although the results of this study are promising, further study with longer observation periods is warranted before this technique can be recommended. (Pediatr Dent 13:327-32, 1991)

Introduction

The pulpotomy preserves the remaining vital portion of cariously exposed pulpal tissue. Formocresol was introduced in the United States by Buckley in 1904 and is the most widely used pulpotomy material in North America (Avram and Pulver 1989). Studies have shown formocresol therapy to have a success rate between 70 and 90% (Wright and Widmer 1979). Histologic results have been variable in contrast to the high clinical success rate. Instead of preserving vital pulpal tissue, chronic inflammation and necrotic tissue were found (Rølling and Lambjerg-Hansen 1978). Another problem with formocresol is its systemic distribution from the pulpotomy site (Myers et al. 1978). Pruhs et al. (1977) found a relationship between primary teeth treated with formocresol and enamel defects in the permanent successors. This relationship was not found by Rølling and Poulsen (1978). The allergenic and mutagenic properties of formaldehyde have been demonstrated in animal models, but not in humans (Judd and Kenny 1987). An alternative to the use of this medicament which does not elicit the same systemic and local problems would be desirable.

Glutaraldehyde and calcium hydroxide have been tested in pulpotomies in primary teeth. Electrosurgery and CO₂ laser also have been used. Clinical studies using a 2% glutaraldehyde solution generally have yielded favorable results. Prakash et al. (1989) and García-Godoy (1986) reported 100% success after 6 months and 98% success after 19-42 months, respectively. Fuks et al. (1986; 1990) reported an initial clinical and radiographic success of 94% after six months which subsequently decreased to 90% at one year and 82% after two years.

Studies investigating the use of electrosurgical pulpotomies have yielded variable findings. Ruemping et al. (1983) and Shaw et al. (1987) demonstrated favor-

able histologic results in primates, while Shulman et al. (1987) noted pathologic root resorption and periapical/furcal pathology. Interpreting the results of these studies is difficult because of differences in techniques and electrical currents used. Lasers also have been tested in pulp therapy. A carbon dioxide laser caused no immediate pulpal damage following pulpotomies in mongrel dogs (Shoji et al. 1985). Much more research is needed to determine effectiveness, as well as the type of laser best suited and most cost-effective for this technique.

When calcium hydroxide was used as a pulpal dressing, the success rate, as estimated from radiographs, seldom exceeded 60% (Magnusson 1970; Schröder 1978) with extensive internal resorption below the amputation level as the most frequent complication (Schröder 1978). According to Schröder (1978) the lack of adequate hemostasis before placement of the medicament adversely affected the treatment outcome. A blood clot on the wound surface lowered the frequency of histologically complete healing.

The success of a pulpotomy may be increased by promoting hemostasis of the remaining pulpal tissue. Heilig et al. (1984) studied the use of aluminum chloride on pulpal tissues before calcium hydroxide placement. A more rapid reduction in pulpal hemorrhage and attainment of hemostasis was observed when aluminum chloride, rather than sterile water control, was used. After 9 months, the aluminum chloride-calcium hydroxide group presented a more favorable result radiographically than the control, but samples were small.

Ferric sulfate (Fe₂[SO₄]₃) is used for gingival retraction before impression taking and in endodontic surgery for hemorrhage control (Christensen and Christensen 1979). In contact with blood, a ferric ion-protein complex is formed and the membrane of this

complex seals the cut blood vessels mechanically, producing hemostasis (Fischer 1981; 1987). Another form of this agent, ferric subsulfate (Monsel's solution, $\text{Fe}_4[\text{OH}]_2[\text{SO}_4]_5$), has been used widely in skin and mucosal biopsies as a hemostatic agent (Epstein and Maibach 1964). Ferric subsulfate is successful in controlling hemorrhage, but has pigmentary, degenerative, and reactive changes following its use during skin biopsies (Amazon et al. 1980; Olmstead et al. 1980). Shaw et al. (1983) also found reversible damage to the connective tissue adjacent to the sulcular gingiva after application of ferric sulfate.

Landau and Johnsen (1988) used ferric sulfate to control pulpal hemorrhage before applying calcium hydroxide to pulpotomized monkey teeth. After seven days, both groups had slight inflammatory changes, and after 60 days a better pulpal response was found in teeth treated with ferric sulfate than in the control. No mummification was seen in any of the pulpotomized tissues because ferric sulfate is not a fixative agent as is formocresol. The hemostatic properties of ferric sulfate and the favorable pulpal response make it a promising medicament for pulpotomy.

Controlling pulpal hemorrhage with ferric sulfate may prevent the problems previously encountered due to clot formation, thereby minimizing the chances for inflammation and internal resorption of the remaining pulpal tissue. The purpose of this study was to compare the clinical and radiographic success of ferric sulfate and formocresol as pulpotomy medicaments.

Materials and Methods

Subjects were selected from the patient population of the Pediatric Dental Clinic at the University of Southern California School of Dentistry. Parents were informed of the study and appropriate consent was obtained. Teeth were selected according to the following clinical criteria: 1) absence of excessive tooth mobility; 2) absence of tenderness to percussion; 3) absence of fistulation; and 4) absence of gross caries or coronal destruction that would preclude restorability. Teeth also met the following radiographic criteria: 1) carious exposure of the pulp; 2) no internal or external resorption; 3) no calcific pulpal degeneration; and 4) no intraradicular or periapical radiolucency. Sixty-two patients ranged in age from 3 years 2 months to 10 years 1 month (mean age: 6 years 7 months). Thirty-seven males and 25 females contributed 83 primary molars (31 maxillary teeth and 52 mandibular teeth) requiring pulpotomy. Teeth were assigned according to a table of random numbers to one of two groups: formocresol (FC group) or ferric sulfate (FS group). A subject with more than one tooth requiring pulpotomy had each tooth randomly assigned to one of the two groups. Fifty-six

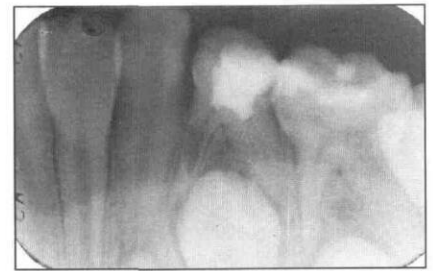
teeth from 48 patients (FC group: 27 teeth; FS group: 29 teeth) were available for evaluation after one year.

The pulpotomy procedure used administration of local anesthetic and isolation of the tooth with a rubber dam. Dental caries was excavated and if a carious pulpal exposure was evident, a sterile #330 high-speed bur (under continuous water irrigation) was used to unroof the pulpal chamber. Coronal pulpal tissue then was removed using a sterile slow speed round bur (#6 or 8) or sterile sharp spoon excavator. After pulpal hemorrhage was assessed, gross hemorrhage control was achieved using dry sterile cotton pellets. In the experimental group, 15.5% ferric sulfate (Astringent™, Ultradent Products, Inc. Salt Lake City, UT) was applied to the pulpal stumps by gently touching the stumps with the applicator ("Dento-infusor") supplied by the manufacturer. Hemorrhage control was assessed and reapplication of the ferric sulfate was accomplished if bleeding did not cease. Following the second application, if hemorrhage persisted, a pulpectomy was completed and the tooth was eliminated from the study. For the formocresol pulpotomy technique, a sterile cotton pellet moistened with 1:5 diluted Buckley's formocresol (Sultan Chemists Inc, Englewood, NJ) was placed against the pulpal stumps for 5 min. If hemorrhage was not controlled, the pulpal stumps were checked and the pulp chamber was cleansed and rinsed followed by a second application of formocresol. If hemorrhage persisted, a pulpectomy was completed and the tooth was eliminated from the study. A zinc oxide and eugenol (ZOE) base was placed over the pulpal stumps of teeth assigned to both groups followed by IRM (Intermediate Restorative Material: LD Caulk Division, Milford, DE) to provide a harder surface. The tooth then was restored with a stainless steel crown.

Clinical and radiographic evaluations of the teeth were conducted at 3-, 6- and 12-month intervals by two independent examiners who had no knowledge of the group to which the particular tooth was assigned. Before grading the X-ray films, the examiners were asked to evaluate 14 posterior periapical radiographs not included in the study to establish a consensus. Teeth were judged clinical successes if they had no symptoms of pain or tenderness to percussion, swelling or fistulation, or pathologic tooth mobility. Radiographic success required a normal periodontal ligament, absence of pathologic internal or external root resorption, and no intraradicular or periapical radiolucency. At the time of evaluation, examiners determined whether external resorption was pathologic or physiologic. If the examiners disagreed, the poorest outcome was chosen. The overall success of the treatment was assessed according to both clinical and radiographic findings. If either was determined to be a failure, treatment was judged to have failed.

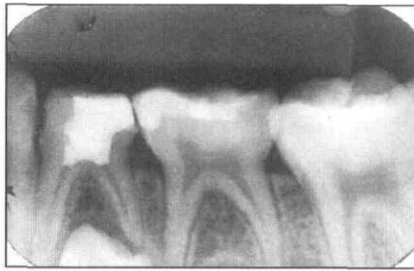

Fig 1. Radiographic failure of first primary molar treated with formocresol due to internal resorption. Preoperative radiograph (1a, left). Radiograph at 3-month postoperative period with internal resorption within the mesial root canal (1b).



Statistical Analysis

The Kappa statistic was used to test the reproducibility of the scoring by examiners. Clinical and radiographic success of the two treatment regimens at each recall visit was analyzed separately by Fisher's exact test.

The number of teeth judged to have treatment failures at the three recall visits was compared by using the matched multisample comparison test. Only the subjects who completed all three recall visits were included in the test so that the significance of the differences of failures among the three recall visits could be evaluated.

Calcification of root canals in both FS and FC groups were analyzed by Chi-square test to determine whether any differences existed.

Results

The Kappa statistic indicated highly significant reproducibility between the two examiners ($P < 0.001$).

Clinical Results (Table 1)

All teeth in the FS group were judged to be successful (success rate 100%) and one tooth out of 27 teeth in the FC group was judged to have failed after one year (success rate 96.3%). No significant difference was found between these two groups ($P > 0.1$) at the 12-month recall, nor between the two groups at the 3- and 6-month recall visits ($P = 1.0$).

Radiographic Results (Table 2)

There was no significant difference between the FC and FS group at any of the recall visits ($P > 0.05$). One tooth judged to be a failure at the 3- and 6-month recall periods was not available at the 12-month recall, and was still considered a failure. Radiographic failure following treatment with formocresol is shown in Fig 1.

Overall Results (Table 3)

Combining the clinical and radiographic results in the 3- and 6-month recall periods, there were no significant differences between the two treatment groups ($P > 0.1$). At the one-year recall, 28 of 29 teeth in the FS group

were considered clinic and radiographic successes, but in the FC group, 21 of 27 teeth were considered successfully treated. A significant difference between the combined clinical-radiographic results of these two groups

Table 1. Clinical evaluation of FS & FC pulpotomies at recall

	3 months		6 months		12 months	
	Success	Fail	Success	Fail	Success	Fail
FS	26	0	27	0	28	0
FC	23	0	24	0	26	1
	$P = 1.0$		$P = 1.0$		$P = 0.491$	

Test was performed at 5% significance level.

Table 2. Radiographic evaluation of FS & FC pulpotomies at recall

	3 months		6 months		12 months	
	Success	Fail	Success	Fail	Success	Fail
FS	25	1	26	1	28*	1
FC	20	3	20	4	22	5
	$P = 0.259$		$P = 0.140$		$P = 0.081$	

Test was performed at 5% significance level.

* One tooth was not available for evaluation at 12 months but was still considered a failure since it had already failed at 3 and 6 months.

Table 3. Overall evaluation of FS & FC pulpotomies at recall

	3 months		6 months		12 months	
	Success	Fail	Success	Fail	Success	Fail
FS	25	1	26	1	28	1
FC	20	3	20	4	21	6†
	$P = 0.259$		$P = 0.140$		$P = 0.041^*$	

Test was performed at 5% significance level.

* Significant difference with $P < 0.05$.

† One tooth was judged to fail clinically but not radiographically.

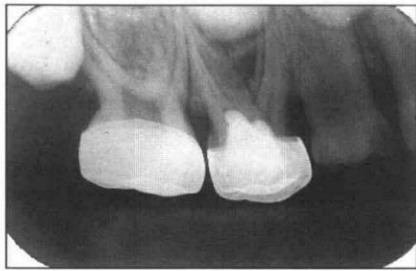
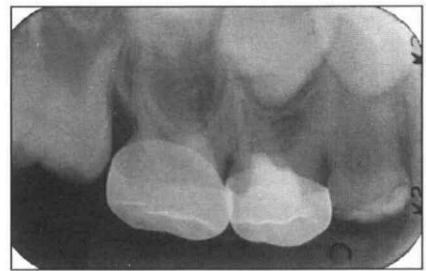

Fig 2. Root canal calcification following treatment with ferric sulfate. Radiograph exposed of first primary molar at 3-month postoperative period (2a, left). Radiograph at 12-month postoperative period with calcification of the mesiobuccal root canal (2b).



was noted after one year ($P < 0.05$). The combined overall success rate of the FS group was 96.6% and the FC group was 77.8%.

Incidence of Failure at Recall

By using the comparison of the three matched samples, there were no significant differences in the time in which treatment was considered to have failed in both the FC group ($P = 1.0$) and FS group ($P > 0.1$). In the FS group, one tooth failed at the 3- and 6-month recall periods but was not available for the 12-month recall. It was still considered to be a failure. In the FC group, two teeth were not available at the 3-month recall but were examined at the 6- and 12-month recall visits, when they were judged to be failures. These two cases were excluded since there was no information regarding the time of failure.

Canal Calcification

In the FS group, internal calcification of the root canals was found in 14 of 29 teeth, while in the FC group there were 12 of 27 teeth with this finding (Fig 2). A Chi-square test did not indicate a significant difference between these two groups ($0.05 < P < 0.1$).

Discussion

An effective pulpotomy medicament must result in clinical and radiographic success and physiologic compatibility between pulp and surrounding tissues. The current study demonstrated that ferric sulfate was clinically and radiographically* successful as a pulpotomy medicament in primary teeth. At the one-year recall, the success rate of the FS group was actually greater than that of the traditional FC pulpotomy group ($P < 0.05$), when both clinical and radiographic success were combined. It was interesting to note that the success rate of the FC group was 77.8%, somewhat lower than reported previously (Morawa et al. 1975; Fuks and Bimstein 1981). An explanation for this finding could be related to the small sample size or to operator error, although pulpotomies in both groups were performed by the same operator under rigorous conditions.

The question of histologic response following treatment with ferric sulfate was addressed in an animal study by Landau and Johnsen (1988) in which ferric sulfate was used to control hemorrhage before calcium hydroxide placement. Vital pulpal tissue was found at the apical third of all teeth treated with ferric sulfate after 60 days, compared to four of seven teeth in the sterile water-calcium hydroxide control group. However, the sample sizes were small and the recall period was short. Although the ferric sulfate technique appeared successful histologically, the long-term effect of this drug on the teeth and the rest of the body was not addressed.

Ferric sulfate, unlike formocresol, does not mummify pulpal tissue (Landau and Johnsen 1988). In the current study, ZOE was chosen as the base material to place over the treated pulp stumps so that the experimental technique could be compared more directly with the traditional formocresol pulpotomy technique which also uses ZOE. The use of the zinc oxide and eugenol base may not be an ideal choice, since eugenol irritates pulpal tissue (García-Godoy 1982). Since formocresol is said to "mummify" or fix the coronal tissue in root canals, pulp tissue under this agent may not be affected by the ZOE. García-Godoy found less severe inflammation when ZOE was placed on formocresol-treated pulps than on pulps not treated with a fixative agent (1982). Since ferric sulfate is not a fixative agent, the base in direct contact with the pulpal surface may play an important role in the healing process. Bases which are inert may stimulate pulp cell attachment and provide more rapid and less inflammatory wound healing (Schröder 1985). The possible combination of ferric sulfate with different base materials is certainly worthy of further investigation.

Schröder (1977) reported an 81% agreement between the clinical and histologic diagnoses of chronic coronal pulpitis in carious primary teeth. A tooth may appear to be a good candidate for a pulpotomy clinically, but pulpal inflammation may not be confined to the coronal portion of the pulp, making the tooth a questionable candidate. Because of the fixative properties of

formocresol and the possibility of mummifying a broad zone of the remaining pulpal tissue, a tooth treated with this medicament could still remain clinically successful. Ferric sulfate is a nonfixative, but has bacteriostatic properties and may not act on the underlying inflammatory tissue; thus, it may not be beneficial in a similar situation. In the current study, the most frequent evidence for a particular technique to fail in either group was intraradicular radiolucency. Taking into account the type of failure and the time period in which the failure occurred, improper selection of the teeth initially may have led to these failures.

One tooth in the FC group was considered to have failed clinically due to pain on percussion. The same tooth, however, did not present any radiographic changes throughout the year. Similarly, the teeth which were considered radiographic failures did not present any clinical symptoms and signs through the one year follow-up. Due to the small sample in this study, a difference of one tooth could be significant. Some teeth showed radiographic but not clinical failure. However, if the recall period was continued longer, more cases might start to show clinical failure.

Willard (1976) reported postoperative calcification of root canals as a frequently observed radiographic change (occurring in 24 of 30 teeth in a 3-year period) following formocresol pulpotomies in primary molars. He explained that this calcification may result from odontoblastic activity following treatment, suggesting that the pulp retains some degree of vitality and function. Root canal calcification also had been described by Rølling and Lambjerg-Hansen (1978) as a typical histologic response following formocresol pulpotomy. Fuks and Bimstein (1981) reported this finding in 20 of 70 treated teeth in children. In the present study, the rate of canal calcification was less than 50%, with no significant difference in the rate between the FS and FC groups ($0.05 < P < 0.1$). The etiology for canal calcification is still a matter of speculation.

Despite the promising findings regarding the use of ferric sulfate, there is a need for further study, for example, longer follow-up period and greater numbers of teeth treated with ferric sulfate to determine the long term effects on primary teeth. Different base materials should be tested following pulpotomy with ferric sulfate to determine the corresponding pulpal reaction. Additional histologic studies are needed to determine pulpal response to this material. Studies should determine the potential effects on underlying permanent teeth and the nature of any absorption and systemic distribution of ferric sulfate from pulpal tissues.

The authors thank Dr. V. Kipnis for his assistance with the statistical analysis.

The ferric sulfate tested in this study was provided by the Ultradent Company.

The procedure's possible discomforts or risks as well as possible benefits were explained fully to the human subjects involved and their informed consent was obtained prior to the investigation. The protocol for this study was approved by the Institutional Review Board for the Protection of Human Subjects, University of Southern California (#05670).

Dr. Fei is a former resident, Dr. Udin is assistant professor and director of Pediatric Dentistry Residency Program, and Dr. Johnson is professor and chairman, Pediatric Dentistry, University of Southern California, Los Angeles, CA.

- Amazon K et al: Ferrugination caused by Monsel's solution, Clinical observation and experimentations. *Am J Dermatopathol* 2:197-205, 1980.
- Avram DC, Pulver F: Pulpotomy medicaments for vital primary teeth. Surveys to determine use and attitudes in pediatric dental practice and in dental schools throughout the world. *ASDC J Dent Child* 56:426-34, 1989.
- Christensen GJ and Christensen R: Astringedent by Ultradent. *Clin Res Assoc Newsletter* 3:2, 1979.
- Epstein E, Maibach HI: Monsel's solution. History, chemistry, and efficacy. *Arch of Dermatol* 90:226-28, 1964.
- Fischer DE: Tissue management for making impressions, in *Restorative Techniques for Individual Teeth*, Baum L, ed. New York: Masson, 1981, pp 247-65.
- Fischer D: Tissue management: A new solution to an old problem. *Gen Dent* 35:178-82, 1987.
- Fuks AB, Bimstein E: Clinical evaluation of diluted formocresol pulpotomies in primary teeth of school children. *Pediatr Dent* 3:321-24, 1981.
- Fuks AB, Bimstein E, Klein H: Assessment of a 2% buffered glutaraldehyde solution in pulpotomized primary teeth of school children: A preliminary report. *J Pedod* 10:323-30, 1986.
- Fuks AB, Bimstein E, Guelmann M, Klein H: Assessment of a 2 percent buffered glutaraldehyde solution in pulpotomized primary teeth of schoolchildren. *ASDC J Dent Child* 57:371-75, 1990.
- García-Godoy F: A comparison between zinc oxide-eugenol and polycarboxylate cements on formocresol pulpotomies. *J Pedod* 6:203-17, 1982.
- García-Godoy F: A 42-month clinical evaluation of glutaraldehyde pulpotomies in primary teeth. *J Pedod* 10: 148-55, 1986.
- Heilig J, Yates J, Siskin M, McKnight J, Turner J: Calcium hydroxide pulpotomy for primary teeth: a clinical study. *J Am Dent Assoc* 108:775-78, 1984.
- Judd PL, Kenny DJ: Formocresol concerns, a review. *J Can Dent Assoc* 53:401-404, 1987.
- Landau MJ, Johnsen DC: Pulpal responses to ferric sulfate in monkeys. *J Dent Res* 67:215 (Abstr no 822), 1988.
- Magnusson B: Therapeutic pulpotomy in primary molars — clinical and histological follow-up. I. Calcium hydroxide paste as wound dressing. *Odontol Revy* 21:415-31, 1970.
- Morawa AP, Straffon LH, Han SS, Corpron RE: Clinical evaluation of pulpotomies using dilute formocresol. *J Dent Child* 42:360-63, 1975.
- Myers DR, Shoaf HK, Dirksen TR, Pashley DH, Whitford GM, Reynolds KE: Distribution of ^{14}C -formaldehyde after pulpotomy with formocresol. *J Am Dent Assoc* 96:805-13, 1978.
- Olmstead PM, Lund HZ, Leonard DD: Monsel's solution: A histologic nuisance. *J Am Acad Dermatol* 3:492-98, 1980.
- Prakash C, Chandra S, Jaiswal JN: Formocresol and glutaraldehyde pulpotomies in primary teeth. *J Pedod* 13:314-22, 1989.
- Pruhs RJ, Olen GA, Sharma PS: Relationship between formocresol pulpotomies on primary teeth and enamel defects on their permanent successors. *J Am Dent Assoc* 94:698-700, 1977.

- Rølling I, Lambjerg-Hansen H: Pulp condition of successfully, formocresol-treated primary molars. *Scand J Dent Res* 86:267-72, 1978.
- Rølling I, Poulsen S: Formocresol pulpotomy of primary teeth and occurrence of enamel defects on the permanent successors. *Acta Odontol Scand* 36:243-47, 1978.
- Ruemping DR, Morton TH, Anderson MW: Electrosurgical pulpotomy in primates — A comparison with formocresol pulpotomy. *Pediatr Dent* 5:14-18, 1983.
- Schröder U: Agreement between clinical and histologic findings in chronic coronal pulpitis in primary teeth. *Scand J Dent Res* 85:583-87, 1977.
- Schröder U: A 2-year follow-up of primary molars, pulpotomized with a gentle technique and capped with calcium hydroxide. *Scand J Dent Res* 86:273-78, 1978.
- Schröder U: Effects of calcium hydroxide-containing pulp-capping agents on pulp cell migration, proliferation, and differentiation. *J Dent Res* 64:541-48, 1985.
- Shaw DH, Krejci RF, Kalkwarf KL, Wentz FM: Gingival response to retraction by ferric sulfate (Astringedent). *Oper Dent* 8:142-47, 1983.
- Shaw DW, Sheller B, Barrus BD, Morton TH: Electrosurgical pulpotomy — A 6-month study in primates. *J Endod* 13:500-505, 1987.
- Shoji S, Nakamura M, Horiuchi H: Histopathological changes in dental pulps irradiated by CO₂ laser: A preliminary report on laser pulpotomy. *J Endod* 11:379-84, 1985.
- Shulman ER, McIver FT, Burkes EJ: Comparison of electrosurgery and formocresol as pulpotomy techniques in monkey primary teeth. *Pediatr Dent* 9:189-94, 1987.
- Willard RM: Radiographic changes following formocresol pulpotomy in primary molars. *J Dent Child* 43:414-15, 1976.
- Wright FAC, Widmer RP: Pulpal therapy in primary molar teeth: a retrospective study. *J Pedod* 3:195-206, 1979.

Statement of Ownership, Management, and Circulation

Pediatric Dentistry, the Journal of the American Academy of Pediatric Dentistry, is published bimonthly by the American Academy of Pediatric Dentistry, 211 E. Chicago Ave. - Suite 1036, Chicago, IL 60611-2616. Editor in chief: Paul S. Casamassimo, DDS, MS, Columbus Children's Hospital, Department of Pediatric Dentistry, 700 Children's Dr., Columbus, OH 43205. Managing Editor: John B. Ferguson, American Academy of Pediatric Dentistry, 211 E. Chicago Ave. - Suite 1036, Chicago, IL 60611-2616.

The American Academy of Pediatric Dentistry is a nonprofit organization with no capital stock and no known bondholders, mortgages, or other security hold-

ers. The average number of copies of each issue produced during the past 12 months was 4,260; none sold through dealers and carriers, street vendors, or counter sales; 3,618 distributed through mail subscriptions, 3,618 total paid circulation; 20 distributed as complimentary copies. For the July/ August, 1991 issue the actual number of copies printed was 4,455; none sold through dealers and carriers, street vendors, or counter sales; 3,703 distributed through mail subscriptions, 3,703 total paid circulation; 20 distributed as complimentary copies; 3,723 copies distributed in total. Statement filed with the U.S. Postal Service November 1, 1991.