

## Treatment of severe microstomia caused by massive fungal destruction of the lips: clinical report

Gerald A. Ferretti, DDS, MSD  
Edward A. Luce, MD  
John R. Mink, DDS, MSD

**T**he literature contains many reports about the care and prevention of microstomia caused by electrical, thermal, and caustic burns of the lip and perioral areas.<sup>1-9</sup> Treatment for the prevention of microstomia is similar regardless of the cause. These traumas to the oral and perioral tissue usually occur between 10 months and 4 years of age.<sup>2,3,7,8</sup> The immediate problems are tissue damage, hemorrhage, infection, nutritional deficiency, and scar adhesions. The long-term outcome, (severe contracture or microstomia) results in problems associated with development of the orofacial structures, oral hygiene, dental treatment, facial expression, speech, and general anesthesia administration.<sup>4</sup>

Use of an appliance to prevent microstomia is indicated when there is unilateral or bilateral damage to the commissures of the lips. The appliance is inserted immediately after the patient is stable and preferably before the eschar sloughing that usually occurs within the first two weeks. It is used to prevent commissure adhesions, scar contracture, and to prevent or minimize the need for surgical procedures. The appliance is worn 24 hours a day except when the child eats or the wound is cleaned. The length of wearing time depends on the age and cooperation of the child and the severity of oral damage. This time period may range from three months to two years after the initial trauma.<sup>1,4,6,9</sup>

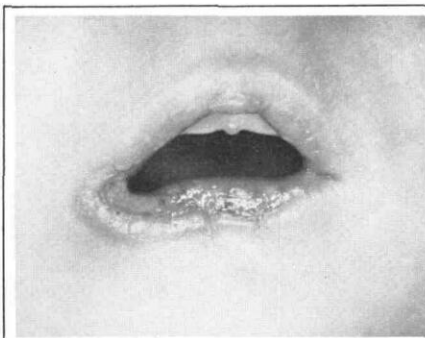
This clinical report relates the treatment of a patient with severe microstomia resulting from a massive oral fungal infection.

### Clinical Report

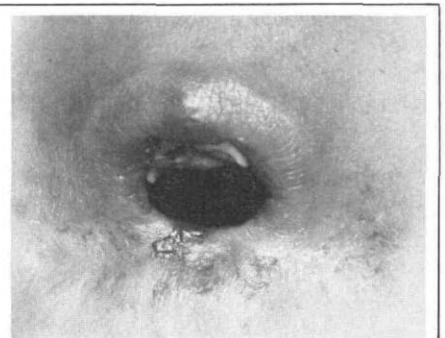J.B., a two-year-old male, was admitted to the University of Kentucky Medical Center for a surgical lip revision.

The admitting diagnosis was severe microstomia secondary to oral scarring from persistent oral mucocutaneous candidiasis since shortly after birth. Diagnostic tests showed an isolated T cell autoimmune defect against *Candida albicans*. Consequently an appliance to prevent microstomia was said to be contraindicated at the initial evaluation (4 months of age) for fear of providing a locus for recurrent candidiasis (Figure 1). Clinical examination of J.B. at 17 months of age, after four hospitalizations with subsequent treatment and resolution of oral mucocutaneous candidiasis, revealed a severe contracture and scarring of the mouth, lack of speech development, poor oral hygiene and many carious primary teeth.

A secondary admitting diagnosis was chronic bilateral otitis media and abscessed teeth. His oral opening was approximately one centimeter in diameter at the time of admission (Figure 2). Examination of the mouth revealed severely carious maxillary anterior primary teeth and a



**Figure 1.** Mucocutaneous damage to the lower lip and right commissure from an oral monilial infection at four months of age (left).



**Figure 2.** Oral opening of 1 cm diameter and carious anterior teeth at two years of age (right).

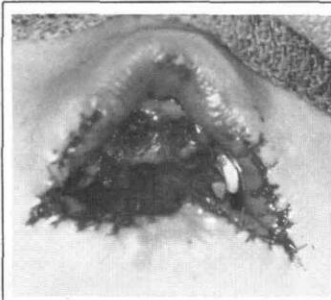


Figure 3. Surgical lip release of the orbicularis oris with primary closure (left).

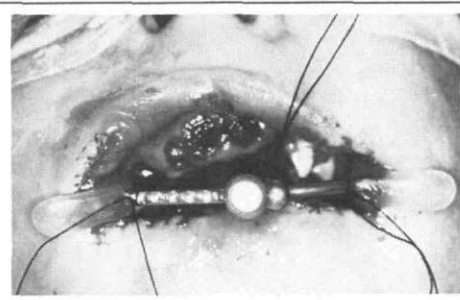


Figure 4. Removable appliance placed 48 hours after lip release (right).

2 x 2 mm hole just to the right of the soft palate midline. Significant laboratory data included a CBC which revealed a white cell count of 16,300. Antibiotics and oral Nystatin<sup>®a</sup> were given to control a fever spike the night before surgery but the surgery had to be delayed for two days until the fever subsided.

A blind nasotracheal tube was inserted to administer the general anesthetic. Polyethylene tubes were placed in both ears. The microstomia was corrected by primary closure, and five maxillary anterior primary teeth were extracted (Figure 3). A device was placed to prevent recurrence of the circumoral microstomia.<sup>b</sup>

There were no postoperative complications, and the oral appliance was removed for 48 hours for suture care; it was replaced before the patient was discharged (Figure 4). Antibiotics were continued throughout the preoperative and postoperative course. He was discharged three days after surgery and was given a return appointment for follow-up care in both the plastic surgery and pediatric dentistry clinics. Two weeks postoperatively the appliance was functioning properly and maintaining the oral opening (Figure 5); however, an ulceration and open wound were found at both commissures.

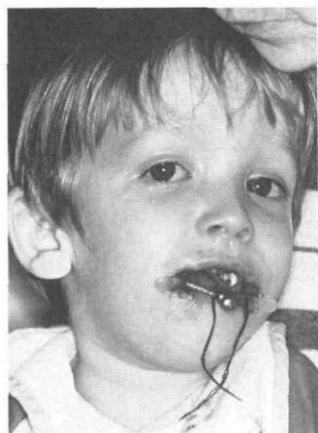


Figure 5. Oral opening with device in place two weeks after surgery.

Four weeks postoperatively J.B. returned to the hospital because the palate was inflamed, blisters had formed, and a purulent discharge was noted. The commissures appeared to be dry and ulcerated and there was thick yellowish plaque found on the palate. A cytologic smear of this material produced a hemorrhagic area under

the smear site. Pathologic examination of the exudate revealed epithelial cells and a heavy, mixed inflammatory cellular infiltrate with no fungal organisms. The plastic surgeon recommended that the appliance be removed to allow the commissural ulcer to heal and to prevent the possibility of infection and subsequent recurrence of an oral mucocutaneous candidiasis. The patient returned to the pediatric dentistry clinic for an oral examination one week after the appliance was removed. The oral opening had been reduced to approximately 50% of that produced by the surgery (Figure 6). The microstomia prevention appliance was replaced to prevent further closure after the acrylic wings were reduced significantly. It was worn with light tension that caused blanching of the oral commissures; tension was needed to remodel the immature scar formation in the shape of the original surgical opening. The appliance was worn for the same length of time as noted previously, and lip ointment was smeared on the flanges to facilitate insertion. The parent was told to open the appliance as it became loose in order to keep slight pressure on the commissures; she was also told that her part in following these instructions was important to the success of the treatment. The appliance was removed nine months after the original surgery, but one month after it had been reinserted the oral opening was nearly back to the original diameter obtained by the surgical lip-release procedure.

During the time the appliance was worn ulcers were present at the commissures, but within one month after it was removed these ulcers healed. At a six-month follow-up examination good circumoral healing with slight scar contracture was noted (Figure 7.)

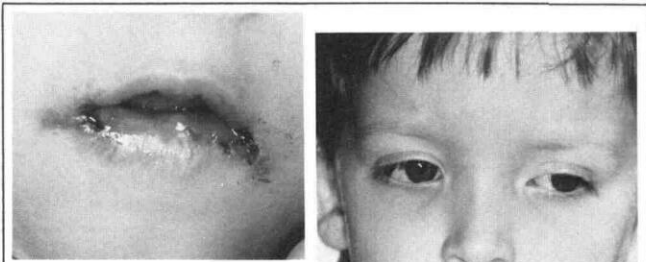
## Discussion

This same surgical procedure may have to be performed again in order to allow J.B.'s facial structure to develop properly. The use of a removable microstomia-prevention appliance prevents wound adhesion and immature scar contracture, and within a one-week period after it was removed prematurely the oral opening constricted.

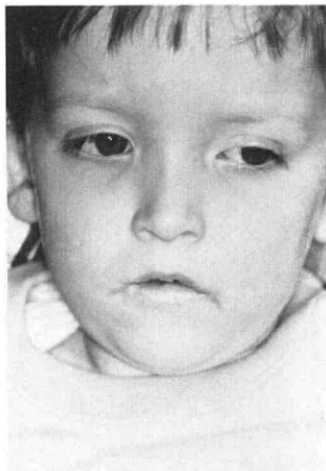The treatment for prevention of microstomia from perioral damage caused by a severe oral fungal infection is no different than for cases of electrical, thermal, or caustic burns with subsequent circumoral damage. There is great risk of a recurrent mucocutaneous candidiasis in-

<sup>a</sup> Premo Pharmaceutical Laboratories, Inc.; S. Hackensack, N.J.

<sup>b</sup> MPA, Iowa City, Iowa.



**Figure 6.** Oral opening one week after prematurely removing the microstomia appliance (above).



**Figure 7.** Six-month postoperative followup. Note the circumoral healing and slight scar contracture (right).

fection from this type of surgical procedure. Use of a removable microstomia prevention appliance in a person with a transient autoimmune defect must be weighed carefully.

Dr. Ferretti is an assistant professor and residency program director, Department of Pediatric Dentistry, College of Dentistry, and an assistant professor, Department of Pediatrics, College of Medicine; Dr. Luce

is an associate professor, Department of Plastic Surgery, College of Medicine; and Dr. Mink is associate dean for clinical affairs, and professor and acting chairman, Department of Pediatric Dentistry, College of Dentistry, A.B. Chandler Medical Center, University of Kentucky, Lexington, Ky. 40536. Requests for reprints should be sent to Dr. Ferretti.

1. Colcleugh, R.G., Ryan J.E. Splinting electrical burns of the mouth in children. *Plast Reconstr Surg* 58:239-41, 1976.
2. Gifford, G.H., Jr., Marty, A. T., MacCollum, D.W. The management of electrical mouth burns in children. *Pediatrics* 47:113-19, 1971.
3. Gormley, M.B., Marshall, J., Jarrett, W., Bromberg, B. Thermal trauma: a review of 22 electrical burns of the lip. *J Oral Surg* 30:531-33, 1972.
4. Hartford, C.E., Kealey, G.P., Lavelle, W.E., Buckner, H. An appliance to prevent and treat microstomia from burns. *J Trauma* 15:356-60, 1975.
5. Jackson, M.J. The use of a dynamic-lip expander in the rehabilitation of a severely burned faced: report of a case. *J Dent Child* 46:230-33, 1979.
6. Larson, T.H. Splinting oral electrical burns in children: report of two cases. *J Dent Child* 44:382-84, 1977.
7. Pitts, W., Pickrell, K., Quinn, G., Massengill, R. Electrical burns of lips and mouth in infants and children. *Plast Reconstr Surg* 44:471-79, 1969.
8. Thomason, H.G., Jukes, A.W., Farmer, A.W. Electrical burns to the mouth in children. *Plast Reconstr Surg* 35:466-77, 1965.
9. Wood, R.E., Quinn, R.M., Forgey, J.E. Treating electrical burns of the mouth of children. *JADA* 97:206-8, 1978.

### Quotable Quote

Marijuana is being used by younger and younger age groups. This finding also has serious implications, not the least of which is that the earlier the age at which marijuana is first used, the greater the likelihood of involvement with more serious drugs. The age of first use has declined progressively over the past 15 years. In the early stages of the drug culture the first use of marijuana occurred primarily after high school. In 1981, however, 34% of high school seniors had begun smoking marijuana before entering high school, and many had started to use it as early as the sixth grade.

From: Nicholi, A. M., Jr. The Nontherapeutic Use of Psychoactive Drugs - A Modern Epidemic. *The New England Journal of Medicine*, Vol. 308, No. 16, April 21, 1983.