



Differential diagnosis of oral enlargements in children

Catherine M. Flaitz, DDS, MS Gary C. Coleman, DDS, MS

Abstract

The purpose of this article is to review soft tissue and bony enlargements that typically occur in the oral and perioral region of children. In order to organize these lesions into a thorough but comprehensible format, the principles of differential diagnosis must be used. All oral enlargements are broadly classified as soft tissue or bony abnormalities. Determination of the specific lesion category is based primarily on a prominent feature that demonstrates the nature of the lesion, followed by the secondary clinical features and any contributory patient information. Classification of exophytic soft tissue entities includes: papillary surface enlargements, acute inflammatory enlargements, reactive hyperplasias, benign submucosal cysts and neoplasms, and aggressive and malignant neoplasms. Bony enlargements of the maxilla and mandible are divided into three categories: inflammatory lesions, benign cystic and neoplastic lesions, and aggressive and malignant lesions. This extensive topic is summarized on flow charts for easy reference with emphasis on grouping together lesions with common characteristics. (Pediatr Dent 17:294-300, 1995)

An enlargement of the oral cavity may represent a wide range of entities such as anatomic variations, developmental anomalies, inflammatory and reactive diseases, cysts, and neoplasms. The goal of differential diagnosis is to determine the nature of the enlargement as a basis for formulating a rational treatment approach. The symptoms, growth rate, palpation characteristics, surface morphology, and lesion site allow for categorization of the soft tissue lesions into one of the five lesion groups as outlined in Fig 1*. These descriptive categories consist of:

1. Papillary surface enlargements (Fig 2)
2. Acute inflammatory enlargements (Fig 3)
3. Reactive hyperplasias (Fig 4)
4. Benign submucosal cysts and neoplasms (Fig 5)
5. Aggressive and malignant neoplasms (Fig 6).

Once a specific category has been selected, the characteristics of the lesion can be compared with other diseases that share common clinical features and behavioral patterns.

Soft tissue lesions

Papillary enlargements of the soft tissues are a distinct group of lesions that are easy to recognize because of their common clinical appearance. Most of these lesions represent a viral-induced epithelial proliferation resulting in pale, spongy-to-firm enlargements with a pebbly or papillary, rough surface texture. These slow-growing lesions are painless with a limited growth potential. Broadly this group is divided into isolated or multiple lesions to assist in the diagnosis and appropriate management of the pediatric patient (Fig 2). The behavior of these lesions is variable, ranging from spontaneous resolution to a recurrent, protracted course.

Acute inflammatory enlargements are characterized by sudden onset, rapid progression, and compressible tissue distention. These fluid-filled or edematous lesions are frequently tender or painful to palpation and may fluctuate in size. Systemic manifestations such as fever, malaise, and lymphadenopathy may develop with lesion progression. As described in Fig 3, this disease category is divided into infectious and noninfectious processes that present with either localized or diffuse tissue involvement. In most instances, identifying and eliminating the source of the inflammation produces rapid resolution of the lesion.

Reactive hyperplasias are a benign group of lesions that frequently mimic neoplastic disease. Most reactive hyperplasias develop in response to a chronic, recurring injury that stimulates an exuberant tissue repair. These inflammatory enlargements are defined by a moderate growth rate, absence of pain, and limited growth potential. The degree of vascularity and edema associated with the soft tissue enlargement determines the color and palpation characteristics. As illustrated in Fig 4, this disease group is divided into either a primary or multifactorial cause for lesion ini-

* Figs 1 through 6 were modified with permission from Chapter 18, Differential diagnosis of oral soft tissue enlargements. In: Principles of Oral Diagnosis, Coleman GC, Nelson JF, Eds, St Louis: Mosby-Year Book, Inc. 1993, pp 352-88.

CHARACTERISTICS OF INTRAORAL SOFT TISSUE ENLARGEMENTS IN CHILDREN

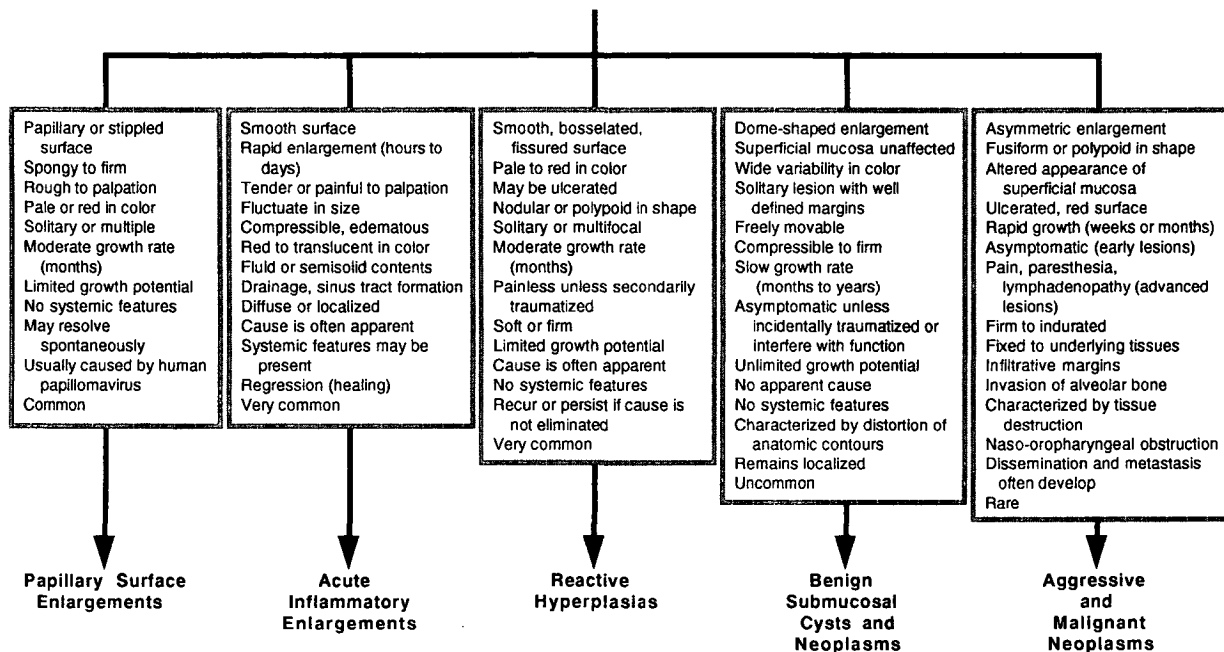


Fig 1. Differential diagnosis of intraoral soft tissue enlargements in children.

ORAL PAPILLARY SURFACE ENLARGEMENTS

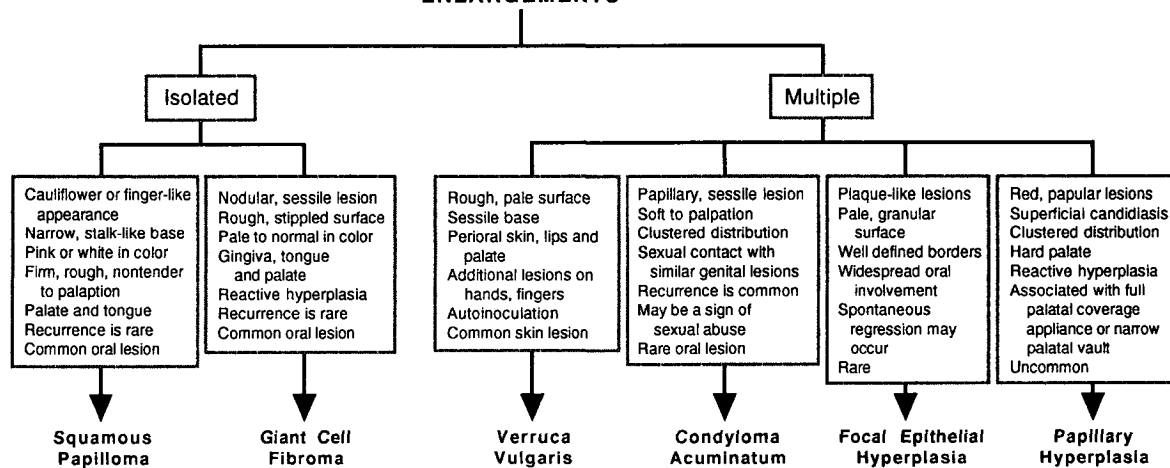


Fig 2. Differential diagnosis of papillary surface enlargements in children.

tiation and growth. Partial regression of the lesion may occur if the source of the soft tissue injury is removed.

Benign submucosal cysts and neoplasms are an uncommon group of lesions that are nodular, well delineated, and freely movable enlargements with normal-appearing, intact mucosal surfaces. The slow and persistent growth pattern results in alteration or distortion of the tissues. Most of these lesions are asymptomatic unless they are traumatized or impinge on vital structures. These lesions are divided into soft tissue cysts, benign connective tissue tumors, and salivary gland neoplasms as illustrated in Fig 5. In addition,

this group is subdivided by site predilection and palpation characteristics. Definitive diagnosis of this disease category is based on histopathologic examination of the surgical specimen.

Aggressive and malignant soft tissue enlargements of the oral cavity are the rarest but most important group to identify in the pediatric population. Rapid, progressive growth of an asymmetric enlargement with infiltrative margins are defining features of this group of lesions. These firm, fixed tumors demonstrate irregular surface changes with areas of erythema and ulceration. Although early lesions are asymptomatic,

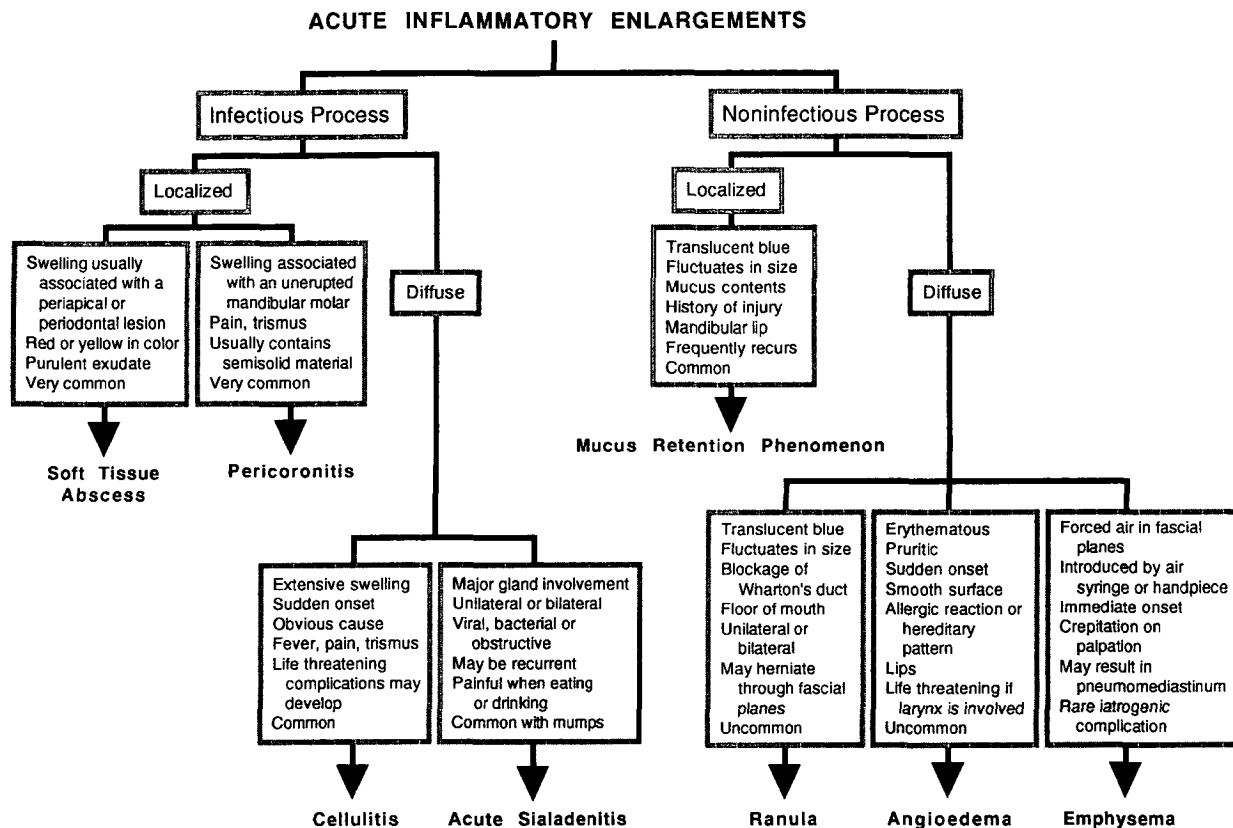


Fig 3. Differential diagnosis of acute inflammatory soft tissue enlargements in children.

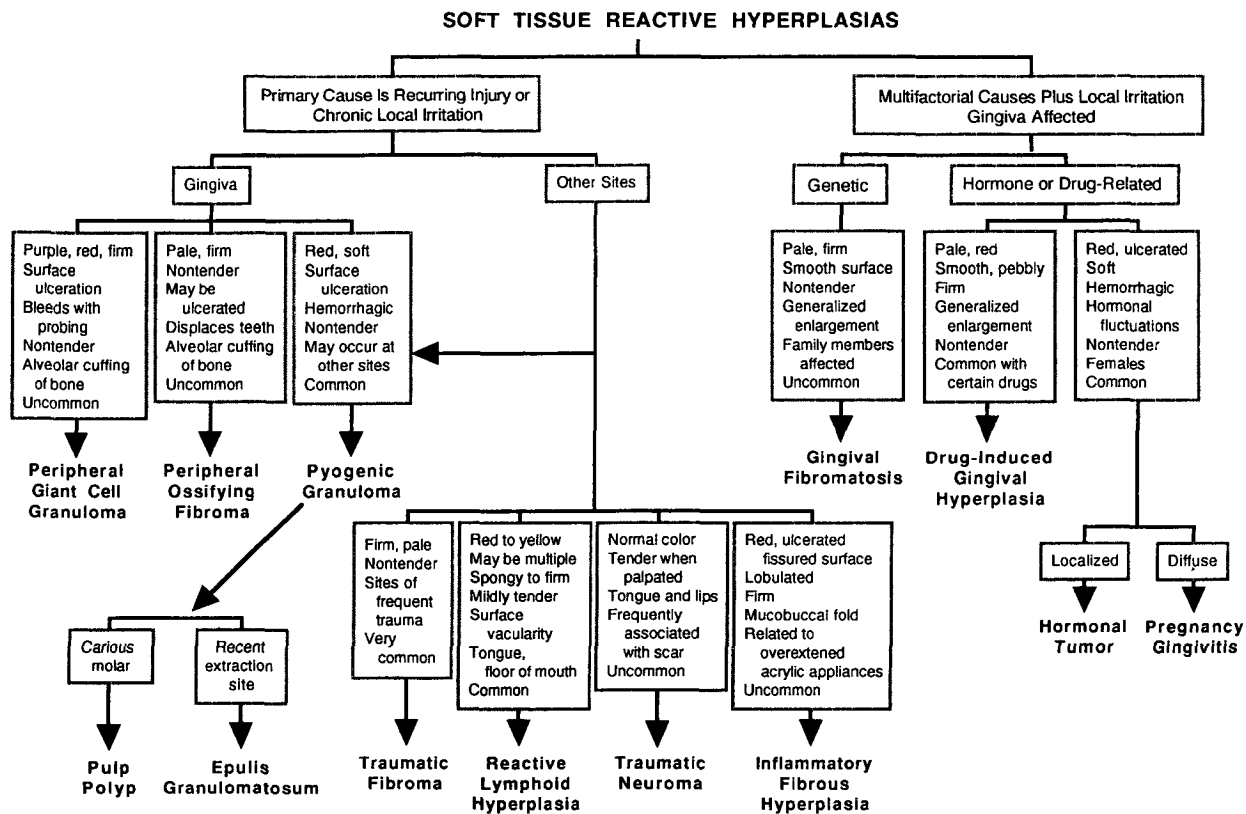


Fig 4. Differential diagnosis of soft tissue reactive hyperplasias in children.

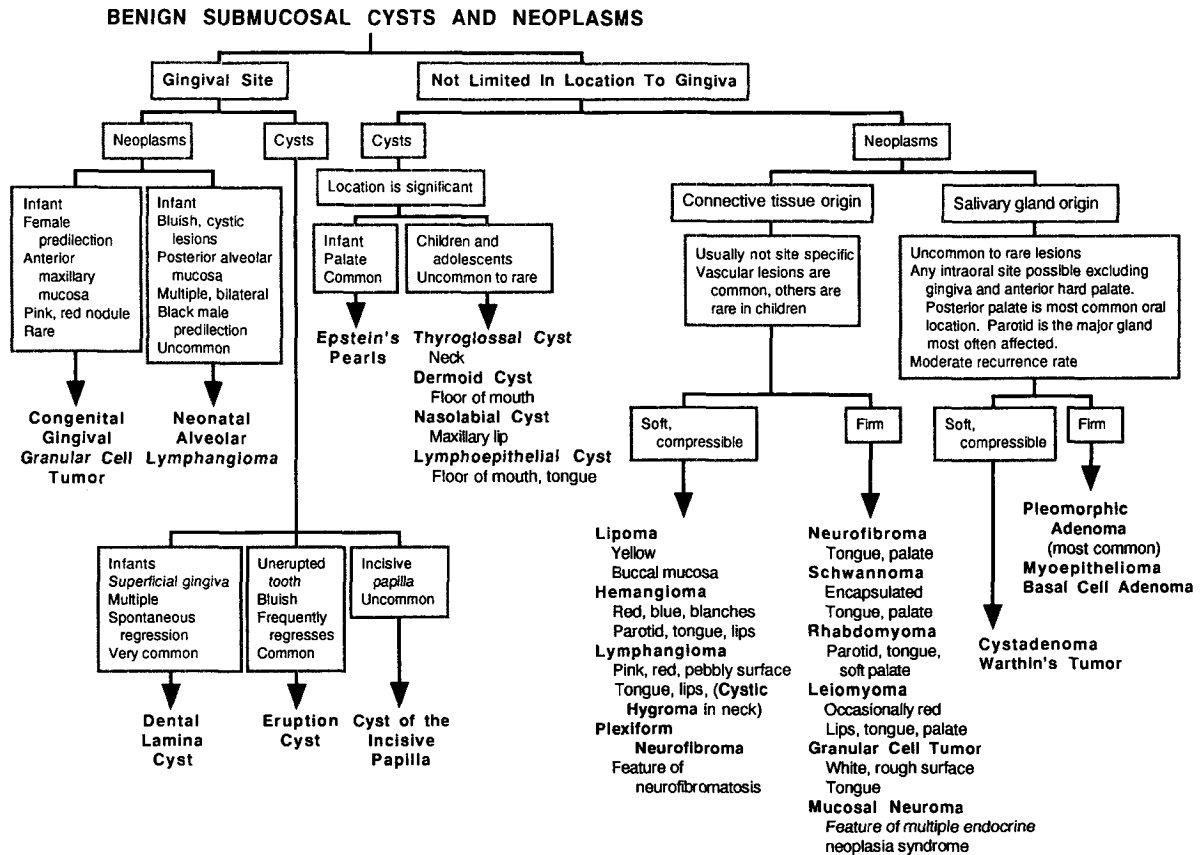


Fig 5. Differential diagnosis of benign submucosal cysts and neoplasms in children.

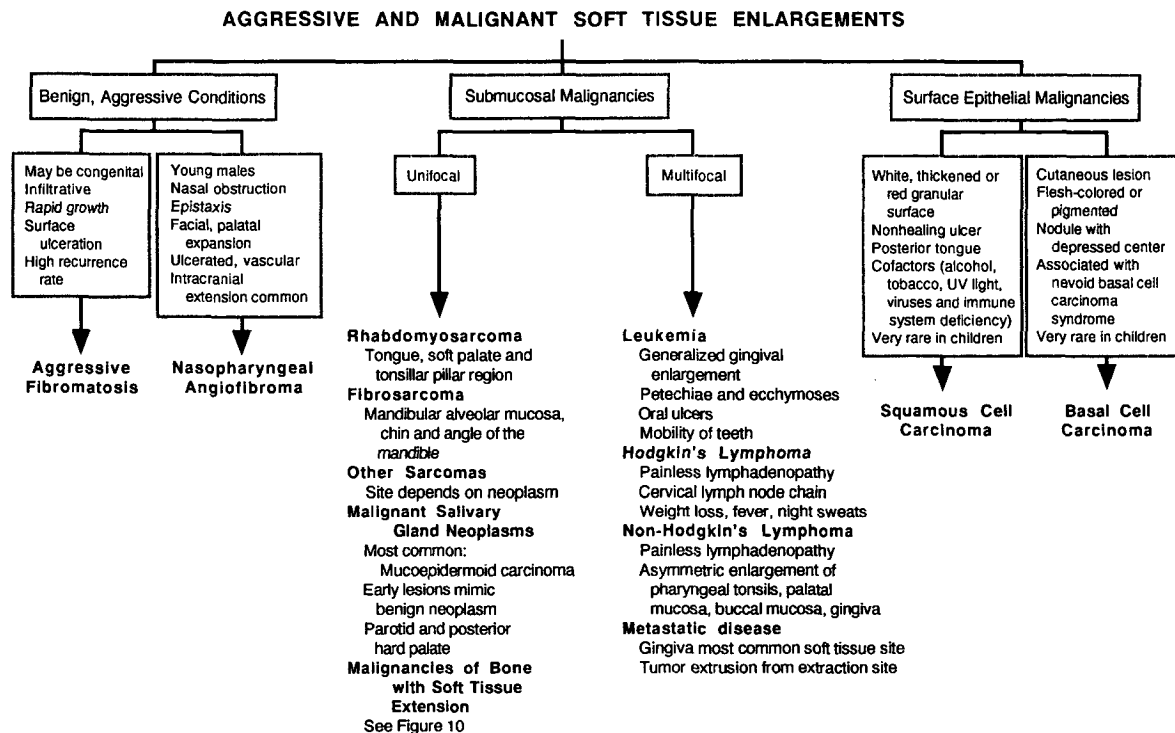


Fig 6. Differential diagnosis of aggressive and malignant soft tissue enlargements in children.

CHARACTERISTICS OF JAW ENLARGEMENTS IN CHILDREN

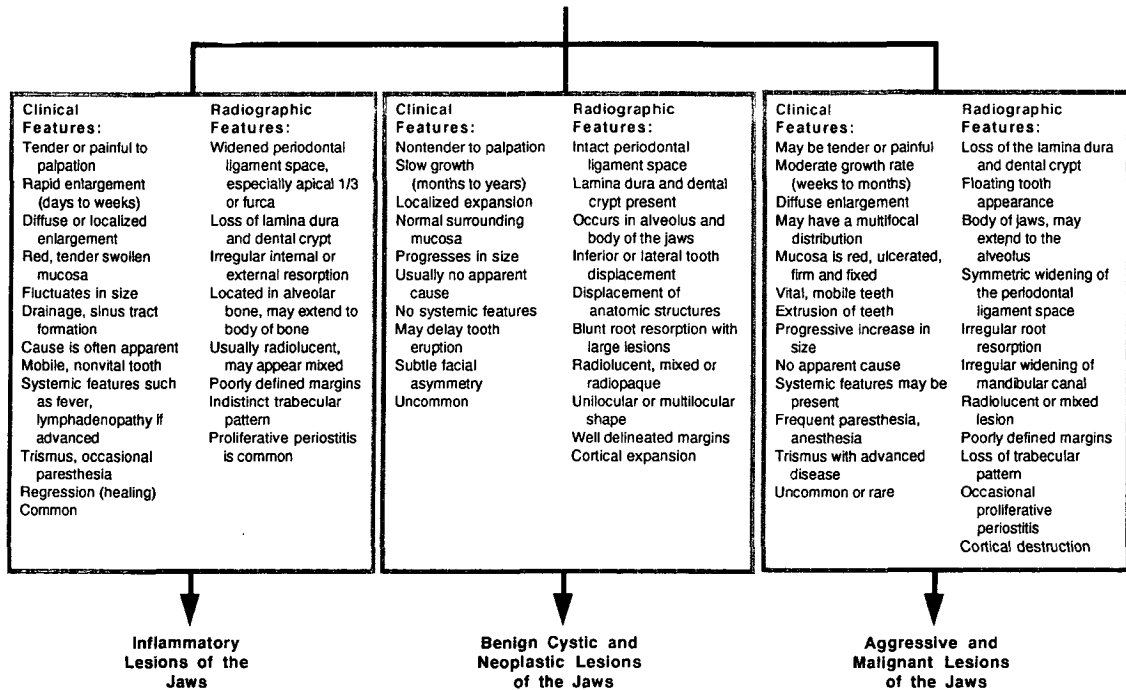
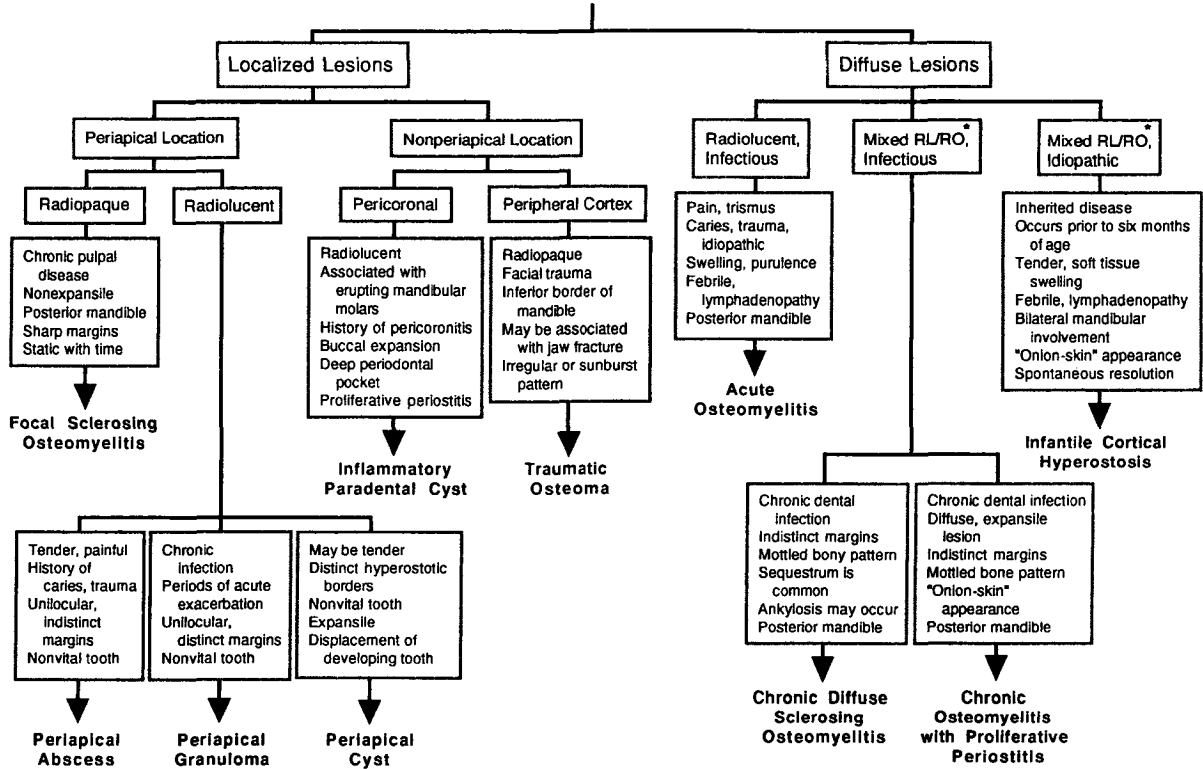


Fig 7. Differential diagnosis of intraoral lesions characterized by bony enlargement in children.

INFLAMMATORY LESIONS OF THE JAWS IN CHILDREN



* RL/RO = mixed radiolucent and radiopaque lesion

Fig 8. Differential diagnosis of inflammatory lesions of the jaws in children.

BENIGN CYSTIC AND NEOPLASTIC LESIONS OF THE JAWS

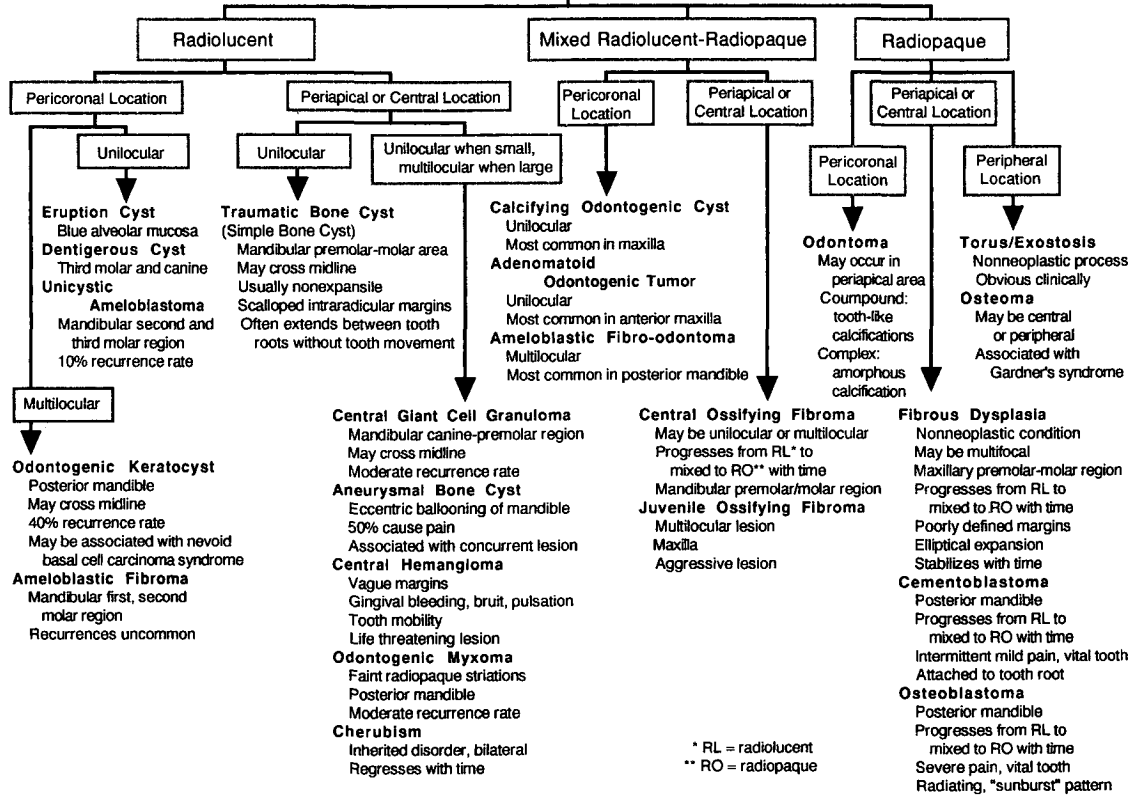


Fig 9. Differential diagnosis of benign cysts and neoplastic lesions of the jaws in children.

AGGRESSIVE AND MALIGNANT NEOPLASMS OF THE JAWS

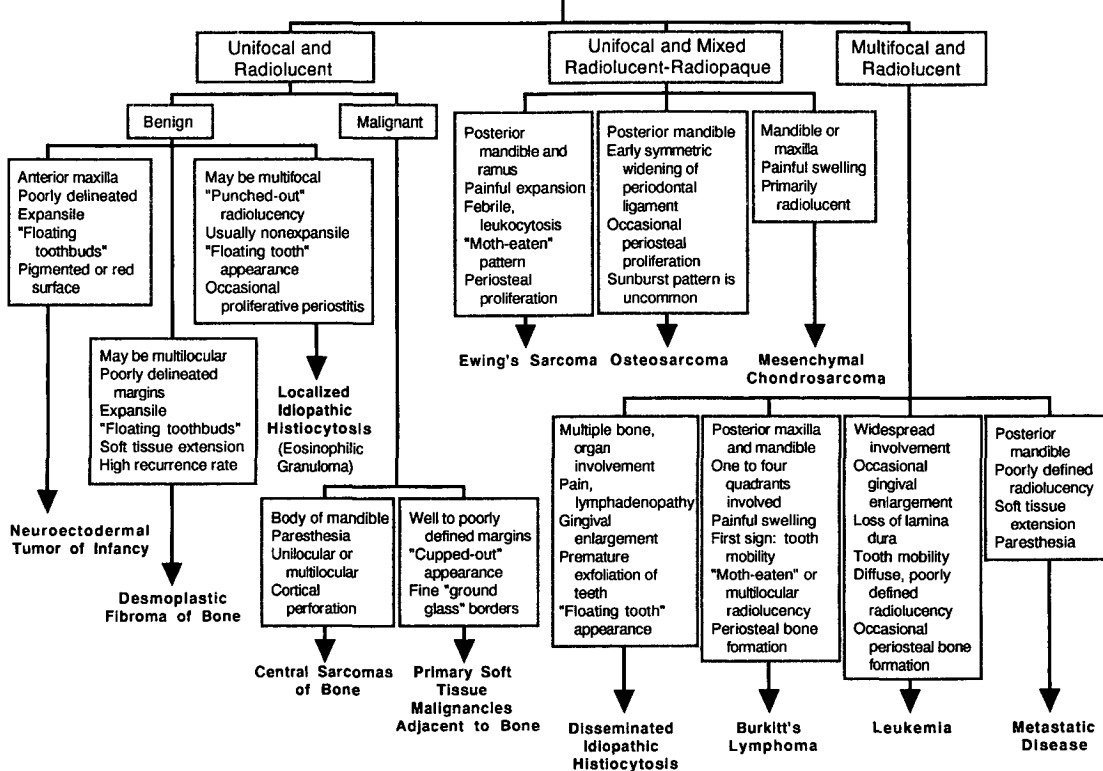


Fig 10. Differential diagnosis of aggressive and malignant neoplasms of the jaws in children.

pain, paresthesia, lymphadenopathy, and naso-oropharyngeal obstruction develop with tumor progression. These diseases have been divided into: benign, aggressive conditions; submucosal malignancies; and surface epithelial malignancies to compare common clinical features (Fig 6). In general, prognosis of this category of lesions depends on the size of the lesion, proximity to vital structures, and evidence of metastasis.

Bony enlargements

Bony enlargements of the maxilla and mandible in children rely on both clinical features and radiographic interpretation in order to develop a differential diagnosis. To manage this comprehensive topic, there are three distinct categories of bony enlargements: 1) inflammatory lesions of the jaws (Fig 8), 2) benign cystic and neoplastic lesions (Fig 9), and 3) aggressive and malignant lesions (Fig 10). The pertinent clinical and radiographic characteristics of jaw lesions in children are summarized in Fig 7.

Inflammatory lesions of the jaws have similar clinical findings as those described for the soft tissue counterpart. Rapid enlargement, pain, erythema, and drainage are characteristic. An apparent cause, in particular a mobile, nonvital tooth, frequently is observed. Important radiographic features include a poorly defined radiolucent or mixed radiolucent-radiopaque lesions of the alveolar bone. Additional findings may demonstrate a widened periodontal ligament space, loss of the lamina dura or dental crypt, and internal or external root resorption. Proliferative periostitis is common in this age group.

Broadly, inflammatory lesions of the jaws are classified as localized or diffuse entities with a radiolucent, radiopaque, or mixed radiolucent-radiopaque appearance (Fig 8).

Benign cystic and neoplastic lesions of the jaws are defined as locally expansile lesions with a slow but progressive growth pattern. Delayed tooth eruption and subtle facial asymmetry are associated with this group of lesions. The pertinent radiographic features include a well-delineated unilocular or multilocular lesion with cortical expansion. These bony lesions may appear radiolucent, radiopaque, or mixed. Inferior or lateral movement of teeth, blunt apical root resorption, and displacement of anatomic structures are detected when large lesions are present. As outlined in Fig 9, benign cystic and neoplastic lesions of the jaws are classified according to radiographic appearance and lesion site.

Aggressive and malignant neoplasms of the jaws are characterized by a diffuse enlargement with a moderate growth rate. Pain, mucosal ulceration, extrusion of teeth, and paresthesia are common complaints. Important radiographic features include a poorly defined radiolucent or mixed radiolucent-radiopaque lesion with cortical destruction. Irregular root resorption, loss of the lamina dura and dental crypt, symmetrical widening of the periodontal ligament

space, and a floating tooth appearance frequently are observed. Aggressive and malignant neoplasms of bone are categorized as radiolucent or mixed radiolucent-radiopaque lesions demonstrating unifocal or multifocal presentation (Fig 10).

Conclusion

In summary, this review article arranges exophytic oral lesions according to common, pertinent characteristics to allow differential diagnosis in the pediatric age group. Flow charts for both soft tissue and bony enlargements of the oral cavity have been designed to assist the pediatric dentist in this important decision-making process. Although the outline of this material is fairly comprehensive, its utility is as a supplement to more comprehensive oral pathology and diagnosis textbooks. In addition, it is not the goal of this material to allow the practitioner to arrive at a definitive diagnosis, but rather, to determine appropriate treatment based on the most likely cause for the soft tissue or bony enlargement. Although neoplastic diseases in children are uncommon, early detection frequently has a significant impact on the treatment regimen, surgical results, and overall prognosis.

Dr. Flaitz is associate professor and director, Surgical Oral Pathology Service, Division of Oral Pathology and Division of Pediatric Dentistry, The University of Texas—Houston Health Science Center Dental Branch, Houston. Dr. Coleman is associate professor, Division of Oral Diagnosis, Baylor College of Dentistry, Dallas, Texas.

1. Coleman GC: Differential diagnosis of radiographic abnormalities. In: *Principles of Oral Diagnosis*. Coleman GC, Nelson JF, Eds. St Louis: Mosby-Year Book Inc, 1992, pp 389–449.
2. Cunningham MJ, Meyers EN, Bluestone CD: Malignant tumors of the head and neck in children: a twenty-year review. *Int J Pediatr Otorhinolaryngol* 13:279–92, 1987.
3. Das S, Das AK: A review of pediatric oral biopsies from a surgical pathology service in a dental school. *Pediatr Dent* 15:208–11, 1993.
4. Flaitz CM: Differential diagnosis of oral soft tissue enlargements. In: *Principles of Oral Diagnosis*. Coleman GC, Nelson JF, Eds. St Louis: Mosby-Year Book Inc, 1992, pp 352–88.
5. Flaitz CM: Oral pathologic conditions and soft tissue anomalies. In: *Pediatric Dentistry Infancy through Adolescence*, 2nd Ed. Pinkham JR, Casamassimo PS, Fields HW, McTigue DJ, Nowak A, Eds. Philadelphia: WB Saunders Co, 1993, pp 29–56.
6. Greer RO, Mierau GW, Favare BE: *Tumors of the Head and Neck in Children*. New York: Greenwood, 1983.
7. Neville BW, Damm DD, Allen CM, Bouquot JE: *Oral & Maxillofacial Pathology*. Philadelphia: WB Saunders Co, 1995.
8. Neville BW, Damm DD, White DK, Waldron CA: *Color Atlas of Clinical Oral Pathology*. Philadelphia: Lea & Febiger, 1991.
9. Regezi JA, Sciubba JJ: *Oral Pathology, Clinical-Pathologic Correlations*. 2nd Ed. Philadelphia: WB Saunders Co, 1993.
10. Scully C, Welbury R: *Color Atlas of Oral Diseases in Children and Adolescents*. London: Wolfe Publishing, 1994.
11. Skinner RL, Davenport WD Jr, Weir JC, Carr RF: A survey of biopsied oral lesions in pediatric dental patients. *Pediatr Dent* 8:163–67, 1986.
12. Wood NK, Goaz PW: *Differential Diagnosis of Oral Lesions*. 4th Ed. St Louis: CV Mosby Co, 1991.