

# Clinical evaluation of diluted formocresol pulpotomies in primary teeth of school children

Anna B. Fuks, DDS  
Enrique Bimstein, DMD

## Abstract

*The present investigation was undertaken to clinically and radiographically observe human primary teeth after pulpotomy using one-fifth dilution of formocresol. Seventy-seven teeth of 59 children, average age seven years, were treated. Seventy teeth were available for follow-up over a period varying from 4 to 36 months. The degree of root resorption was evaluated comparing pairs of treated and homologous non-pulpotomized teeth. Only four teeth had to be extracted, two of them due to furcation radiolucency, one due to a periapical lesion, and one due to internal resorption. Forty-one pairs were available for root resorption analysis: 19 had a similar resorption rate, 16 treated teeth resorbed faster, and 6 resorbed slower than their controls.*

## Introduction

Pulpotomies are an accepted and widely utilized procedure for treating cariously exposed vital primary teeth.<sup>1</sup> Numerous clinical studies on formocresol pulpotomies report different success rates.<sup>2,4</sup> These numbers decrease when histologic examinations are performed in addition to the clinical and radiographic checkups. Description of histologic findings ranged from slight inflammation to total degeneration and necrotic changes; these are amenable to repair by replacement with granulation tissue and ingrowth of connective tissue through the apex.<sup>5,7</sup> The last point is still a matter of debate by several authors, but seems to be the accepted concept currently.<sup>8</sup> An optimal pulp dressing medicament for pulpotomized primary teeth has not yet been found. Most studies have employed the formula proposed by Buckley, who used 19 percent formaldehyde, 35 percent cresol, and 15 percent glycerine in distilled water. It is generally accepted that this solution is toxic to connective tissue cells.<sup>9</sup>

Straffon and Han, in 1968, evaluated the effect of a one-fiftieth dilution of the formocresol on hamster connective tissue cells, and concluded that formocresol in that concentration does not interfere with prolonged recovery of connective tissue, and might significantly suppress initial inflammatory response.<sup>10</sup> A number of other experiments have been carried out

using different dilutions of formocresol;<sup>9,11-13</sup> they demonstrated that the toxicity of the formula decreased proportionally to the dilution.<sup>11</sup> From these studies it became evident that a one-fifth dilution was the most favorable, because it was as effective in bringing about cyto-stasis as the full concentration, yet it allowed a faster recovery of the affected connective tissue cells.<sup>9</sup> These results were confirmed by Escobar<sup>14</sup> in tests using the one-fifth dilution in monkey primary molars.

Based on experimental data from Escobar, Morawa et al.<sup>13</sup> suggested the clinical use of a one-fifth dilution of formocresol for pulpotomies in primary teeth in children. They concluded that the effective clinical result achieved was equal to, if not better than, that obtained from the use of full-strength formocresol. Further evidence of better pulp response to diluted formocresol than to the full concentration has been demonstrated histologically in dog and monkey teeth.<sup>15,16</sup>

The purpose of the present investigation is to observe the clinical behavior of human primary teeth after being pulpotomized and treated with a one-fifth dilution of formocresol.

## Methods and Material

Twenty-two boys and 37 girls, all of them elementary school second graders with an average age of seven years, participated in this study. Pulpotomies were performed in 77 primary teeth, using the formocresol solution proposed by Escobar and tested clinically by Morawa et al.<sup>13,14</sup> The material included 29 upper primary molars, 2 maxillary cuspids and 46 mandibular primary molars.

The criteria for selection of the teeth to be treated were: 1. symptomless exposure of vital pulp by caries, 2. no clinical or radiographic evidence of pulp degeneration, and 3. the possibility of proper restoration of the tooth.

## The Pulpotomy Technique

The teeth to be treated were anesthetized and isolated with rubber dam. Preparation for a preformed stainless steel crown was completed and all caries were removed before opening of the pulp chamber. Coronal pulp was amputated with a clean round bur mounted on a low speed engine, and rinsed with sterile saline. Hemostasis was promoted by placing a dry cotton pellet at the pulp chamber. A cotton pellet moistened with the one-fifth diluted formocresol was then applied over the pulp stumps for five minutes, removed, and a dressing made of zinc oxide mixed with equal amounts of eugenol and diluted formocresol was used to cover the remaining pulp. The teeth were restored with a stainless steel crown.

Clinical and radiographic follow-up varied from 4 to 36 months (Table 1). The treatment was regarded

**Table 1.** Clinical success rate of pulpotomized primary teeth of school children utilizing a one-fifth diluted formocresol solution.

Time In Months After Treatment	Clinical Status at the Last Examination		
	Success	Failure	Total
1 - 6	3	1	4
7 - 12	28	1	29
13 - 18	11	2	13
19 - 24	17	0	17
25 - 30	6	0	6
more than 30	1	0	1
<b>Total</b>	<b>66 (94.3%)</b>	<b>4 (5.7%)</b>	<b>70 (100%)</b>

as a failure when one or more of the following signs was present: internal root resorption, furcation, periapical bone destruction, pain, swelling, or sinus tract.

The degree of root resorption of treated and homologous teeth was evaluated according to criteria established by Wright,<sup>17</sup> in which root resorption was measured in three grades as follows: 1. one or more roots near complete resorption, 2. one or more roots, resorption within mid third of root, and 3. less than one third resorption on any root. All the radiographs were examined concomitantly by both authors.

## Results

From a total of 77 treated teeth only 70 were available for checkup, 31 maxillary and 39 mandibular.

Table 1 presents the rate of clinical success at the time the tooth was last examined. Approximately 83 percent of the examined teeth have been in the mouth between 7 to 24 months. Only four teeth showed signs of failure and had to be extracted — two of them

presented evidence of furcation radiolucency, one had a periapical lesion, and the other had internal resorption (Figures 1 & 2). Twenty teeth presented with root canal obliteration and 46 were normal clinically and radiographically (Figure 3, Table 2).

The degree of root resorption of the treated teeth compared to non-pulpotomized controls is shown in Table 3. A total of 41 pairs were available for analysis; among them, 19 pairs had a similar resorption rate, 16 pulpotomized teeth resorbed faster and 6 slower than their non-pulpotomized controls.

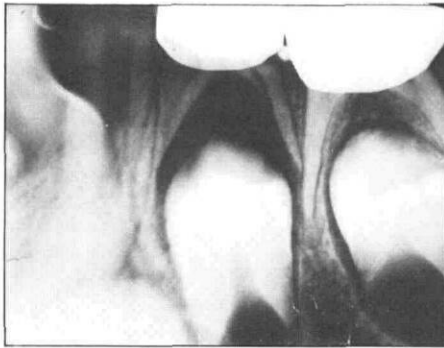
## Discussion

Previous articles described controversial results utilizing the full formocresol concentration in primary teeth of children. Rolling and Thylstrup,<sup>4</sup> observing 98 pulpotomized primary molars, didn't report a single case of internal resorption after three years, while Magnusson,<sup>7</sup> reported this finding in 37 percent of lower primary molars. A small percentage of internal resorption (1.4%) was found in the present study. Radiographic changes in upper molars are sometimes difficult to discern; even when considering exclusively the lower molars (39 teeth), a low rate of internal resorption was found (2.6%).

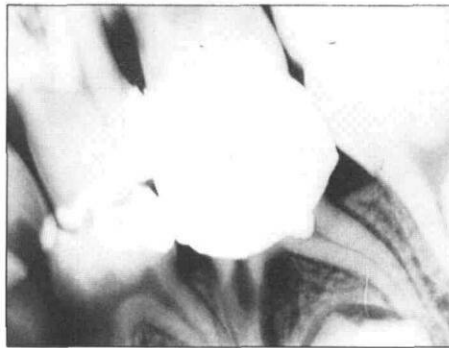
These differences in clinical response may be due to the absence of a typical response of the pulp tissue to formocresol, which has been described as "capricious."<sup>7</sup> Other contributing factors that might lead to internal resorption after pulpotomy are a traumatic cutting technique or the presence of an extrapulpal blood clot that would cause chronic inflammation.<sup>18,19</sup>

Relatively high percentages of periapical and furcation radiolucent areas were reported by different authors, all of them using the traditional Buckley's solution. A considerably lower percentage was observed in the present study using the one-fifth dilution of formocresol (Table 2).

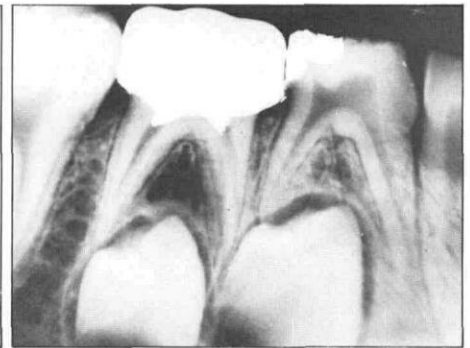
Root canal obliteration following formocresol pulpotomy in human primary teeth has been reported; calcific metamorphosis is apparently the result of exaggerated odontoblastic activity following formocresol pulpotomy.<sup>20,22</sup> It has been demonstrated by proline labeling in non-carious monkey teeth, that repair may occur slowly or not at all in formaldehyde influenced pulp, but in unaffected tissue, dentin formation occurs normally.<sup>22</sup> This might not be the behavior of cariously exposed primary teeth where chronic inflammation may be present and the dentin formation disturbed even in areas not directly affected by formocresol. Moreover, protein fixation by formocresol, as well as cytotoxicity, has been reported as being a function of the strength of the medicament; although there is protein biosynthesis impairment no matter what the concentration of the solution utilized, a one-fifth dilution allows for tissue recovery.<sup>11</sup>



**Figure 1.** Radiograph of pulpotomized lower first primary molar — note the presence of a furcation radiolucency, indicating failure of the treatment.



**Figure 2.** Radiograph of lower second primary molar showing internal root resorption of the mesial root and incomplete obliteration of the distal root. Note radiolucency of the bone next to the internal resorption area.



**Figure 3.** Radiograph of a lower second primary molar with a partially obliterated mesial root.

**Table 2.** Effect of a one-fifth dilution of formocresol on pulpotomized primary teeth of school children: radiographic findings.

No. of Treated Teeth	Radiographic Findings									
	Normal		Internal Resorption		Root Canal Obliteration		Furcation Radiolucency		Periapical Radiolucency	
	No.	%	No.	%	No.	%	No.	%	No.	%
70	46	65.7	1	1.4	20	28.6	2	2.9	1	1.4

Obliteration of the root canal is still present in a relatively small rate in the present study suggesting that a less toxic solution might lead to better clinical results (Table 2).

The only previous clinical study using diluted formocresol in human primary teeth is that of Morawa.<sup>13</sup> He mentions the presence of two failures out of a total of 125 pulpotomies, but the reasons are not specified.

An increased rate of root resorption following therapy with different concentrations of formaldehyde in primary molars is a well-documented fact.<sup>13,17</sup> Similar to Morawa's findings,<sup>13</sup> the exfoliation of the pulpotomized teeth in this study has been enhanced in a considerable number of cases, but the succedaneous teeth were periodontally and morphologically normal. The mechanism of enhanced root resorption with use of

formaldehyde is not clearly understood. One explanation refers to a cell-mediated reaction to normal periodontal tissue by the formocresol irritant, thus initiating or potentiating external root resorption. The presence of chronic inflammation in pulpotomized teeth may also lead to early shedding in a pattern similar to that described for inflamed non-treated primary teeth.<sup>23</sup>

The present study, in addition to previous works<sup>9,11,13,14,16</sup> leads to the conclusion that the one-fifth dilution of formocresol may be an alternate medicament for primary vital pulpotomy procedures in children.

Drs. Fuks and Bimstein are lecturers, department of pedodontics, Hadassah Faculty of Dental Medicine, P.O.B. 12 000, Jerusalem, Israel. Requests for reprints should be sent to Dr. Fuks.

**Table 3.** Comparison of the resorption rate in pairs of pulpotomized primary teeth and their controls.

Resorption Rate of Pulpotomized Tooth	No. of Pairs	%
Same as control	19	46
Faster than control	16	39
Slower than control	6	15
Total	41	100

## References

- Lewis, T. and Law, D. B. Pulpal treatment in primary teeth, in *Clinical Pedodontics*, ed. Finn, S. B.: Philadelphia, W. B. Saunders Co., 1973, pp 201-223.
- Law, D. B. and Lewis, T. M. Formocresol pulpotomies in deciduous teeth, *JADA*, 69:601-607, 1964.
- Redig, D. F. A comparison and evaluation of two formocresol pulpotomy techniques utilizing Buckley's formocresol, *J Dent Child*, 35:22-30, 1968.
- Rolling, I. and Thylstrup, A. A 3 year clinical follow-up study of pulpotomized primary molars treated with the formocresol technique, *Scand J Dent Res*, 83:47-53, 1975.

5. Berger, J. E. Pulp tissue reaction to formocresol and zinc oxide eugenol, *J Dent Child*, 32:13-28, 1965.
6. Langeland, L. K., Dowden, W. and Langeland, K. Mummification, tissue disintegration, microbes, inflammation, and apposition, *J Dent Res*, 55 B:128, 1976.
7. Magnusson, B. O. Therapeutic pulpotomies in primary molars with the formocresol technique: a clinical and histological follow-up, *Acta Odont Scand*, 36:157-165, 1978.
8. Pulp therapy for primary teeth — Project TAPP, Quercus Corporation, 1978, p 13.
9. Loos, P. J., Straffon, L. H., and Han, S. S. Biological effects of formocresol, *J Dent Child*, 40:193-197, 1973.
10. Straffon, L. H. and Han, S. S. The effects of formocresol on hamster connective tissue cells, a histologic and quantitative radioautographic study with proline-H<sup>3</sup>, *Arch Oral Biol*, 13:271-288, 1968.
11. Straffon, L. H. and Han, S. S. Effects of varying concentrations of formocresol on RNA synthesis of connective tissues in sponge implants, *Oral Surg*, 29:915-925, 1970.
12. Loos, P. J. and Han, S. S. An enzyme histochemical study of the effect of various concentrations of formocresol on connective tissues, *Oral Surg*, 31:571-585, 1971.
13. Morawa, A. P., Straffon, L. H., Han, S. S., and Corpron, R. E. Clinical evaluation of pulpotomies using dilute formocresol, *J Dent Child*, 42: 360-363, 1975.
14. Escobar, R. F. Effects of diluted formocresol on monkey primary molar pulp, M. Sc. Thesis, University of Michigan, 1972, p 54.
15. Fuks, A. B., Bimstein, E. and Bruchim, A. Radiographic and histologic evaluation of the effect of two concentrations of formocresol on pulpotomized primary and young permanent teeth in monkeys, Sent for publication.
16. Garcia — Godoy, F. and Olivares, M. A. O. Pulp tissue reaction to diluted formocresol: histologic study in dogs, *Revista Dental (Santo Domingo)*, 20:15-27, 1977.
17. Wright, F. A. C. and Widmer, R. P. Pulpal therapy in primary molar teeth, a retrospective study, *J Pedod*, 3:195-206, 1979.
18. Schroeder, U. A 2-year follow-up of primary molars pulpotomized with a gentle technique and capped with calcium hydroxide, *Scand J Dent Res*, 86:273-278, 1978.
19. Granath, L. E. and Hagman, G. Experimental pulpotomy in human bicuspids with reference to cutting technique, *Acta Odont Scand*, 29: 155-163, 1971.
20. Willard, M. R. Radiographic changes following formocresol pulpotomy in primary molars, *J Dent Child*, 43: 414-415, 1976.
21. Laster, Z. A clinical evaluation of formocresol pulpotomies in deciduous teeth, DMD Thesis, Hadassah Faculty of Dental Medicine, Hebrew University, 1974.
22. Rolling, I. and Lambjerg, H. Pulp condition of successfully formocresol-treated primary molars, *Scand J Dent Res*, 86:267-272, 1978.
23. Obersztyn, A. Experimental investigation of factors causing resorption of deciduous teeth, *J Dent Res*, 42:660-674, 1963.

## Quotable Quote

In 1975, the results of studies reported in *Consumer Reports* showed that Maypo 30-Second Oatmeal, Cheerios and Special K were "far and away the most nutritious" of all cereals tested. Now, similar studies have once again been conducted, and the results are reported in the February *Consumer Reports*. Maypo 30-second Oatmeal and Cheerios once again took first place, along with Instant Quaker Oatmeal, All Bran, Familia, Kretschmer Sun Country Granola, Shredded Wheat and some others. Special K, however, was this time found to be only fairly nutritious, as were Froot Loops, Wheaties, Hearty Granola and other cereals. Corn Chex, Corn Flakes, Fruity Pebbles and Total were a few found to be the least nutritious.

Variations in ingredients, the authors of the studies report, make it difficult to pinpoint why certain cereals were found more nutritious than others, since wheat, oat, and corn cereals scored in both high and low categories. However, none of the rice cereals were found to be very nutritious. And while moderate vitamin and mineral fortification seemed to improve the nutritional qualities of the hot cereals, this was not so with the ready-to-eat cereals.

From: Science News, 119:7,  
February 14, 1981.