

## Clinical and radiographic assessment of direct pulp capping and pulpotomy in young permanent teeth

Anna B. Fuks, CD  
Simon Bielak, CD  
Aubrey Chosak, BDS, MSD

### Abstract

*Seventy-six vital permanent incisors with complicated crown fractures in 72 children were assessed clinically and radiographically for the healing of pulp exposures treated by direct pulp capping or by pulpotomy. Thirty-eight of these teeth had pinpoint exposures, complete roots, and were treated by pulp capping. Pulpotomy was the treatment for the other 38 teeth that had incomplete root development, regardless of the size of the exposure. A success rate of 92% was observed in the teeth which were treated by pulpotomy, and 81.5% was the success rate of those treated by direct pulp capping.*

**T**raumatic injuries resulting in pulp exposure in young patients present a challenge in treatment. The immediate objective would be the selection of a procedure designed to maintain the vitality of the pulp.<sup>1</sup> An exposed vital pulp can be treated by capping, pulpotomy, or pulpectomy, depending on several factors such as: degree of pulp exposure, the interval between the accident and examination, and the stage of root development. A partial pulpotomy technique has been recently described as another choice for successfully treating vital exposures.<sup>2</sup>

The exact indication of pulp capping has not yet been established. It is currently accepted that this treatment should only be performed in teeth where the exposure is confined to a small area, where exposure occurred not more than a few hours before, and when there are no associated injuries to the supporting structure.<sup>3</sup>

Incompletely formed teeth with vital pulps exposed by trauma that presented the above conditions have been also treated by pulp capping, but a vital pulpotomy has been considered the treatment of choice.<sup>4</sup> The rationale for pulpotomy is based on the assumption that inflammation and impaired vascularity caused by the injuries would be confined to

the superficial part of the coronal pulp, while the radicular pulp would be normal.<sup>3</sup>

It is important to emphasize that the pulpotomy procedure has been considered the first step in endodontic therapy.<sup>5</sup> When apical root formation is completed, a conventional root canal filling has been recommended, thus preventing calcific degeneration and obliteration of the pulp canal.<sup>6,7</sup> This has been accepted policy followed by both general practitioners and endodontists. Evidence of long-term successful outcome of vital pulpotomy has been presented by Bodenham.<sup>8</sup> Krakov et al., suggested that root canal treatment subsequent to pulpotomy which has resulted in completion of the root is indicated only when a post and core are required to adequately restore the tooth.<sup>5</sup>

The purpose of the current investigation was to assess clinically and radiographically the healing of pulp exposures treated by direct pulp capping or by pulpotomy, and the effect on the results of the interval between the accident and treatment.

### Methods and Materials

The study sample consisted of 76 vital permanent incisors with a complicated crown fracture in 72 children. These patients, whose age varied from 7 to 14 years, received emergency treatment at the Department of Pedodontics of the Hadassah Faculty of Dental Medicine in Jerusalem. Preoperative examination revealed that the teeth showed no mobility or slightly increased mobility, and all of them were sensitive to the electric pulp tester<sup>a</sup> stimulation. Pulp capping was performed in 38 teeth with pinpoint exposures and with complete roots; pulpotomy was the treatment of choice for another 38 teeth that had incomplete root development, regardless of the size

<sup>a</sup>Vitapulp: The Pelton & Crane Company, Box 3664, Charlotte, NC.

Table 1. Distribution of teeth treated by pulp capping with calcium hydroxide in traumatized incisors with closed apices.	Time elapsed from trauma to treatment	Number of teeth treated	Failures No. %	Successful follow up period in months				
				3-5	6-11	12-23	24-35	36+
	Up to 12 hrs.	13	2 15.4	2	5	1	1	2
	13 - 24 hrs.	17	3 11.1	2	4	5	2	1
	1 - 4 days	5	0 0	1	2	—	1	1
	5 - 7 days	3	2 66.6	1	—	—	—	—
	Total	38	7 18.5	6	11	6	4	4

of the exposure.

### The Techniques

**Pulp capping.** The teeth were isolated with cotton rolls, rinsed with saline and dried with cotton applicators. The exposure site was then covered by a calcium hydroxide paste (Calxyl<sup>b</sup> or Dycal<sup>c</sup>). A pinch band was fabricated and cemented with zinc oxide-eugenol cement to protect the pulp dressing and preserve arch length.

**Pulpotomy.** After local anesthesia, the teeth were isolated with a rubber dam and access to the pulp chamber was obtained with a pear-shaped N 330 carbide bur mounted on a high speed handpiece and cooled by water. Coronal pulp amputation was done at low speed using a sterile round bur. The amputation site was placed approximately at the level of the cemento-enamel junction, where the pulp canal shows a slight constriction. The wound surface was irrigated with a sterile saline solution, and hemorrhage was controlled by applying sterile cotton pellets. Calcium hydroxide (Calxyl<sup>b</sup>) was then applied to the amputation surface and covered by a zinc oxide-eugenol cement. A permanent filling (usually amalgam) was inserted to seal the access orifice to the pulp chamber.

The treatment was considered to be successful when the following criteria were observed:

1. Absence of clinical symptoms (pain, tenderness to percussion, swelling);
2. No intraradicular or periapical pathology could be detected radiographically;
3. Continued root development and the presence of a dentin bridge;
4. In cases of direct pulp capping, a continuous hard tissue barrier determined by direct clinical examination and a positive response to electric pulp tester stimulation. Radiographs were of little value in determining the presence of a dentin bridge.

### Results

The success rate of direct pulp capping in traumatized incisors with closed apices can be observed in Table 1. From a total of 38 pulp capped teeth 7(18.5%) became necrotic; among these, 5 were treated within 24 hours after the accident. In only

one case, pulp necrosis occurred as early as one week after treatment; in 4 cases, necrosis was observed 2 or 3 months after pulp capping, and in the last 2 cases, necrosis appeared after 6 and 7 months. Figure 1 shows a central incisor prior to direct pulp cap-

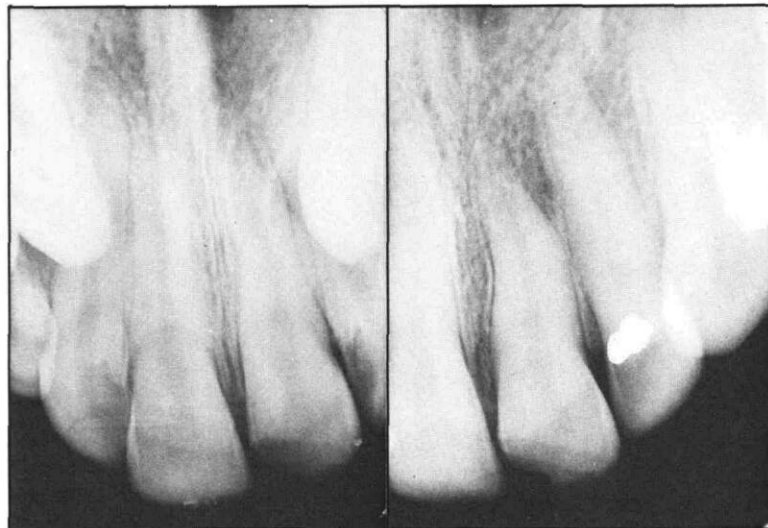

Figure 1. Upper central incisor with complicated crown fracture treated by direct pulp capping: (a) immediately before pulp capping, (b) 52 months after pulp capping.

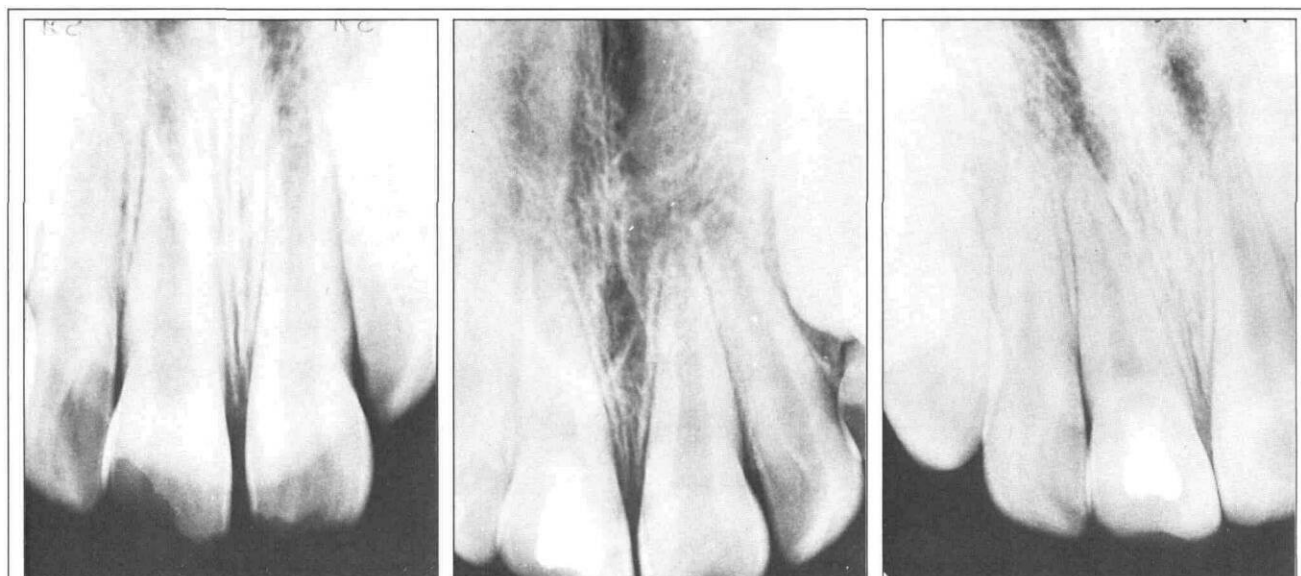
ping 52 months after treatment. The binomial distribution was used to calculate the probability of failure under each of two models. Model I assumed that the probability of failure ( $\pi_{PH0}^{(x)}$ ) does not depend on the time interval between accident and treatment; model II assumed that the probability of failure ( $\pi_{PH1}^{(x)}$ ) is different in different time intervals. The results of the binomial distribution was  $\pi_{PH0}^{(x)} = 0.00208$  and  $\pi_{PH1}^{(x)} = 0.0322$ . This difference was non-significant at a 5% level.

The outcome of 38 immature permanent incisors with complicated crown fractures treated by a calcium hydroxide pulpotomy is presented in Table 2.

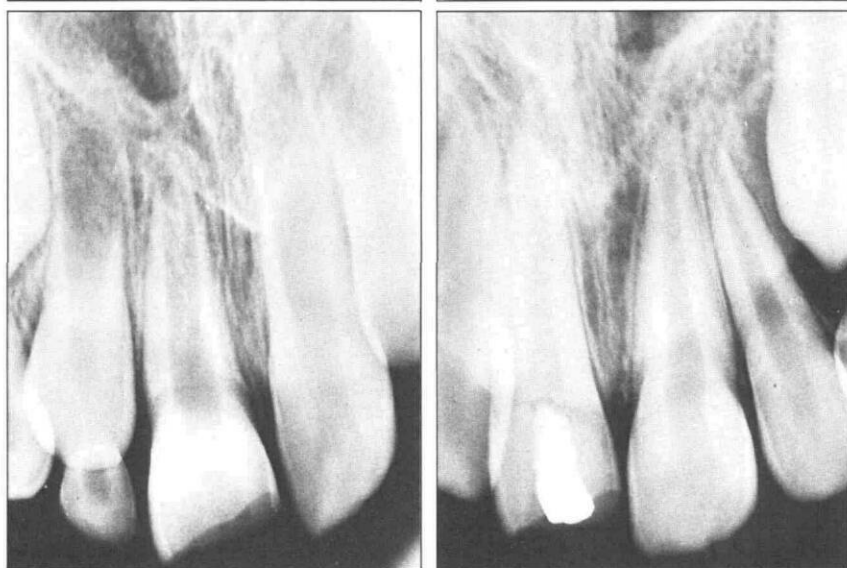All but two of the teeth were vital, as assessed by continued root formation and apical closure (Figures 2 & 3). Of these, one became necrotic 3 weeks, and the other 6 months, after the emergency treatment. Another tooth had a pulp canal obliteration, but no periapical pathology could be observed radiographically 4½ years postoperatively (Figure 4).

<sup>b</sup>Calxyl: Dental Preparation, Otto & Co. Frankfurt/Main - W. Germany

<sup>c</sup>Dycal: The L. D. Caulk Company, Division of Dentistry, International Inc. Milford, DW.



**Figure 2.** (Above, left to right) Upper central incisor with complicated crown fracture treated by pulpotomy: (a) immediately before treatment — notice the incompletely formed root and the wide open apex, (b) 15 months after treatment — a dentin bridge is evident and the root apex is almost closed, (c) 5½ years after the pulpotomy; no pathology is observed.



**Figure 3.** (At right) Upper central incisor with complicated crown fracture treated by pulpotomy: (a) immediately before treatment — the root is incompletely formed and the apex is wide open, (b) 25 months after treatment — the root is fully formed and the apex is closed.

This tooth was listed as a failure although there were no other clinical signs or symptoms.

The binomial distribution was similarly used to evaluate the probability of failure as related to the time interval between accident and treatment. The findings were  $\pi\text{PH0}^{(x)} = 0.000968$  and  $\pi\text{PH1}^{(x)} = 0.2938$ , this difference being non-significant at a 5% level.

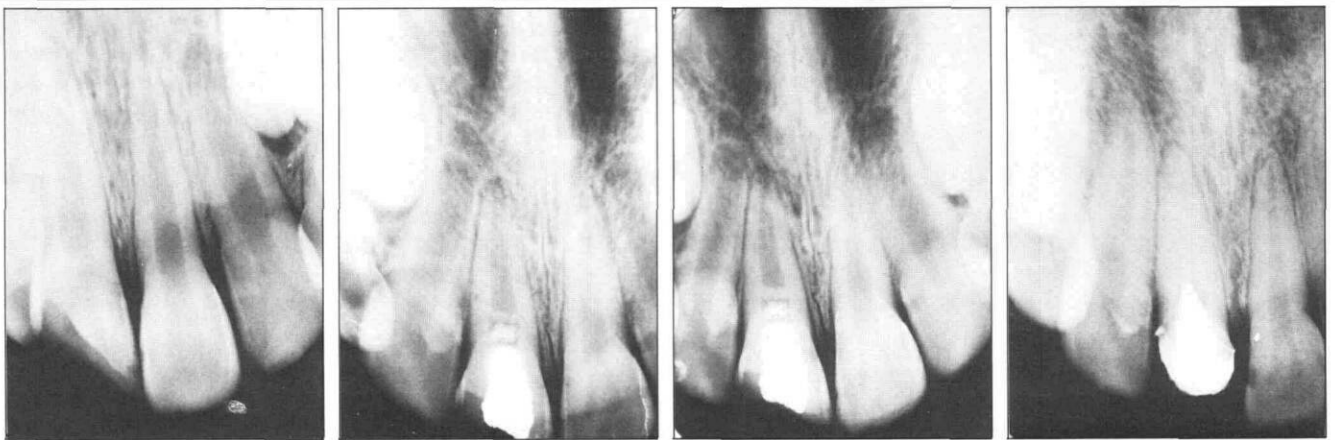## Discussion

The treatment of complicated crown fractures may involve either pulp capping, pulpotomy, or partial pulpectomy.<sup>3</sup> Direct pulp capping has been indicated in cases of pinpoint exposures that occurred not more than a few hours before, without special consideration to the degree of root development.<sup>3</sup> The primary objective in the treatment of an incompletely formed tooth in which the pulp has been exposed, is to induce continued root formation.

A succession of cases in which there was pulp

necrosis following direct pulp capping, and the poor prognosis of a non-vital young permanent incisor with only a partially developed root and wide open apex, caused a change of treatment policy here some eight years ago. We felt that some of the failures of pulp capping may have been due to contamination of the pulp at the time of, or following trauma which was impossible to diagnose clinically. We also felt that debridement by pulpotomy technique might give a higher success rate. Because of the importance of continued vitality in teeth with underdeveloped roots, pulpotomy with calcium hydroxide became the treatment of choice in these cases.

The growing use of the apexification technique,<sup>3</sup> although allowing for adequate conventional root canal filling, still leaves a root with thin dentin walls and a poor long-term prognosis. The failure rate for teeth treated by pulpotomy is low, and the percentage of pulp necrosis in this study (5%), is even lower than the ones described in the literature.<sup>6,9</sup> The inter-



**Figure 4.** Complicated crown fracture in upper central incisor treated by pulpotomy followed by complete obliteration of the root canal (left to right): (a) preoperative radiograph taken before treatment, revealing an immature tooth, (b) a dentin bridge was already evident 4 months postoperatively, (c) 10 months after treatment — notice the presence of a thick dentin bridge; the root apex is almost closed, (d) complete obliteration of root canal is evident 4½ years after pulpotomy.

val between the accident and treatment does not seem to be critical for healing (Table 2). This confirms the conclusions of Cvek, who utilized a partial pulpotomy technique.<sup>2</sup> The present results are based on a rather small number of cases however; it is possible that with a larger sample the time interval may become statistically significant.

In germ-free animals it has been demonstrated that the major determinant in the healing of exposed rodent pulps, was the presence or absence of microbial flora.<sup>10</sup> In the case of pulpotomy, the dressing is placed within the confines of the pulp chamber, and not over a contaminated exposed pulp. Although it has been shown experimentally that traumatized pulp tissue may become infected by bacteria reaching the pulp via the blood stream, unexposed tissue is less liable to be infected.<sup>11</sup> Good clinical results in the different studies seems to justify this hypothesis.<sup>6-10</sup>

In a pulpotomy, the calcium hydroxide paste is protected by a cement base, and therefore the remaining pulp is less liable to become contaminated, even when the temporary filling is lost. In cases of pulp capping, the loss of a temporary restoration would result in the loss of the dressing and recontamination, and would consequently lead to a possible failure. In teeth with fully developed roots, failure of a pulp capping would still allow for a favorable prog-

nosis following good endodontic therapy.

Pulpotomy has been advocated as an interim treatment — a conventional root filling has been recommended when root formation is completed. Degenerative changes like pulp calcifications, fibrosis, or dry gangrene have been the justification of such a policy.<sup>6</sup> Another reason why many endodontists routinely perform endodontic therapy in the cases mentioned above, is that the dentin bridges formed may contain dead tracts, and are not always completely calcified.<sup>12</sup> Complete hard tissue barriers protect and keep the pulps free of inflammation, but several degrees of inflammation have been described under incomplete bridges in monkey teeth.<sup>13</sup> The fact that dead tracts and porosity have been observed histologically in these bridges is not of clinical significance, and therefore routine endodontic therapy would not be indicated.<sup>4,14</sup> In the case presented in Figure 2, despite the fact that almost total obliteration of the root canal occurred, no periapical pathology was observed. Tendency to obliteration was not found in any of the other thirty-five successful cases.

### Conclusion

Pulpotomy should not be considered an interim treatment that should be followed by a complete root

Table 2. Distribution of teeth treated by pulpotomy with calcium hydroxide in traumatized incisors with open apices.	Time elapsed from trauma to treatment	Number of teeth treated	Failures No. %	Successful follow up period in months			
				6 - 11 No.	12 - 23 No.	24 - 35 No.	36+ No.
	Up to 1 day	23	0 —	2	6	6	9
	2 - 6 days	7	3 —	1	2	1	0
	7 - 13 days	4	0 —	1	—	—	3
	14+ days	4	0 —	1	1	—	2
	Total	38	3 7.9	5	9	7	14

filling. Regular periodical radiographic check-ups should be performed in order to disclose any pathology that might eventually develop.

Direct pulp capping failed in 18.5% of the cases so treated. However, it is still an acceptable treatment for traumatic exposures in teeth with fully formed roots, as these teeth have a good prognosis following root canal therapy if pulp capping fails.

Dr. Fuks is lecturer, Dr. Bielak is assistant, and Dr. Chosak is associate professor, Department of Pedodontics, Hadassah Faculty of Dental Medicine — Hebrew University, Jerusalem — Israel, PO Box 12 000. Requests for reprints should be sent to Dr. Fuks.

1. McDonald, R. E. Management of traumatic injuries to the teeth and supporting tissues, in *Dentistry for the Child & Adolescent*. The C. V. Mosby Company, Saint Louis, 1974, pp 287-323.
2. Cvek, M. A clinical report of partial pulpotomy and capping with calcium hydroxide in permanent incisors with complicated crown fractures. *J Endo* 4:232, 1978.
3. Andreasen, J. O. Crown fractures, in *Traumatic Injuries to the Teeth*. Munksgaard, Copenhagen, Denmark, 1972, pp 79-88 and 167-169.
4. Krakow, A. A., Berk, H., and Gron, P. Therapeutic induction of root formation in the exposed incompletely formed tooth with vital pulp. *Oral Surg, Oral Med, Oral Path* 43:755, 1977.
5. Patterson, S. S. Pulp calcification due to operative procedures - pulpotomy. *Int Dent J* 17:409, 1967.
6. Hallett, G. E. M. and Porteous, J. R. Fractured incisors treated by vital pulpotomy — a report on 100 consecutive cases. *Brit Dent J* 115:279, 1963.
7. Goldmann, M. Root-end closure techniques including apexification. *Dent Clin N Am* 18:297, 1974.
8. Bodenham, R. S. The prognosis for vital pulpotomy of traumatized permanent incisors. *Dent Practit* 17:327, 1967.
9. Kisling, E. Om Behandlingen a skader som folge af acutte mekaniske traumer pa unge permanente incisiver. *Tandlaegebladet* 57:61 and 109, 1953.
10. Kakehashi, S., Stanley, H. R., and Fitzgerald, R. J. The effects of surgical exposures of dental pulps in germ-free and conventional laboratory rats. *Oral Surg, Oral Med, Oral Path* 20:340, 1965.
11. Burke, G. W. and Knighton, H. T. The localization of microorganisms in inflamed dental pulp of rats following bacteremia. *J Dent Res* 39:205, 1960.
12. Langeland, K., Dowden, W. E., Tronstad, L., and Langeland, L. K. Human pulp changes of iatrogenic origin. *Oral Surg, Oral Med, Oral Path* 34:944, 1972.
13. Holland, R., Souza, V., Mello, W., Nery, M. J., Bernabe, P. E. E., and Otoboni, J. A. Permeability of the hard tissue bridge formed after pulpotomy with calcium hydroxide: a histologic study. *JADA* 99:472, 1979.
14. Berk, H. and Krakow, A. A. A comparison of the management of pulpal pathosis in deciduous and permanent teeth. *Oral Surg, Oral Med, Oral Path* 34:944, 1972.

## Quotable Quote

The issue (evolution) was seen by Darwin's defenders, such as T. H. Huxley, as a straight conflict between bigotry and enlightened rationalism. Darwin's theory was misinterpreted as a vindication of the political doctrine that a policy of laissez-faire will inevitably result in Progress with a capital 'P': on and on and on and on and up and up and up. What Darwin's theory really said was that species tend to become adapted to increasingly specialized environments; it was not concerned with the notion of 'Progress' at all. Yet one still encounters biologists who refer to 'advanced' and 'primitive' species and who are quite evidently predisposed to think that mankind can be sub divided into 'advanced' and 'primitive' 'races', 'cultures' or what have you. Needless to say it is 'we' who are 'advanced', 'we' being the particular human collectively to which the author himself happens to belong.

From: Leach, E. R. Men, Bishops and Apes. *Nature*, 293:19-21, September 3, 1981.