

Radiographic and histologic evaluation of the effect of two concentrations of formocresol on pulpotomized primary and young permanent teeth in monkeys

Anna B. Fuks, DDS
Enrique Bimstein, DMD
Avraham Bruchim, DVM

Abstract

The behavior of pulp tissue under two concentrations of formocresol was evaluated radiographically and histologically in pulpotomized primary and young permanent monkey teeth. A faster resorption rate of the roots of the treated primary teeth was observed with both concentrations. Evidence of vital tissue as expressed by continued root development was observed in the permanent teeth of both treated groups, but a milder degree of inflammation was seen in the diluted concentration group.

Controversial findings have been reported concerning pulp reaction following formocresol pulpotomy treatment.¹⁻⁸ Histologic investigations describe several pulpal changes ranging from the ingrowth of connective tissue through the root apex to total coagulation of the pulp and necrosis.^{2,9-11} The presence of vital tissue in pulpotomized primary molars treated with formocresol has been demonstrated previously.^{12,13} Despite this fact, there is no uniform reaction to formocresol, and a "very capricious behavior" of the pulp under formocresol has been described.¹⁰ Straffon tested the effect of formocresol on hamster connective tissue cells and observed a definite reduction in the number of inflammatory cells and a faster recovery of the tissue with decreased formocresol concentrations.¹⁴ Further biochemical and histochemical investigations confirmed these results.^{15,16} From these studies it became evident that a 20% dilution was the most favorable, being as effective as the full concentration and yet allowing a faster recovery of the affected cells.¹⁵⁻¹⁷ Escobar tested the effect of a 20% dilution of formocresol on monkey primary molars and suggested that this could be an alternate medicament for primary vital pulpotomy procedures.¹⁸ Morawa et al. tested this medicament clinically in primary teeth of

children and concluded that it was equal or even better than the full strength formocresol.^{18,19}

The continued apical formation of immature permanent teeth treated with formocresol has been studied previously.²⁰ This investigation has been carried out in periods of time not exceeding 150 days. It is generally believed that the success rate of formocresol pulpotomies decreases with time.²¹

The purpose of the present investigation was to evaluate the long-term effects of pulpotomies with two concentrations of formocresol upon the root resorption of primary molars, and the continued apical formation of immature permanent teeth in the rhesus monkey.

Methods and Materials

Two rhesus monkeys approximately 20 months old were used in this study. Both had noncarious primary molars; the first permanent molars and the permanent incisors had erupted at the beginning of the experiment. The animals were anesthetized by a pentothal solution IV (50 mg per kg bodyweight). Preoperative periapical radiographs taken immediately before treatment revealed both the stage of root resorption of the primary molars and the degree of root development of the permanent teeth. The latter had incomplete roots and their apices were wide open (Figure 1a). Pulpotomies initially were performed in all the primary molars and in the permanent first molars and central incisors. Subsequently, the other permanent teeth were treated in groups, as soon as the erupting teeth provided enough clinical crown to allow placement of a rubber dam. Each monkey was treated four times.

Pulpotomy procedure

The one-appointment pulpotomy treatment was used. All cavity preparations were made under rubber dam and with burs mounted in a conventional speed hand-

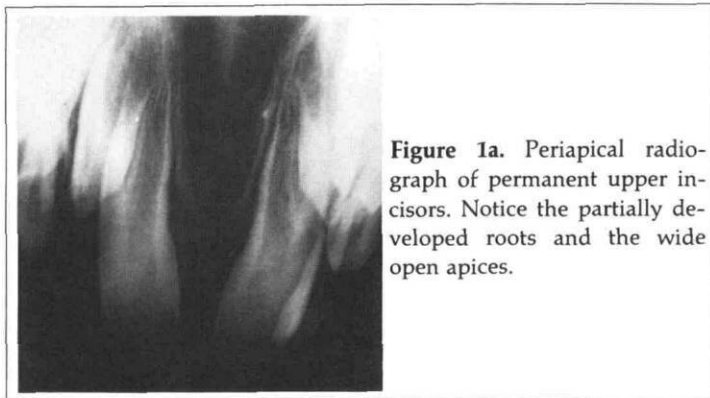


Figure 1a. Periapical radiograph of permanent upper incisors. Notice the partially developed roots and the wide open apices.

Table 1. Distribution of the Pulpotomized Teeth According to Utilized Formocresol Solution

Formocresol solution used	Type of tooth		Total
	Primary	Permanent	
Full strength	4	12	16
20% dilution	4	10	14
Total	8	22	30

observed. Root development and closure of the apices of the treated permanent teeth with both of the formocresol dressings was similar to the untreated controls.

A dentin bridge was evident in five of the seven treated anterior teeth; just above it, and below the formocresol dressing, a narrow radiolucent band was present (Figure 1b). No bridging could be noticed in the posterior teeth. Partial obliteration of the pulp canals could be observed in both treated groups (Table 2). Surprisingly, signs of internal resorption were found replacing the dentinal bridge of three of the upper treated anterior teeth approximately 18 months after pulpotomy was performed (Figure 2). Four months after treatment (and normal root development) one permanent molar fractured, the amalgam restoration was lost, and periapical and furcation radiolucent areas were evident.

Histologic findings

No characteristic pattern of pulp tissue response to the two concentrations of formocresol could be observed (Table 3). All but one of the teeth were vital, as demonstrated by continued root development, but only two teeth presented with apparently healthy pulp tissue, both treated with diluted formocresol (Figures 3a & 3b). No areas of fixation was observed, but necrosis was evident in the tissue in direct contact with the formocresol. Below it, in three teeth treated with diluted formocresol and in two treated with the full concentration, a reparative

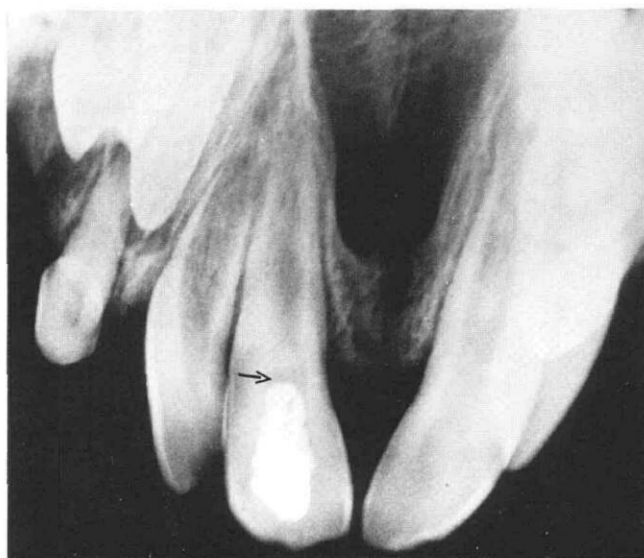


Figure 1b. Periapical radiograph of pulpotomized permanent maxillary central incisor showing a normally developed root, an almost closed apex and a dentin bridge. Note the radiolucent area between the bridge and the formocresol dressing.

piece. After the dentin roofs were removed, the teeth were irrigated with sterile saline in order to remove the debris. The coronal pulps were amputated with fresh sterile round burs, and cotton pellets moistened with sterile saline were placed over the pulp stumps to effect hemostasis. After blood clots developed, the pellets were removed and the medicaments were inserted by the following steps. Cotton pellets moistened with either a full^a or diluted^b formocresol liquid were placed in contact with the pulp stumps for five minutes. Excess liquid was removed by compressing the cotton pellet against a sterile towel. Creamy mixtures made of zinc oxide powder mixed with equal amounts of eugenol and the selected formocresol liquids were placed over the pulp stumps, covered by a base of zinc oxide-eugenol and restored with silver amalgam.

A total of 12 permanent and 4 primary teeth were treated with formocresol (full concentration), while 10 permanent and 4 primary teeth were treated with the 20% dilution formocresol (Table 1). Each treated tooth had its contralateral nontreated control. Follow-up radiographs were secured to observe the degree of root resorption of the primary teeth, the stage of root development of the permanent teeth, and the presence of eventual pulpal or periapical pathoses. The treated and control primary teeth were left to exfoliate so as to observe the effect of pulpotomy on the root resorption rate. The monkeys were sacrificed 22 and 24 months, respectively, after the initial treatment. Maxillectomy and mandibulectomy were performed and each jaw was divided into three fragments. These blocks were decalcified, embedded in paraffin and serial sections of the treated and control permanent teeth were made for histological examination.

Results

Radiographic findings

Clinical and radiographic examination revealed a faster root resorption rate of the treated primary molars as compared to their controls. No appreciable difference could be noted between the two formocresol dressings, and no signs of pulpal or periapical pathoses were

^a Formocresol (Buckley's formula), King Specialty Co., Fort Wayne, Ind.

^b Buckley's formula diluted as described by Morawa et al.¹⁹

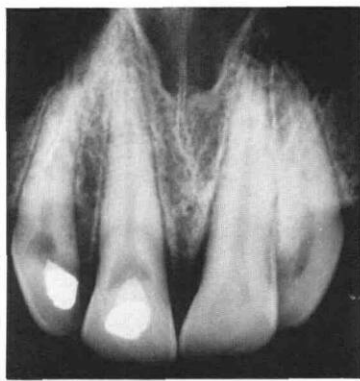


Figure 2. An 18-month post-treatment radiograph of treated central and lateral incisors which shows areas of internal resorption replacing the dentin bridges.

dentin bridge was seen. The dentin at the bridge area was irregular and atubular, in contrast with the pre-existing tubular dentin of the canal walls. The odontoblastic layer below the dentin bridge appeared regular, but the odontoblasts were flattened. This was in contrast with those along the pulp canal, which had a columnar (normal) appearance. All other treated teeth exhibited different degrees of hard tissue apposition, hyperemia, inflammatory cell infiltrate, and fibrosis, with no relation to time after treatment or to the formocresol concentra-

Table 2. Effect of Full Concentration of Formocresol Versus a 20% Dilution on Pulpotomized Permanent Teeth in Monkeys: Radiographic Findings

	Formocresol solution	
	Full	20% dilution
Number of teeth treated	12	10
Normal root development	12	10
Dentin bridge	2	3
Internal resorption	1	2
Partial root obliteration	5	6
Inter-radiolar radiolucency	1	—
Periapical lesion	1	—

tion used. Also, fibrosis was observed in nontreated teeth (Figure 4). Areas of necrosis were present in five teeth, four of them treated with the full concentration formocresol liquid; the frequency of severe inflammation and advanced fibrosis was higher in the full concentration group (Figure 5). Chronic total pulpitis with liquefaction necrosis and a periapical granuloma was present in one tooth of the diluted formocresol group (Figure 6). Osteodentin was seen in areas of pulp obliteration in both treated groups. Dentin formation after treatment was irregular and atubular, but a definite calcio-traumatic line was not clearly visible.

Discussion

The important point illustrated by this experiment based on clinical and radiographic observation, was that pulp vitality was maintained and normal root development followed by apical closure was evident in all immature treated teeth. This is in agreement with Sanchez's findings in shorter postoperative intervals.²⁰

Table 3. Effect of Full Concentration of Formocresol Versus a 20% Dilution on Pulpotomized Permanent Teeth in Monkeys: Histologic Findings

	Formocresol solution	
	Full	Diluted
Number of teeth treated	12	10
Normal pulp	0	2
Regular odontoblastic layer	0	2
Fibrosis	5	3
Severe inflammation	5	2
Mild inflammation	0	5
Osteodentine	2	6
Areas of necrosis	4	1
Granulation tissue	0	1
Periapical granuloma	1	0

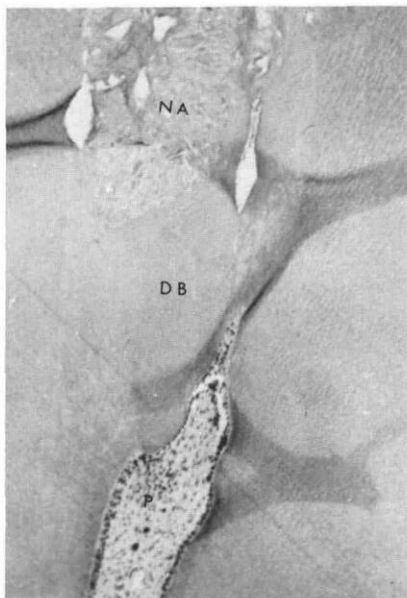
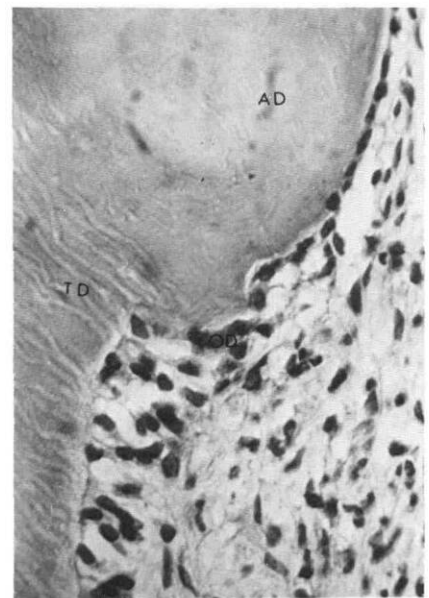

Figure 3a. (left) Photomicrograph of a lateral incisor 21 months after treatment with diluted formocresol. Observe the necrotic area (NA) that was in contact with the formocresol, below it a dentin bridge (DB), and next to it an apparently normal pulp (P) (5x).

Figure 3b. (right) A higher magnification of the same tooth showing the presence of atubular dentin (AD) at the bridge site, regular pre-existing tubular dentin (TD). Notice the flattened odontoblasts (OD) underneath the dentin bridge (40x).



The formation of reparative dentin is part of the repair process that occurs whenever there is pulp injury. When inflammation takes place, repair accompanies it. Dentin bridges have been observed mainly under calcium hydroxide dressings, but a marked reparative dentin reaction was described by Sanchez using a full concentration of formocresol in immature monkey permanent teeth.^{20,22} This reaction also was observed by Escobar in pulpotomized monkey primary teeth using a diluted concentration, but not seen in other teeth treated with full strength formocresol.¹⁸ In the present study, although dentin bridges were visible only in the anterior teeth treated with both concentrations, deposition of reparative dentin along the canal walls also was present in nine posterior teeth; two of them treated with full concentration. Dentinal deposition in response to formaldehyde has been demonstrated by Rolling et al. and by Peron et al. in rhesus monkeys, and by Willard in primary teeth of children treated by a formocresol pulpotomy.^{13,23,24}

Long-term follow-up radiographs disclosed signs of internal resorption at the dentin bridge area that could be interpreted as the result of chronic inflammation.²⁵ This finding could be the response to a traumatic pulpotomy technique with rotating instruments, to an extrapulpal blood clot, or to the toxicity of the formocresol.^{15,16,26-28} Dentinal resorption followed by a deposition of hard tissue on the root canal has been described by Rolling et al. as the most typical process taking place in

primary molars successfully treated with formocresol.²⁵ In Rolling's study, pulpal changes were observed in all teeth, but complete *in vivo* formaldehyde tissue fixation as previously described was not observed.² Our findings also reveal a wide range of pulpal changes but no tissue destruction or periapical lesions were evident, as previously reported.¹¹ It has been suggested that protein fixation in formocresol pulpotomies can be a function of the strength of the medicament. Both a full concentration and a 20% dilution suppressed protein biosynthetic activities in bovine pulps, but the latter allowed for eventual tissue recovery.^{15-17,28,29} The present findings, confirming those of Sanchez, reveal that the damage to the pulp caused by both formocresol concentrations did not impair root development.²⁰ Although inflammation was present in both groups, in the 20% dilution it was less severe, in agreement with previous studies.^{18,19}

Conclusions

A faster resorption rate of the roots of the treated primary teeth was observed with both concentrations. Follow-up radiographs of permanent teeth during the first year revealed a favorable response to formocresol pulpotomy with both concentrations; root development continued and the apices closed. Microscopic evidence of pulpal pathosis expressed as internal resorption was seen at a later date. Histologically, neither of the concentrations produced ideal results, but a milder degree of inflammation was seen in the diluted group.

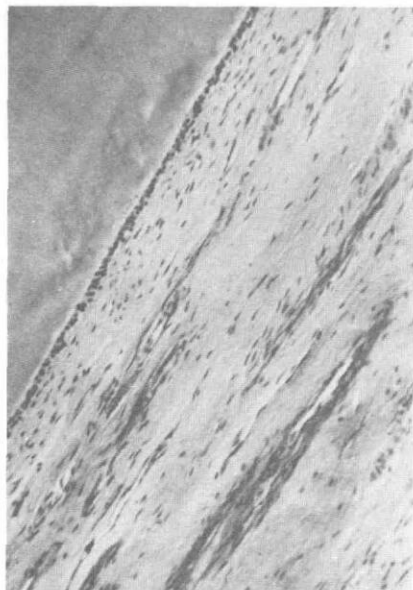


Figure 4. Photomicrograph of untreated upper permanent incisor showing a fairly high amount of fibers (10x).

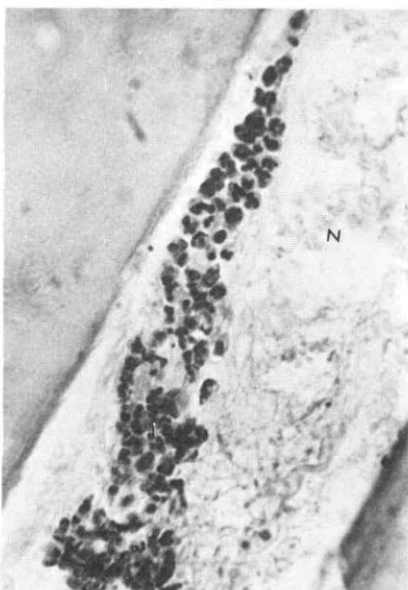


Figure 5. Photomicrograph of the root of a lower premolar 17 months after treatment with the full concentration of formocresol. Notice the presence of necrotic areas (N) and an inflammatory cell infiltrate (I) (40x).

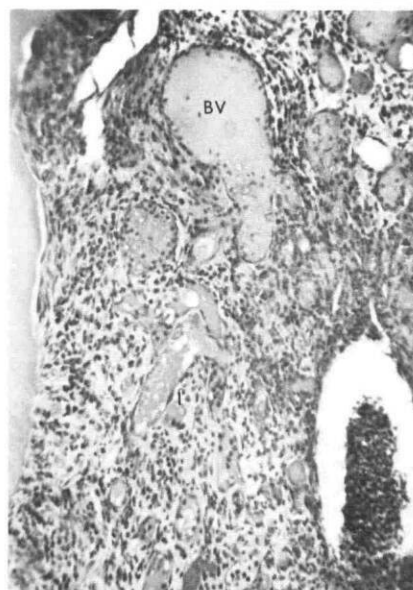


Figure 6. A magnification of the periapical area of a lower permanent molar 24 months after treatment with the full concentration showing a heavy inflammatory infiltrate (I) and enlarged blood vessels (BV) (5x).

This study reinforces Escobar's suggestion that a 20% formocresol concentration may be an alternate medication for clinical pulpotomy procedures.¹⁸

We thank the laboratory personnel of Oral Pathology for the preparation of the histologic sections and photographs.

Drs. Fuks and Bimstein are lecturers, Department of Pedodontics; and Dr. Bruchim is lecturer, Department of Comparative Medicine, Hadassah Faculty of Dental Medicine, POB 12 000, Jerusalem, Israel. Reprint requests should be sent to Dr. Fuks.

1. Beaver, H.A., Kopel, H.M., Sabes, W.R. The effect of zinc oxide-eugenol cement on a formocresolized pulp. *J Dent Child* 33:381-96, 1966.
2. Berger, J.E. Pulp reaction to formocresol and zinc oxide-eugenol. *J Dent Child* 32:13-28, 1965.
3. Boller, R.J. Reactions of pulpotomized teeth to zinc oxide and formocresol-type drugs. *J Dent Child* 39:52-60, 1972.
4. Doyle, W.A., McDonald, R.E., Mitchell, D.F. Formocresol versus calcium hydroxide in pulpotomy. *J Dent Child* 29:86-97, 1962.
5. Redig, D.F. A comparison and evaluation of two formocresol pulpotomy techniques utilizing "Buckley's" formocresol. *J Dent Child* 35:22-30, 1968.
6. Law, D.B. An evaluation of vital pulpotomy technique. *J Dent Child* 23:40-44, 1956.
7. Law, D.B., Lewis, T.M. Formocresol pulpotomies in deciduous teeth. *JADA* 69:601-7, 1964.
8. Spedding, R.H., Mitchell, D.F., McDonald, R.E. Formocresol and calcium hydroxide therapy. *J Dent Res* 44:1023-34, 1965.
9. Massler, M., Mansukhani, N. Effects of formocresol on the dental pulp. *J Dent Child* 26:277-97, 1959.
10. Magnusson, B.O. Therapeutic pulpotomies in primary molars with the formocresol technique. A clinical and histological follow-up. *Acta Odontol Scand* 36:157-65, 1978.
11. Langeland, L.K., Dowden, W., Langeland, K. Formocresol, "mummification," tissue disintegration, microbes, inflammation, resorption and apposition. *Int Assoc Dent Res Miami, Program Abstract no. 268*, 1976.
12. Rolling, I., Hasselgren, G., Tronstad, L. Morphologic and enzyme histochemical observations on the pulp of human primary molars three to five years after formocresol treatment. *Oral Surg* 42:518-28, 1976.
13. Rolling, I., Melsen, B. Dentin formation in formocresol pulpotomized primary monkey teeth studied by tetracycline and H³-proline incorporation. *Scand J Dent Res* 87:403-14, 1979.
14. Straffon, L.H., Han, S.S. The effects of formocresol on hamster connective tissue cells, a histologic and quantitative radioautographic study with proline-H³. *Arch Oral Biol* 13:271-88, 1968.
15. Straffon, L.H., Han, S.S. Effect of varying concentrations of formocresol on RNA synthesis of connective tissue in sponge implants. *Oral Surg* 29:915-25, 1970.
16. Loos, P.J., Han, S.S. An enzyme histochemical study of the effect of various concentrations of formocresol on connective tissues. *Oral Surg* 31:571-85, 1971.
17. Loos, P.J., Straffon, L.H., Han, S.S. Biological effects of formocresol. *J Dent Child* 40:193-97, 1973.
18. Escobar, R.F. Effects of diluted formocresol on monkey primary molars pulp. MSc. Thesis, University of Michigan, 1972, p 54.
19. Morawa, A.P., Straffon, L.H., Han, S.S., Corpron, R.E. Clinical evaluation of pulpotomies using dilute formocresol. *J Dent Child* 42:360-63, 1975.
20. Sanchez, Z.M.C. Effects of formocresol on pulp-capped and pulpotomized permanent teeth of rhesus monkeys. MSc Thesis, University of Michigan, 1971, p 55.
21. Rolling, I., Thylstrup, A. A three-year clinical follow-up study of pulpotomized primary molars treated with the formocresol technique. *Scand J Dent Res* 83:47-53, 1975.
22. Seltzer, S., Bender, I.B. *The dental pulp*, 2nd ed. J.B. Lippincott, 1975, p 259.
23. Peron, L.C., Burkes, E.J., Gregory, W.B. Vital pulpotomy utilizing variable concentrations of paraformaldehyde in rhesus monkeys. *Int Assoc Dent Res Miami, Program Abstract no. 269*, 1976.
24. Willard, R.M. Radiographic changes following formocresol pulpotomy in primary molars. *J Dent Child* 46:414-15, 1976.
25. Rolling, I., Hansen-Lambjerg, H. Pulp condition of successfully formocresol-treated primary molars. *Scand J Dent Res* 86:267-72, 1978.
26. Granath, L.E., Hagman, G. Experimental pulpotomy in human bicuspid with reference to cutting technique. *Acta Odontol Scand* 29:155-63, 1971.
27. Schröder, U., Granath, L.E. On internal dentine resorption in deciduous molars treated by pulpotomy and capped with calcium hydroxyde. *Odontol Revy* 22:179-88, 1971.
28. Lazzari, E.P., Walker, W.A. Biochemical effects of formocresol on bovine pulp tissue. *Oral Surg* 45:796-802, 1978.
29. Garcia-Godoy, F., Olivares, M.A.O. Pulp tissue reaction to diluted formocresol. Histologic study in dogs. *Revista Dental (Santo Domingo)* 20:15-27, 1977.

Quotable Quote

A consensus development conference was held at the National Institutes of Health on "Defined Diets and Hyperactivity"—an emotionally charged topic if ever there was one. A vocal contingent of physicians and families of hyperactive children contend that "defined diets," which are free of artificial colors, flavors, and preservatives, are an effective treatment for childhood hyperactivity. An equally vocal contingent of medical researchers assert that the diets' effects, if there are any, should be ascribed to faith healing.