

Oral actinomycosis in children: case reports

Frances B. Glenn, DDS Donald D. Doughty, DDS

Abstract

Actinomycosis of the oral cavity, specifically at the crown level of teeth, is rare in children. If left untreated, the disease can be fatal. The lesion is a granuloma in which suppuration has occurred with the Actinomyces israelii bacterium as the primary causative organism. There are distinct granules visible clinically in the lesion which are microcolonies of the bacteria. The lesion may appear as an acute abscess for which there is no apparent reason and teeth adjacent to the lesion may be caries and restoration free. The abscess contains an abundance of lymphocytes, plasma cells, macrophages, and occasional multinucleated giant cells. The disease is treated by excision biopsy and large, long-term doses of penicillin or tetracycline. Proper management involves a team approach with the patient's pediatrician. The diagnosis, treatment, and management of 2 female patients, ages 9 and 10 years, are described.

Oral actinomycosis in children is rare due to the prevalent use of antibiotics. Before 1950 it was seen more frequently in male patients, 20 years or older.¹

Prior to antibiotics, the organism *Actinomyces bovis* was found in orofacial lesions. The predominant organism now seen in patients is *Actinomyces israelii*, with a few lesions containing *A. naeslundii*, *A. eriksonii*, *A. dentolyticus*, and *A. propionica*, which cannot be distinguished histopathologically from *A. israelii*.²

In children, tonsil and adenoid problems, dental calculus, epuli, trauma, and deep dental caries have been described in the literature as endogenous sources from which a lesion may arise. Actinomyces organisms can be isolated in 11-14% of excised tonsils. If an oral lesion is left untreated, it can become resistant to therapy and the outcome may be fatal.^{3,4}

VonLangerbeck in 1845 was the first to discover this fungus-like bacterium, and Israel, in 1878, recognized and described the actinomycete in human

disease.¹ The lesion is a granuloma in which suppuration has occurred and the pus contains visible granules which microscopically show a center of closely meshed filamentous networks with a border of radially arranged structures often ending in club-shaped bodies which are regarded as hyaline thickening of the sheaths of the threads. The lesion varies from that of an acute abscess with an abundance of lymphocytes, plasma cells, macrophages, and occasional multinucleated giant cells. The more chronic lesion contains proliferating connective tissue as the most conspicuous feature. Bony involvement may occur with trismus and swelling in the region of the angle or ramus of the mandible. Abscess formation with erosion of the cortex leads to bone resorption. The skin, neck, scalp, pleura, lungs, and the abdomen may develop lesions. Tokiwa and Yoshiya in 1950 described a case of actinomycosis of the jaw with metastases to the brain.⁵

Actinomycosis may occur at any age, but it is most frequently reported in young adults and is more than twice as prevalent in males than in females.²

Case Report: Patient 1

A 10-year-old Caucasian female was seen for posterior orthodontic banding and anterior bracket bonding. The patient had been seen 3 weeks prior for a routine dental checkup. At the visit, a soft tissue mass of about 8 mm extended over the distobuccal cusp of the mandibular right first permanent molar. The patient was unaware of its presence. The visit was interrupted to take a panoramic radiograph which disclosed a radiolucent area at the distogingival margin of the crown (Fig 1). Bite-wing radiographs taken 3 weeks prior were negative for caries and pathology.

The dental and medical history of the patient was reviewed, and a parent noted that the patient's first permanent molars erupted at age 8 years with some

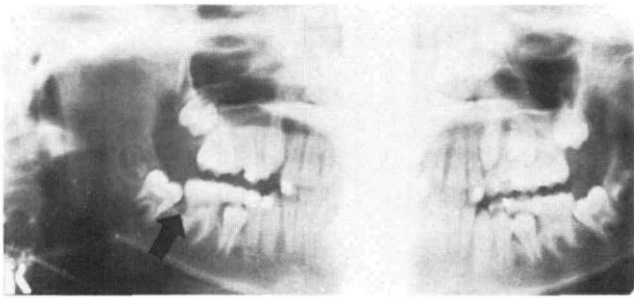


FIG 1. Radiograph of lesion, case 1.

difficulty. At that age there were 4 restored primary molars, but the adjacent second primary molar and all 4 first permanent molars were caries free. The patient had a history of frequent strep throats and high fever episodes since age 10 months, but had not had tonsil and adenoid surgery.

The patient was referred to an oral surgeon for an excision biopsy. The diagnosis of actinomycosis was confirmed by the pathologist who found distinct sulphur granules (Fig 2). A culture was positive for *A. israelii*. The patient received oral penicillin V, 500 mg/qid 6 hr after surgery for 4 weeks. Healing progressed and orthodontic banding was completed 3 months after diagnosis. At this appointment, the parent stated that the patient's grandfather had been treated for actinomycosis several years ago. There has been no oral recurrence during the 3-year follow-up of this patient, however, routine panoramic radiographs show

the mandibular right second permanent molar erupting ectopically. Thirty-four months after the excision the patient required an appendectomy, but the surgeon failed to have the organ cultured for actinomycosis.

Case Report: Patient 2

A 9-year-old female of Chinese ancestry was seen for initial dental examination; intraoral, bite-wing, and panoramic radiographs were taken. No caries or restorations were present, and resorption of the mandibular first primary molars was noted. Mandibular second premolars were congenitally missing with a Class II, Division 1 malocclusion and a history of airway problems and mouthbreathing. A painless, 9 mm mass containing granules was present at the distobuccal gingival area of the mandibular right first permanent molar. A careful history review with the parent revealed that the patient's primary incisors erupted at 4 months and her first permanent molars at 5 years. There was no history of trauma, and her tonsils and adenoids were present. The patient was referred to the second author for an excision biopsy. The pathology report was as follows: Actinomycosis — the specimen consists of squamous epithelium with pseudoepitheliomatous hyperplasia and severe acute and chronic inflammation associated with "sulphur granules." The gram stain revealed that the granules are composed of interlacing branching gram-positive filamentous organisms consistent with actinomycosis

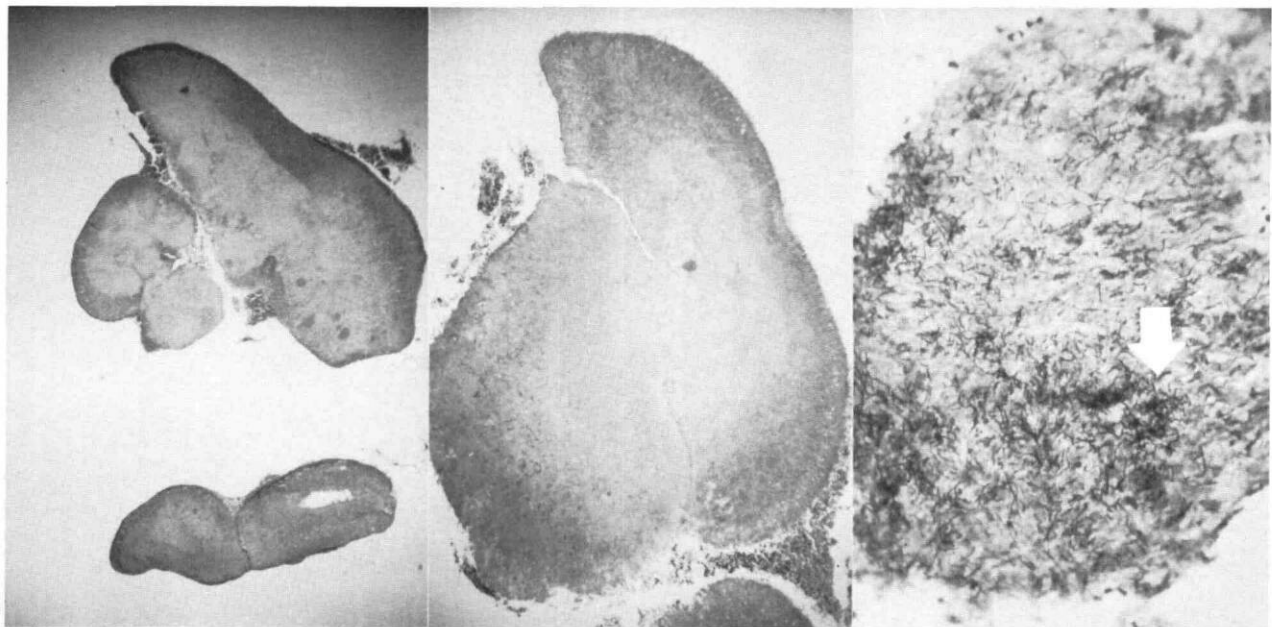


FIG 2. Histology of lesion of case 1 demonstrating "sulphur granules" in the upper left and right. FIG 3. (center) Histology of case 2 showing "sulphur granules" at lower right; (right) Histology of case 2 showing interlacing filamentous branches of *A. israelii*.

(Fig 3). This patient was treated at the time of surgery with 4 M units of procaine penicillin a day intravenously for 7 days; then oral penicillin V 500 mg/qid for 5 weeks. Healing was uneventful and no lesion recurrence has been noted to date.

Discussion

The consensus of opinion is that the origin of the actinomycosis is most often tonsillar⁶ and that the eruptive patterns and positions of the permanent molars provide sites for organisms to develop a lesion.

Children with oral actinomycosis lesions may be seen by the dentist first, an oral surgeon second, and a pediatrician third. It is important for the dentist who treats children to be alert and recognize the lesion caused by *A. israelii*. As soon as a biopsy confirms the diagnosis, the dental surgeon should inform the patient's physician in writing so that it is included in the patient's medical as well as dental record. It is important to monitor any subsequent lesions in the oral cavity, head and neck area, as well as elsewhere in the body, after the primary lesion has been removed and the patient treated with antibiotics. Vigilance probably should extend for the lifetime of the patient. Tonsillectomy would be mandatory if there was an oral recurrence after adequate antibiotic therapy.^a

Holm has demonstrated the presence of associated organisms in 954 of 960 specimens isolated from actinomycosis in humans.⁷ *Haemophilus actinomycetemcomitans* can be associated in lesions of actinomycosis which may be an indicator for the later development

of periodontal disease. Both organisms are anaerobic and may be synergistic with the *Haemophilus* responsible for reducing the oxygen tension of the involved tissues and thereby lowering host resistance.

It is interesting that the only 2 cases seen in children by the authors in more than 25 years of suburban dental practice are in females younger than 11 years, involving the same side of the mouth and same tooth position. The first case was diagnosed in 1981 and the second in 1984.

The authors thank pathologists Drs. Raymond A. Justi and Thomas M. Mark, Doctors Hospital, Coral Gables, Florida, for microscopic slides for illustrations and the patients' other physicians, Drs. George Lister and Julio Martinez for their cooperation.

Dr. Glenn is in the private practice of pediatric dentistry and orthodontics, 7741 SW 62nd Ave, South Miami, FL 33143. Dr. Doughty is in the private practice of oral surgery, Coral Gables, FL. Both are visiting lecturers at The University of Miami School of Medicine. Reprint requests should be sent to Dr. Glenn.

1. Bronner M, Bronner M: Actinomycosis. Baltimore; Williams & Wilkins Co, 1969 pp 40-41, 262-68.
2. Goldstein BH, Sciubba JJ, Laskin DM: Actinomycosis of the maxilla: review of literature and report of case. J Oral Surg 30:362-66, 1972.
3. Binford CH, Connor DH: Pathology of Tropical and Extraordinary Diseases. Washington, DC; Armed Forces Institute of Pathology, 1976 pp 552-54.
4. Kirsch W, Stears JC: Actinomycotic osteomyelitis of the skull and epidural space. J Neurosurg 33:347-51, 1970.
5. Tokiwa N, Yoshiya T: Clinical observations of actinomycosis in the neck and facial regions. Bull Tokyo Med Dent Univ 6:135, 1959.
6. Burket LW: Burket's Oral Medicine, 8th ed. Philadelphia; JB Lippincott Co, 1984 pp 371-72.
7. Holm P: Studies on the aetiology of human actinomycosis; "Do the other microbes of actinomycosis possess virulence?" Acta Path Microbiol Scand 28:392-406, 1951.

^a The antibiotic dosage in patient 2 is the more usually recommended regimen of therapy.

Quotable Quote: why families change pediatricians

Dissatisfaction with their child's physician sometimes causes parents to transfer to a new health provider. We studied the reasons for such transfers from 4 pediatric practices in Chittenden County, Vermont. Personal qualities of the physician, including the parents' perception of the physician's communication skills, his clinical competence, and the apparent level of concern were the most important factors that distinguished satisfied from dissatisfied parents. Structural features, including costs, waiting time, and continuity with the same physician, were less often sources of enough dissatisfaction to produce a transfer. Effectiveness and success in pediatric practice are dependent on competence, communication, and caring.

Young PC et al: Why families change pediatricians. Am J Dis Child 139:683-86, 1985.