

The teaching of Class I and II restorations in primary molars: a survey of North American dental schools

Marcio Guelmann, DDS Ivar A. Mjör, BDS, MSD, MS, Dr. Odont Greg R. Jerrell, DDS

Dr. Guelmann is assistant professor, Department of Pediatric Dentistry, University of Florida, Gainesville, Florida; Dr. Mjör is professor and Academy 100 Eminent Scholar, Department of Operative Dentistry, University of Florida, Gainesville, Florida; Dr. Jerrel is associate professor, Department of Pediatric Dentistry, University of Florida, Gainesville, Florida. Correspond with Dr. Guelmann at mguelmann@dental.ufl.edu

Abstract

Purpose: The purpose of this study was to obtain an overview of materials and restorative techniques taught for Class I and Class II restorations in primary molars in different pediatric dentistry departments in North America.

Methods: A form with response alternatives was mailed to 63 dental schools in the United States and Canada. The forms were addressed to the chairman/undergraduate program director of the department of pediatric dentistry. Questions regarding the restorative materials taught, indications and contraindications for the use of tooth-colored materials and the type of cavity preparation indicated for those materials were among the topics assessed.

Results: Eighty-six percent of the dental schools responded to the survey. Amalgam continues to be the material of choice for Class I and II restorations in primary molars, although hybrid composites and compomers are gaining some popularity. When tooth-colored materials were indicated, the slot-type of cavity preparation was the preferred one.

Conclusions: The diversity in teaching may reflect uncertainty related to requirements for optimal restorations of primary teeth. Data from dental schools of other countries may be important to obtain to establish universally accepted criteria and standards for restorative techniques of primary teeth. (*PediatrDent* 23: 410-414, 2001)

Amalgam was taught for decades as the material of choice for Class I and II restorations in primary molars. The Project TAPP, Task Analysis of Procedures in Pedodontics,¹ established standards for cavity preparations that are currently accepted.

Patients' demand for better esthetics and parents' scare of the potential adverse effect of mercury on health and the pollution of the environment motivated manufacturers of dental products to develop alternatives for amalgam. For the last 20 years, numerous clinical and laboratory studies using tooth-colored esthetic materials for Class I and II restorations in primary teeth were reported.²⁻²¹ Composite resins, glass ionomers, resin-modified glass ionomers, and, lately, compomers were used. Conservative and traditional, amalgam-like cavity preparations for Class I and II restorations were tested as well as new condensation and polymerization techniques.⁴⁻¹²

Currently available pediatric dentistry textbooks do not include instructions or illustrations on how to prepare primary

molars for esthetic filling materials, but general considerations were recently introduced and discussed.²² Garcia-Godoy²³ reviewed the subject and specified techniques and materials to be used. Due to the relatively short life of primary teeth, different restorative materials from those used in permanent teeth were indicated, making the selective criteria decision complicated for the clinician.

Studies of teaching programs for Class I and Class II composite restorations in permanent teeth have been conducted in North America,²⁴ Europe,²⁵ Japan²⁶ and Brazil.²⁷ Marked diversities in the teaching were noted, like the amount of curriculum time dedicated to teach resin-based composites, the type of tooth indicated for these restorations (premolars and/or molars), and the occlusal width of the preparations. These diversities were not only within countries, but also between continents. The status for primary teeth was not yet investigated.

The purpose of this study was to obtain an overview of materials and restorative techniques taught for Class I and Class II restorations in primary molars in different pediatric dentistry departments in the United States and Canada.

Methods

The invitations to participate in the study were mailed in January 2001 to all 63 dental schools in the United States and Canada. It contained a cover letter explaining the study, an anonymous two-page form with alternative responses and a pre-stamped envelope for the reply. The forms were addressed to the chairman/undergraduate program director of the department of pediatric dentistry. At the end of February 2001, a reminder was sent.

The study was based on that by Mjör and Wilson²⁴ and consisted of 10 questions, some in a yes/no format and others in a multiple-choice format. The questions assessed the use of amalgam and tooth-colored restorative materials for Class I and Class II restorations for primary molars, mainly focusing on the use of tooth-colored materials and the type of cavity preparations indicated for these materials, the types of materials used, indications and contraindications for their use, the teaching of pediatric dental materials, and the department policy for the use of bases and liners in cavity preparations of different depths. Information regarding preclinical and clinical requirements,

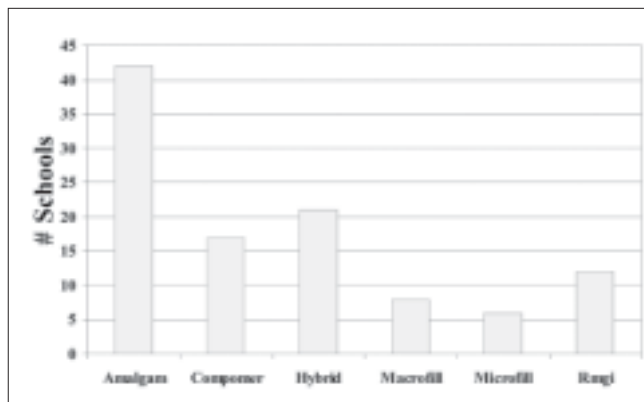


Fig 1. Schools' preferences for restorative materials in primary molars. Most of the schools recommended more than one material (RmgI=Resin modified glass ionomer)

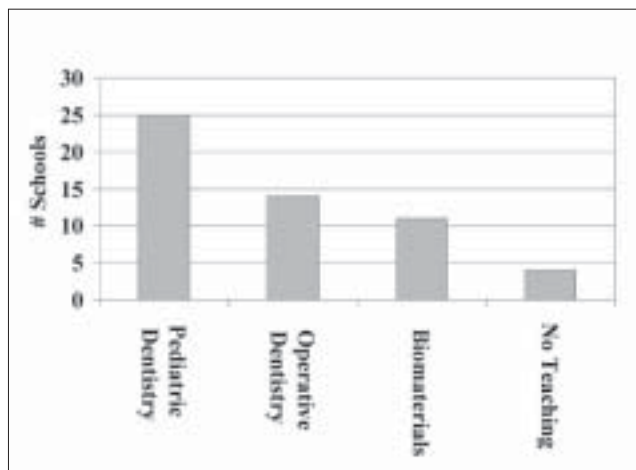


Fig 2. Responsibility for teaching pediatric dental materials

Table 1. Contraindications for Using Tooth-Colored Materials

Chosen by >50% of schools	Chosen by <25% of schools
Poor oral hygiene	Patient's age
After pulpotomy and pulpectomy	Allergy
Inability to use rubber dam	
Restorations with more than two surfaces	
Gingival margin subgingival	
Larger restorations	

brand name of materials and cost of tooth-colored restorations in comparison to amalgam was not requested in the survey.

Results

Fifty-four (86%) of 63 dental schools in the United States and Canada responded to the survey. Most schools answered all of the questions for the different topics, and the response rates for each category were calculated based on the number of schools responding. Some schools selected several alternative answers for some of the questions.

Material selection

The results for material selection for Class I and II restorations in primary teeth are illustrated in Figure 1. Eleven schools (20%) selected amalgam as the only restorative material recommended. Most of the schools recommended more than one material to be used. Among the tooth-colored materials, hybrid composites and compomers were the most popular. Only one school reported to be "amalgam-free" and one Canadian school reported that dental restorations for patients nine years of age and younger were covered by the government only if restored with amalgam.

Thirty-four schools (63%) selected amalgam as the preferred material for restorations of Class I and II lesions. Five schools (9%) preferred composite materials for Class I and amalgam only for Class II. One department mentioned that there was no agreement among the faculty and the decision was up to the instructor in the clinic.

Teaching dental materials

Teaching of pediatric dental materials was reported to be included in the undergraduate pediatric course in 46% of the departments. Seven percent of the schools reported that this subject was not taught in their course. The departments of Operative Dentistry and Dental Biomaterials were responsible for teaching pediatric dental materials in about 20% of the schools (Figure 2).

Teaching tooth-colored materials

The departments were asked if they taught composite resins, compomers and glass ionomers as alternative materials to amalgam in Class II restorations in primary molars. Forty-seven schools (87%) responded positively, but 50% only under certain conditions. The contraindications for the use of tooth-colored filling materials in Class I and II restorations in primary molars were also reported. They were selected from a list of 11 potential contraindications. The reason for asking about contraindications was to find out if any of the same contraindications reported for permanent teeth (eg, heavy occlusion, bruxism, allergy, etc.) was also considered for restorations in primary teeth. The results are summarized in Table 1.

Type of cavity preparation

Ninety-six percent of the schools teach classical Class I and Class II cavity preparations for amalgam in primary teeth. Information about the type of cavity preparation recommended for tooth-colored materials was also requested. Fifty-seven percent of dental schools indicated the conservative box-only (slot) type of preparation and 19% of these also indicated the addition of retention grooves to the preparation. Thirty-six percent selected the classical amalgam-like type of cavity preparation (Figure 3).

The use of cement bases/liners for primary molars

When restoring Class II lesions with amalgam, 15% of the dental schools recommended the use of total etch and bonding agents as a standard procedure. When a base was deemed necessary under amalgam, glass ionomer was the preferred material for 32% of the schools and calcium hydroxide for 14%. Thirty-six percent selected both materials as options. Twelve percent also included total etch and bonding agents (Figure 4).

Figure 5 illustrates the schools' recommendations for bases/liners regardless the restorative material used. When shallow cavity preparations are prepared, 78% of the schools did not recommend any base or liner. Fourteen percent recommended total etch and bonding agents in combination with the final restorations.

For moderately deep cavity preparations, 49% did not recommend any base or liner. Fourteen percent recommended calcium hydroxide only and 12% glass ionomer only. Twelve percent recommended either calcium hydroxide or glass ionomers. Total etch and bonding agents were recommended by 8% of the schools for moderately deep cavities. For deep cavity preparations, glass ionomer only was indicated by 32% of the schools while 13% indicated calcium hydroxide only. Thirty-two percent recommended both calcium hydroxide and glass ionomer.

Discussion

The results of the present study showed that amalgam continued to be taught as the preferred restorative material for Class I and Class II restorations in primary molars in most of the dental schools in North America. Although it was the most popular material, amalgam was not the only material that was taught. Most of the schools selected more than one material to be used, but the indications for using those materials were not specified nor requested in the survey.

The preferred tooth-colored materials in Class I and II restorations for primary molars were hybrid composites and compomers. These results confirm the findings of

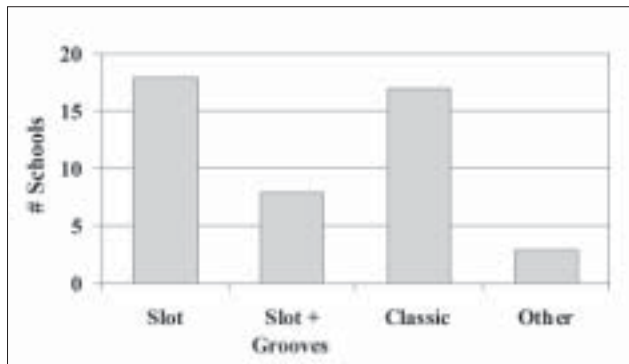


Fig 3. Type of cavity preparations selected for tooth-colored restorations

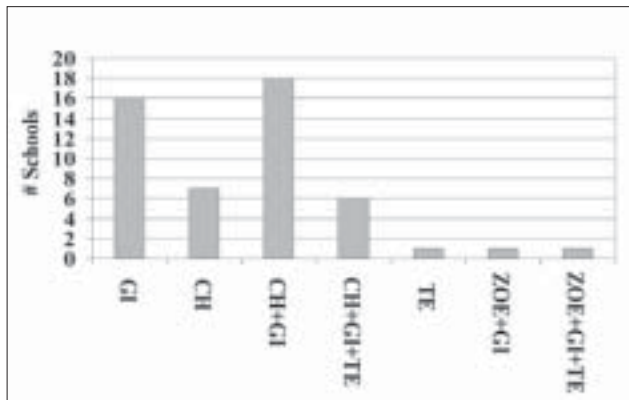


Fig 4. Indications for the use of bases and liners under amalgam restorations (GI= glass ionomer; CH= calcium hydroxide; TE= total etch; ZOE= zinc oxide eugenol)

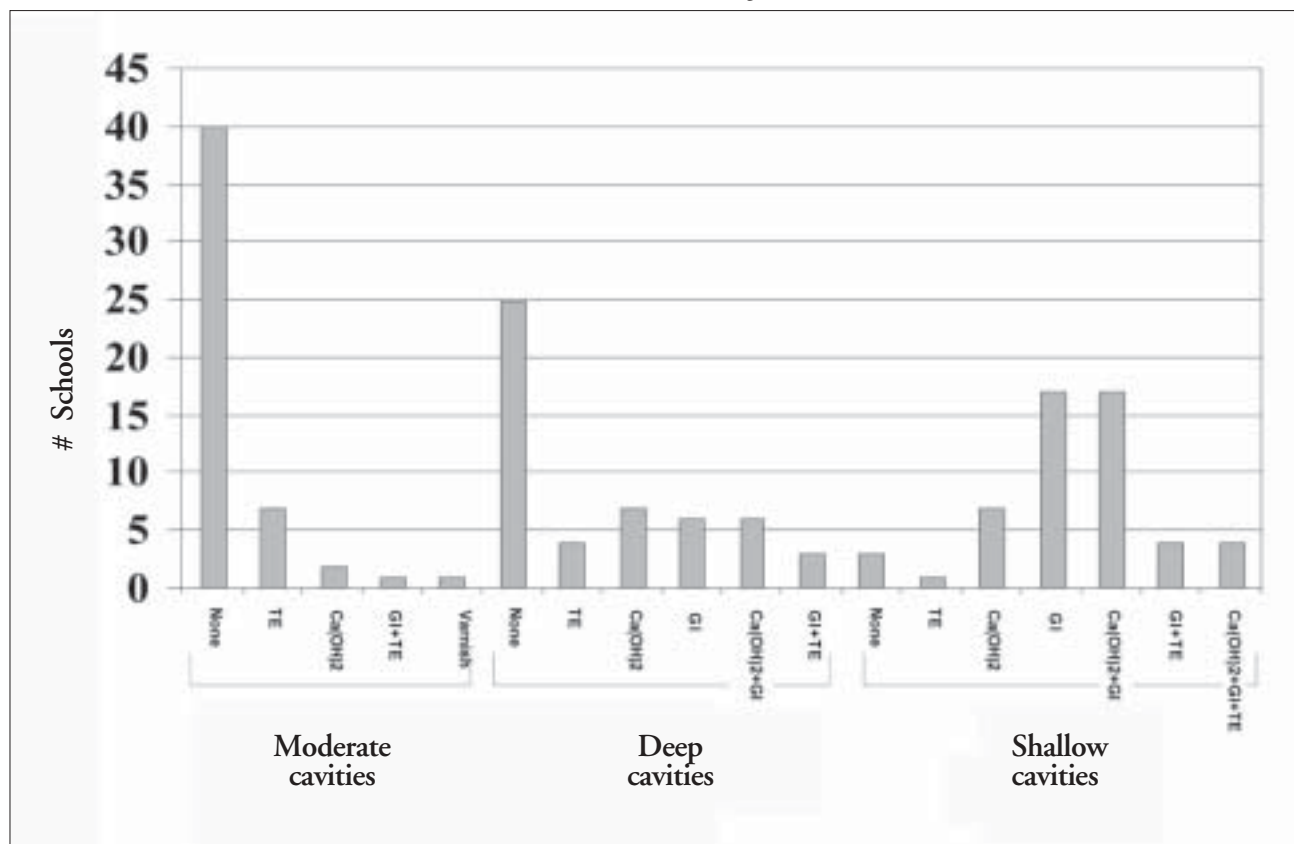


Fig 5. Indications for the use of bases and liners in different depth cavity preparations in primary molars (TE=total etch; GI+glass ionomer)

Christensen,²⁷ who reported the increased popularity of compomers and hybrid composites in pediatric dentistry.

Short-term clinical studies (up to two years) with composites in primary molars showed high success rates.^{3,4} Shorter longevity for composites has also been reported.²⁰ However, high long-term failure rates were reported,⁵ mainly due to secondary caries, loss of retention and discoloration.

Compomers were introduced on the European market in 1993 as an alternative material to amalgam in primary teeth.²⁹ Several clinical studies were conducted worldwide assessing the quality and longevity of compomer restorations in the last five years.⁷⁻¹² Although the short-term follow up reported for these studies is only up to three years, the results so far are comparable to amalgam (90% success after two years). Excellent handling properties, good esthetics, fluoride release, and simple application technique were the main reasons for compomers' popularity. The restorations in those studies were made according to two cavity designs: (1) a box-only (slot) preparation and (2) the conventional amalgam-like type of preparation. After two years, the failure rate for both types of cavity preparations was similar (10%). The addition of retention grooves was reported to improve the retention rate of the restorations.¹¹ Compomers are also technically sensitive materials. The use of rubber dam influenced the quality of the fillings. In a multicenter study⁷ where multiple operators performed the fillings, "relative" isolation was used. A failure rate of 22% was reported after two years.

The use of bases and liners in primary teeth were comparable to those in permanent teeth.²⁴ For shallow and moderately deep cavity preparations in both studies, the majority of the schools did not recommend any base or liner before inserting the restorative material. For moderately deep cavity preparations, glass ionomers were the material of choice for permanent teeth if a base was used, while calcium hydroxide and glass ionomers were equally selected for primary teeth. For deep preparations, glass ionomers followed by calcium hydroxide were indicated for both primary and permanent teeth.

No data are available regarding teaching of Class I and II restorations in primary teeth in other geographic areas. Due to restrictions in the use of amalgam in some European countries, and probably also in Japan, the teaching of tooth-colored materials as amalgam replacement in those countries is more emphasized than in North America. Information on the teaching programs from these countries may be important to enhance the quality of restorations in primary teeth.

Conclusions

Marked diversity in the teaching programs was noted in North American dental schools. Amalgam continued to be the preferred material for Class I and II restorations in primary teeth.

Data from dental schools of other countries and continents would be important to compare the findings and assist in the determination of optimal restorations in primary teeth.

References

1. Houpt M. Project TAPP, Task Analysis of Procedures in Pedodontics. United States Public Health Service Final report, (Litho), 1975.
2. Guelmann M, Fuks AB, Holan G, Grajower R. Marginal leakage of Class II glass-ionomer-silver restorations, with and without posterior composite coverage: an in-vitro study. *J Dent Child* 56:277-282, 1989.
3. Eidelman E, Fuks A, Chosack A. A clinical, radiographic, and SEM evaluation of Class II Composite restorations in primary teeth. *Oper Dent* 14:58-63, 1989.
4. Oldenburg TR, Vann WFJr, Dilley DC. Composite restorations for primary molars: two-years results. *Pediatr Dent* 7:96-103, 1985.
5. Varpio M. Proximocclusal composite restorations in primary molars: a six-year follow-up. *J Dent Child* 52:435-440, 1985.
6. Holan G, Chosack A, Casamassimo PS, Eidelman E. Marginal leakage of impregnated Class II composites in primary molars: an in vivo study. *Oper Dent* 17:122-128, 1992.
7. Andersson-Wenckert IE, Folkesson UH, van Dijken JW. Durability of a polyacid-modified composite resin (compomer) in primary molars: a multicenter study. *Acta Odontol Scand* 55:255-260, 1997.
8. Hse KMY, Wei SHI. Clinical evaluation of compomer in primary teeth: 1-year results. *JADA* 128:1088-1096, 1997.
9. Roeters JJM, Frankenmolen F, Burgerdijk RCW, Peters TCRB. Clinical evaluation of Dyract in primary molars: 3-year results. *Am J Dent* 11:143-148, 1998.
10. Marks LAM, van Amerongen WE, Kreulen CM, Weerheijm KL, Martens LC. Conservative interproximal box-only polyacid modified composite restorations in primary molars, 12-month clinical results. *J Dent Child* 66:23-29, 1999.
11. Mass E, Gordon M, Fuks AB. Assessment of compomer proximal restorations in primary molars: a retrospective study in children. *J Dent Child* 66:93-97, 1999.
12. Papagiannoulis L, Kakaboura A, Pantoleon F, Kavvadia K. Clinical evaluation of a polyacid-modified resin composite (compomer) in Class II restorations of primary teeth: a two-year follow-up study. *Pediatr Dent* 21:231-234, 1999.
13. Fuks AB, Araujo FB, Osorio LB, Hadani PE, Pinto AS. Clinical and radiographic assessment of Class II esthetic restorations in primary molars. *Pediatr Dent* 22:479-485, 2000.
14. Croll TP, Helpin MK. Class II Vitremer restorations of primary molars. *J Dent Child* 62:17-21, 1995.
15. Qvist V, Laurberg L, Poulsen A, Teglers PT. Longevity and cariostatic effects of everyday conventional glass-ionomer and amalgam restorations in primary teeth: three-year results. *J Dent Res* 76:1387-1396, 1997.
16. Donly KJ, Grangennet C. Dentin demineralization inhibition at restoration margins of Vitremer, Dyract and Compoglass. *Am J Dent* 11:245-248, 1998.
17. Tonn EM, Gunnar R. Clinical evaluations of composite resin restorations in primary molars: a 4-year follow up study. *JADA* 117:603-606, 1998.
18. Christensen GJ. Restorations of pediatric posterior teeth. *JADA* 127:106-108, 1996.
19. Corbin SB, Kohn WG. The benefits and risks of dental amalgam: current findings reviewed. *JADA* 125:381-388, 1994.
20. Donly KJ, Segura A. Clinical Performance and caries inhibition of resin-modified glass ionomer cement and amalgam restorations. *JADA* 130:1459-1466, 1999.
21. Qvist V, Qvist J, Mjör IA. Placement and longevity of tooth-colored restorations in Denmark. *Acta Odontol Scand* 48:305-311, 1990.
22. Waggoner WF. Restorative dentistry for the primary dentition. In: Pediatric Dentistry — Infancy Through Adolescence. 3rd ed. Pinkham JR, Casamassimo PS, McTigue DJ, Fields HW, Nowak A. Philadelphia: W.B. Saunders Co; 1999:309-340.

23. Garcia-Godoy F. Resin-based composites and compomers in primary molars. *Dent Clin North Am* 44:541-570, 2000.
24. Mjör IA, Wilson NHF. Teaching Class I and Class II direct composite restorations: results of a survey of dental schools. *JADA* 129:1415-1421, 1998.
25. Wilson NHF, Mjör IA. The teaching of Class I and Class II direct composite restorations in European dental schools. *J Dent* 28:15-21, 2000.
26. Fukushima M, Iwaku M, Setcos JC, Wilson NHF, Mjör IA. Teaching of posterior composite restorations in Japanese dental schools [abstract 1633]. *J Dent Res* 77:836, 1998.
27. Gordan VV, Mjör IA, Veiga Filho LC, Ritter AV. Teaching of posterior resin-based composite restorations in Brazilian dental schools. *Quintessence* 31:735-740, 2000.
28. Christensen GJ. Restorative dentistry for pediatric teeth State of the art 2001. *JADA* 132:379-381, 2001.
29. Hickel R, Manhart J. Glass-ionomers and Compomers in pediatric dentistry. In: *Advances in Glass-Ionomer Cements*. Davidson CL, Mjör IA. Quintessence Publishing Co; 1999:201-226.

Letter to the Editor



Dental Prophylaxis: An Ethical Conundrum

Dental prophylaxis has been an integral part of the caries prevention armamentarium for decades. So much is it embedded in the public psyche, that most patients consider their recall dental appointments as going for “cleaning their teeth.” But this hallowed aura of the dental prophylaxis has lost its scientific luster of late.

Evidence-based recommendations forswear universal provision of the dental prophylaxis.¹ This brings to the fore two potential ethical issues.

1. Elimination of dental prophylaxis from recall dental examinations has significant economic implications for pediatric dental practices.² This raises the unpleasant devil’s advocate question of whether some practitioners would resist adopting the evidence-based recommendations on grounds of economic self-interest.

2. Dental prophylaxis in common parlance refers to the rubber cup pumice prophylaxis. This notion prevails among patients and third-party payers. However, the American Academy of Pediatric Dentistry has appropriately noted that the “dental prophylaxis can be performed using a brush or rotary cup.”³ Therefore, some practitioners may substitute the rubber cup pumice prophylaxis with the toothbrush prophylaxis. These practitioners may opt to use the same procedure code for toothbrush prophylaxis as for a rubber cup pumice prophylaxis and they would be technically correct in doing so. But the parent or third-party payer may presume that a rubber cup pumice prophylaxis was performed. The disturbing question

that might be asked of the practitioner on the discovery that a toothbrush rather than a rubber cup pumice prophylaxis was performed would be that, “Is not a toothbrush prophylaxis a part of Oral Hygiene Instructions” and therefore appropriately charged as such? This miscoding (sic) might be construed as misrepresenting treatment delivered.

These ethical dilemmas confronting practitioners merit an early resolution.

S.M. Hashim Nainar, BDS, MDSc
Hamilton, Ontario

References

1. Lewis DW, Ismail AI: The Canadian Task Force on the Periodic Health Examination: Periodic health examination, 1995 update: 2. Prevention of dental caries. *Can Med Assoc J* 152:836-846, 1995.
2. Nainar SMH: Economic implications of evidence-based caries prevention in pediatric dental practice: a model-based approach. *Pediatr Dent* 23:66-70, 2001.
3. American Academy of Pediatric Dentistry: The role of prophylaxis in pediatric dentistry. *Pediatr Dent* 22(7): 37, 2000.