



Congenital adrenal hyperplasia and enamel hypoplasia: case report

Kerrod B. Hallett, MDSc, FRACDS Roger K. Hall, MDSc, FRACDS, FICD

Abstract

A female with congenital adrenal hyperplasia and enamel defects involving the permanent maxillary incisors and all canines and premolars received composite veneer splint overlays under general anesthesia. Possible etiological factors involved in the formation of the enamel defects and overall case management is discussed. (Pediatr Dent 17:54-59, 1995)

Congenital adrenal hyperplasia (CAH) and adrenogenital syndrome (AS) are terms used to describe a group of rare autosomal recessive medical conditions involving inborn errors of steroidogenesis.^{1,2} Because of a lack of circulating cortisol, ACTH-mediated adrenal hypertrophy occurs, but the adrenal glands generally are incapable of secreting large quantities of steroids other than androgens. In the most common form of CAH, the underlying abnormality in the adrenal cortex is a deficiency of the enzyme 21-hydroxylase which results in a partial block of cortisol (glucocorticoid) and aldosterone (mineralocorticoid) biosynthesis. The diagnosis of CAH is readily confirmed by elevated 17-hydroxyprogesterone in the serum and an excess of pregnanetriol in the urine. The other adrenal enzyme defects, each with their own characteristic abnormalities, have been described previously,^{1,2} but comprise only 10% of remaining cases.

Females with the classic form of CAH are born with ambiguous external genitalia and require reconstructive surgical procedures for cosmetic reasons and to facilitate normal reproductive function. The excess secretion of fetal androgens results in clitoral enlargement and fusion of the labia causing genitalia that, in the most extreme form, may be similar to those of the male with undescended testes. Both sexes undergo precocious advance in somatic growth and progressive virilization in the female or incomplete masculinization in the male occurs. Gender confusion in affected females may develop from incorrect sex assignment and rearing. Pseudohermaphroditism may be prevented by prenatal administration of dexamethasone to the at-risk mother in the first trimester of pregnancy to suppress the abnormal secretion of

androgens by the fetal adrenal gland.³ In addition, three of four children are at risk for sudden death due to salt wasting and fluid loss, hypoglycemia, and systemic infection unless hormone replacement therapy is commenced early in infancy. Gluco- and mineralocorticoid replacement therapy has been shown to correct the salt imbalance and ensure essential adrenal function during growth and maturation.⁴

The long-term use of replacement corticosteroids can cause many side-effects,⁵ often beginning soon after therapy commences. In children, overall growth retardation, osteoporosis, impaired glucose tolerance, and increased susceptibility to infection are important considerations. Of interest to the pediatric dentist is the potential effect of corticosteroid therapy on calcium homeostasis in general and permanent tooth development, particularly enamel protein matrix synthesis and mineralization.

Dental management of children with CAH requires an individualized protocol for corticosteroid supplementation depending on their current replacement regimen. Patients who have taken daily corticosteroid replacement within the last year are at risk from hypotensive crisis if they are not given supplementary corticosteroids before and during periods of stress such as dental procedures.^{5,6}

The purpose of this case report is to present a previously unreported association of CAH and enamel hypoplasia and an oral rehabilitation technique utilizing sectional arch splints to restore the affected dentition.

Case report

Chief complaint and past history

AC, a 6-year 11-month-old female with salt-wasting CAH diagnosed at age 2 weeks, was referred by her endocrinologist to the Department of Dentistry, Royal Children's Hospital, for initial assessment and management of "terrible front teeth."

She was the only child of consanguineous parents of Lebanese background, born at term following a normal pregnancy and vaginal delivery. Sex was indeterminate until chromosome analysis confirmed 46 XX karyotype. She was commenced on oral cortisone acetate at medical diagnosis and additional oral

prednisolone at age 5 years 2 months. Her medical history included multiple febrile episodes during early infancy and childhood, recurrent otitis media, poor eating habits, vomiting, and diarrhea. Her developmental milestones were considered normal, but height and weight were at or below the third centile throughout childhood.

Clinical examination

AC was timid and shy with extremely short stature and a wasted appearance in general. Her weight was 14.9 kg (3.5 kg below the third centile for her age) and her height was 109.0 cm (4 cm below the third centile for her age). Vital signs were: pulse 127, blood pressure 108/86, and temperature 36.7°C. She cooperated poorly and her behavior further deteriorated during the initial consultation and later investigations.




Fig 1. Frontal view of patient's face at presentation showing periorbital and perioral pigmentation, thick eyebrows, low hairline.

Facial proportions were balanced and she had a thin face with a straight profile and a general brachycephalic pattern (Fig 1). Periorbital and perioral pigmentation was apparent with low hairline, thick eyebrows, and upper lip facial hair. Mandibular opening was within normal limits with no deviation on opening or closure. She had a mixed dentition that was advanced for her chronological age. Soft tissues were within normal limits with no gingival pigmentation apparent. The gingivae were marginally inflamed due to poor oral hygiene and eruption of permanent incisors.

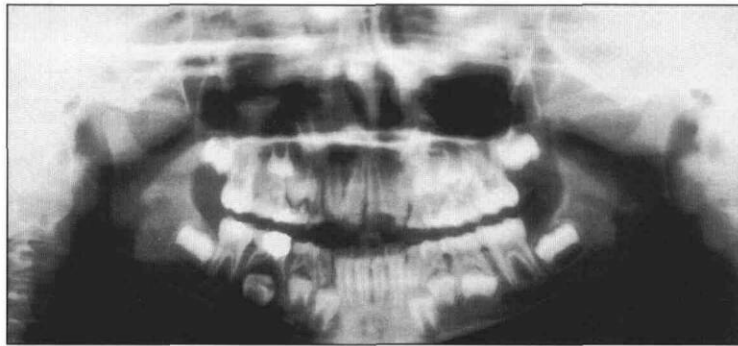


Fig 3. Panoramic radiograph showing dental development at age 7 years 8 months, nonvital right mandibular second primary molar.

All erupting permanent maxillary incisor teeth were noted to have a generalized thin, rough, hypoplastic enamel surface involving the entire crown (Fig 2). Both the permanent mandibular incisors and first molars were unaffected, but the mandibular incisal enamel appeared thin with accentuation of the mammelons. The remaining primary teeth also had a normal appearance and morphology except for the canines, which may have been hypoplastic previously as they were now heavily worn. Amalgam dental restorations were present on the interproximal surfaces of maxillary primary molars and on the occlusal surface of the mandibular right second primary molar. All remaining teeth appeared to be clinically sound. We assessed the occlusion as bilateral flush molar terminal plane with a normal anterior overjet and overbite relationship. Both arches were mildly crowded with ectopic eruption of the incisors. A panoramic radiographic examination (Fig 3) revealed a chronologically advanced, complete succedaneous dentition and periapical pathology associated with pulpal necrosis

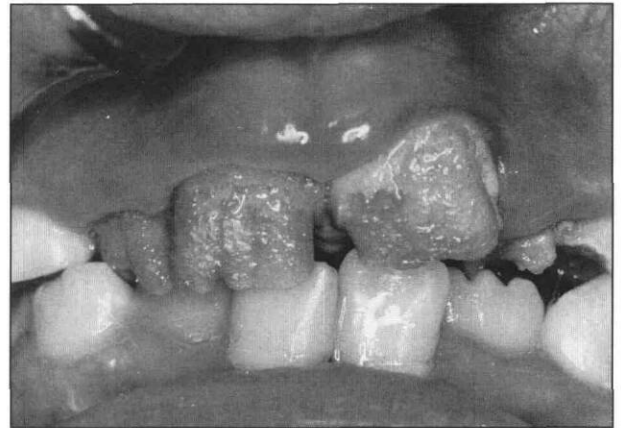


Fig 2. Frontal view of anterior teeth showing hypoplastic maxillary incisors and thin mandibular incisors with accentuated mammelons.

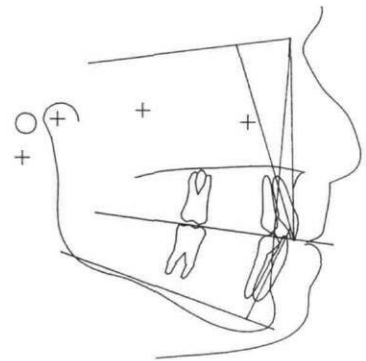


Fig 4. Steiner cephalometric analysis at age 7 years 8 months showing Class II skeletal pattern. Cephalometric angles are SNA 89°, SNB 79°, ANB 10°, MP 25°, OP 14°, Maxillary incisor SN 100°, Mandibular incisor MP 96°, Interincisal angle 137°.

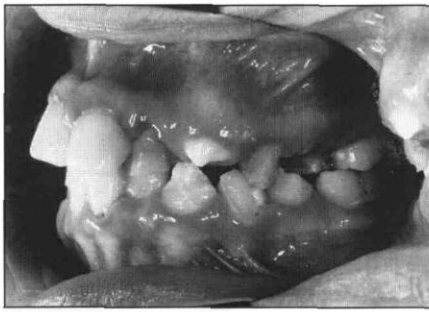


Fig 5A (left). Right lateral view showing erupting hypoplastic permanent canines and premolar teeth at age 9 years 10 months. The maxillary incisors had been temporized previously with composite resin veneers.

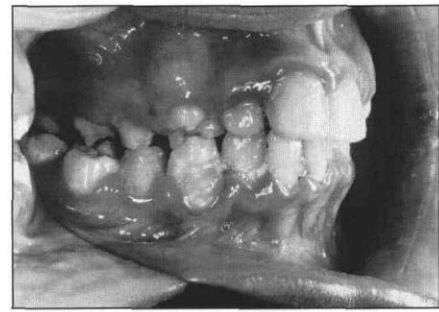


Fig 5B (right). Left lateral view showing erupting hypoplastic permanent canines and first premolar teeth, and over-retained primary teeth fragments.

of the mandibular right second primary molar. Cephalometric analysis (Fig 4) was undertaken to assess future skeletal growth patterns and showed a skeletal Class II jaw relationship, associated maxillary protrusion, and low occlusal and mandibular plane angles.

A provisional diagnosis of chronological enamel hypoplasia associated with an earlier systemic insult was made and a treatment plan was established involving dental prophylaxis, fissure sealant therapy, and interim restoration of enamel defects with composite resin veneers. The dental and skeletal malocclusion is to be reviewed every 6 months and orthodontic treatment considered with eruption of all permanent teeth and if cooperation is sufficient to allow successful treatment.

After numerous attempts to desensitize the patient and introduce simple preventive procedures, the extraction and the fissure sealants were completed. The patient was clearly upset with intraoral manipulation and isolation was extremely difficult. The treatment plan was modified to include full-crown restoration with composite resin under general anesthesia after eruption of the permanent premolars and canines. The central incisors were restored with composite resin veneers while waiting for eruption of the buccal segments. During this period, the patient was reviewed quarterly until tooth eruption was complete. All premolars and canines were noted to be similarly affected with a thin, rough hypoplastic enamel surface (Figs 5a and 5b). However, it was our clinical impression that the second premolars were less affected than the first premolars and that the second molars had a normal radiographic appearance.

Dental restoration was scheduled to be undertaken using sectional arch splints to allow ease of manipulation of the resin material and opening of the interocclusal dimension to a working height established from transfer records on a semiadjustable articulator. After a trial wax-up on the working models to create the correct occlusal plane and tooth shape, transfer alginate impressions were made and duplicate stone models poured to facilitate the splint construction. Sectional splints, shown in Fig 6, were made from a 1-mm-thick thermoforming, clear, polystyrene foil (Erkolen, Erckopp GmbH, Pfalzgrafenweiler, Germany) using the suck-down method used for mouthguard fabrication. Full maxillary and mandibular

lar arch splints were sectioned into working units of three teeth — premolar and first molar units and incisor and canine units — to facilitate reconstruction of the tooth crowns using a hybrid composite resin (Herculite XR®, Kerr Manufacturing Co, Romulus, MI) and dentin bonding agent (All Bond 2™, Universal Bonding System, Bisco, Itasca, IL). The completed restorations are shown Figs 7a and 7b.

Preventive measures including regular oral hygiene instruction, professional prophylaxis, and topical fluoride application with daily 0.05% neutral sodium fluoride mouthwash (Dentamint Neutral, Colgate Oral Care, Sydney, AUS) have been advocated during the pre- and post-treatment periods. Unfortunately, her oral hygiene has not improved and the marginal gingivitis has never fully resolved.

Discussion

The most interesting aspect of this case is to speculate on the diagnosis and the pathological processes responsible for the enamel defect development.

During the secretory phase of amelogenesis, the soft, immature, forming enamel with a high-protein (80–

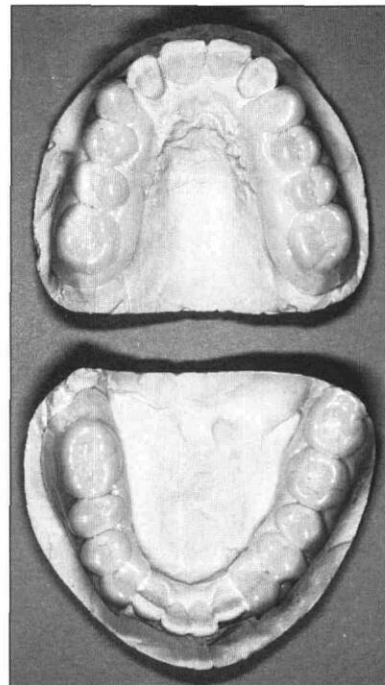
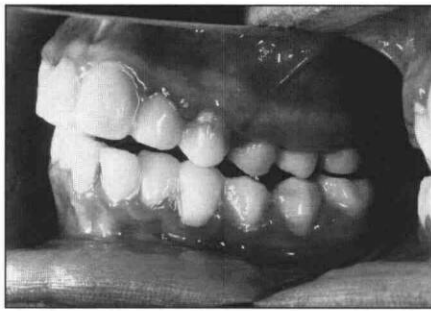
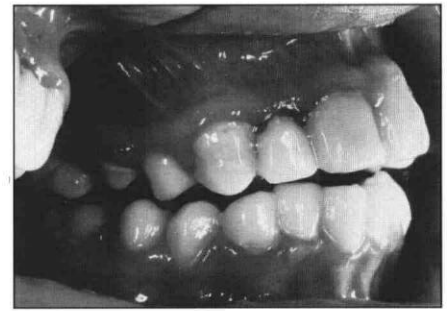


Fig 6. Two maxillary and mandibular sectional arch splints on duplicated models prior to crown reconstruction. The splints were sectioned into working units of incisors/canines, and premolars/first molars with mesial and distal extension to facilitate the crown buildup procedure.



Figs 7A (left), and 7B (right).
Left and right lateral views
of completed composite
resin splint restoration
of incisor/canine and
premolar/molar teeth.



90% amelogenin, 10–20% enamelin), high water, and low mineral content attains its full thickness, and then the protein framework is broken down by intrinsic protease activity as secondary mineralization with hydroxyapatite crystallites occurs. Initially, during protein removal, considerable porosity occurs as matrix is replaced by tissue fluid. Protein removal and mineralization may occur concurrently with matrix secretion and deposition as a continuum.⁷

A genetic factor responsible for the enamel defect was difficult to investigate with no siblings and all immediate family members in Lebanon. The unusual distribution of the permanent enamel defects and the unaffected primary dentition make this etiological model unlikely, although the consanguinity of the parents must increase the potential for an autosomal recessive form of hypoplastic or hypocalcified amelogenesis imperfecta.

The possibility of factors operating within CAH itself as the cause of the enamel defects in a manner similar to other inborn errors of metabolism such as galactosemia, phenylketonuria, alkaptonuria, erythropoietic porphyria, and hyperoxaluria was considered. Pindborg⁸ does not list CAH as a possible metabolic condition in the development of enamel hypoplasia in his review article of 140 causative factors, and to our knowledge no other case reports have highlighted this association. The unequal distribution of the defects does not support a hypothetical metabolic influence, which would influence all permanent tooth formation equally. CAH is inherited as a monogenetic autosomal recessive trait closely linked to the HLA major histocompatibility complex on the short arm of chromosome 6.² Amelogenins comprise 80–90% of the immature enamel protein matrix. Lau et al.⁹ have reported the mapping of the human amelogenin gene to the distal short arm of the X chromosome and the pericentromeric region of the Y chromosome, while Salido et al.¹⁰ have confirmed these genes to be transcriptionally active in developing human fetus toothbuds in the formation of enamel protein and crystallites during the secretory stage of tooth development. It is unlikely that CAH and amelogenin synthesis are genetically related.

Another differential diagnosis considered was chronological enamel hypoplasia due to a systemic insult affecting the permanent maxillary incisor and all ca-

nine and premolar teeth during their critical period of amelogenesis.¹¹ Urinary infection, childhood viral illnesses, and poor nutritional intake have been postulated as possible etiological factors in the development of chronological enamel hypoplasia.⁸ This possibility is supported by: 1) the distribution of the defects in this case involving only those teeth in which enamel matrix synthesis would normally have commenced from 5–6 months in utero to 8 months after birth;⁷ 2) a proven *Escherichia coli* urinary infection in the neonatal period; and 3) a postnatal history of recurrent febrile illness of probable viral etiology and poor nutrition intake.

Advanced tooth development and eruption in conjunction with advanced somatic bone maturation and measured cephalometric facial growth parameters as seen in this case have been studied in children with CAH.¹² It is conceivable that the enamel matrix synthesis for the unaffected permanent mandibular incisors and first molars — teeth that are known to commence enamel protein synthesis at 3 1/2 to 5 months in utero⁷ — was complete before birth and that these teeth were unaffected by postnatal events. The pathogenesis is still unclear, but it is presumed that an exanthematous fever or enteropathy may result in direct damage to the ameloblasts, the supporting cells of the dental follicle, and their vascular supply, producing enamel defects. In addition, increased susceptibility to systemic infection due to immunosuppression from long-term steroid replacement therapy⁵ would potentiate the likelihood of a medical insult producing chronological enamel hypoplasia.

An additional factor in the etiology of the enamel hypoplasia could be the direct effect of long-term corticosteroids administration on tooth development. Microradiographic examination of the incisors of cortisone-treated rats has shown deposition of intrapulpal cementum-like globules and frequent incremental lines within the dentin.¹³ These defects suggest that the mineral content of dentin may be lower than normal, possibly due to odontoblast disorganization or poor cell differentiation during dentinogenesis. In a similar study investigating cortisone-induced enamel hypoplasia,¹⁴ accentuated surface perikymata and closely apposed incremental lines were seen in enamel prismatic structure. Other features included irregularly calcified, cementum-like globules within the dental follicle consisting of fine needle-like crystals smaller than those of

normal enamel. This earlier work by Anneroth and Bloom¹³ and Hall,¹⁴ though limited, suggests a direct influence of cortisone on odontogenesis and mineralization. The side effects of osteoporosis and hypocalcemia from long-term, high-dose corticosteroid therapy described by several clinicians^{5,15} and suggested by others,¹⁶ and its subsequent effect on enamel development require further laboratory investigation before a direct cause and effect relationship can be stated.

Current principles in the management of generalized enamel defects such as amelogenesis imperfecta, stress the need for early interception and conservative restoration of the affected teeth to prevent attrition.¹⁷⁻²¹ The pediatric dentist must time intervention to the patient's current dental needs and maximize the future prosthodontic options for definitive restoration. Here, this decision was further confounded by our patient's medical, psychological, and behavior-management problems.

Interim restoration of affected permanent teeth with composite resin veneers for anterior teeth and stainless steel crowns for posterior teeth has been suggested by several authors.^{17, 18} Early intervention is advised to prevent caries development, gingivitis, and occlusal attrition.¹⁸ Of more importance to the patient is the improved dental appearance and the reduced sensitivity, which allows normal eating, drinking, and cleaning. Strict dietary control of between-meal sugary snacks and drinks, topical fluoride therapy with supplemental fluoride tablets and fluoride toothpaste, and meticulous oral hygiene has also been advocated to prevent further loss of already-compromised tooth structure.¹⁸ In our case, the patient was anorexic and her diet mainly consisted of high-caloric supplementation with carbohydrate-containing foods and drinks to encourage weight increase. She was poorly compliant with oral hygiene measures but did use a fluoride toothpaste and lived in an optimally fluoridated area. Unfortunately, dental caries developed in the proximal surfaces of the first molar and premolar teeth during the waiting period and the generalized marginal gingivitis did not resolve.

However, it was still considered appropriate to intervene when the permanent canines were fully erupted to protect the dentition from dental caries and wear. A hybrid composite resin was chosen for occlusal overlay of the molar teeth and for crown buildup of the incisor, canine, and premolar teeth due to its esthetic appearance and durability. Splinting the incisor and canine teeth and both premolar and first molar teeth, should achieve sufficient strength and retention. An esthetic and functional interim restoration will suffice until definitive orthodontic, periodontic, and prosthodontic treatment¹⁹⁻²¹ can be undertaken at the completion of dental and facial development.

Conclusion

The etiology of the enamel defects must remain uncertain. A coincidental autosomal recessive defect unrelated to CAH may be present in this child with consanguineous parents. Chronological, systemically mediated enamel defects also could have occurred due to the multiple neonatal events and episodes of childhood illness with associated hyperpyrexia and endocrine and metabolic imbalance sustained in this child. The sparing of the permanent lower incisors and first molar teeth could be due to the accelerated dental development occurring in CAH patients.

Dr. Hallett was senior registrar, pediatric dentistry, and Dr. Hall director and chief pediatric dental surgeon, Department of Dentistry, Royal Children's Hospital, Melbourne, Australia, at the time of this case report.

1. New MI, White PC, Pang S, Dupont B, Speiser PW: The congenital adrenal hyperplasias. In: *The Metabolic Basis of Inherited Disease*, 6th Ed. Scriver CR, Beaudet AL, Sly WS, Valle D, Eds. New York: McGraw Hill, 1989, pp 1881-1917.
2. White PC, New MI, Dupont B: Congenital adrenal hyperplasia (1) and (2). *N Engl J Med* 316:1519-24, 1580-86, 1987.
3. New MI: Prenatal diagnosis and treatment of adrenogenital syndrome (Steroid 21-hydroxylase deficiency). *Dev Pharmacol Ther* 15:200-10, 1990.
4. Klingensmith GJ, Garcia SC, Jones HW Jr, Migeon CJ, Blizzard RM: Glucocorticoid treatment of girls with congenital adrenal hyperplasia: effects on height, sexual maturation, and fertility. *J Pediatr* 90:996-1004, 1977.
5. Scully C, Cawson RA: Complications of corticosteroid therapy. In: *Medical Problems in Dentistry*, 2nd Ed. Bristol: Wright, 1987, pp 240-45.
6. Glick M: Glucocorticosteroid replacement therapy: a literature review and suggested replacement therapy. *Oral Surg Oral Med Oral Pathol* 67:614-20, 1989.
7. Hall RK: Developmental defects of tooth enamel. In: *Pediatric Orofacial Medicine and Pathology*, 1st Ed. London: Chapman and Hall, 1994, pp 10-11, pp 184-202, p 391.
8. Pindborg JJ: Aetiology of developmental enamel defects not related to fluorosis. *Int Dent J* 32:123-34, 1982.
9. Lau EC, Slavkin HC, Snead ML: Analysis of human enamel genes: insights into genetic disorders of enamel. *Cleft Palate J* 27:121-30, 1990.
10. Salido EC, Yen PH, Koprivnikar K, Loh-Chung Y, Shapiro LJ: The human enamel protein gene amelogenin is expressed from both the X and the Y chromosome. *Am J Hum Genet* 50:303-16, 1992.
11. Goodman AH, Armelagos GJ: The chronological distribution of enamel hypoplasia in human permanent incisor and canine teeth. *Arch Oral Biol* 30:503-7, 1985.
12. Speigel RN, Sather AH, Hayles AB: Cephalometric study of children with various endocrine diseases. *Am J Orthod* 59:362-75, 1971.
13. Anneroth G, Bloom G: Structural changes in the incisors of cortisone-treated rats. *J Dent Res* 45:229-35, 1966.
14. Hall RK: Microradiographic study of induced enamel defects of rat molar enamel. *J Dent Res (Abstr #2)* 55:517, 1976.
15. Spiegel RJ, Vigersky RA, Oliff AI, Echelberger CK, Burton J, Poplack DG: Adrenal suppression after short term corticosteroid therapy. *Lancet* 1:630-33, 1979.
16. Shusterman S, Fellers FX: The prevalence of enamel defects in childhood nephrotic syndrome. *ASDC J Dent Child* 36:435-40, 1969.
17. Rada RE, Hasiakos PS: Current treatment modalities in the conservative restoration of amelogenesis imperfecta: a case report. *Quintessence Int* 21:937-42, 1990.

18. Mackie IC, Blinkhorn AS: Amelogenesis imperfecta: early interception to prevent attrition. *Dent Update* 18:79-80, 1991.
19. Patel RA, Hovijitra S, Kafrawy AH, Bixler D: X-linked (recessive) hypomaturation amelogenesis imperfecta: a prosthodontic, genetic, and histopathologic report. *J Prosthet Dent* 66:398-402, 1991.
20. Wright JT, Waite P, Mueninghoff L, Sarver DM: The multidisciplinary approach managing enamel defects. *J Am Dent Assoc* 122:62-65, 1991.
21. Greenfield R, Iacono V, Zove S, Baer P: Periodontal and prosthodontic treatment of amelogenesis imperfecta: a clinical report. *J Prosthet Dent* 68:572-74, 1992.

Most childhood leukemia survivors able to overcome school problems

Dose of cranial radiotherapy and age of diagnosis big education-related risk factors

Most childhood survivors of acute lymphoblastic leukemia overcome school problems even though they are more likely to enter a special education or learning disabled program, according to an article in a recent *Journal of the American Medical Association*.

Riccardo Haupt, MD, Clinical Epidemiology Branch, National Cancer Institute, Bethesda, Maryland, Lonnie Zeltzer, MD, Department of Pediatrics, UCLA Medical Center, Los Angeles, California, and colleagues analyzed data to determine the impact of treatment on scholastic performance in the first cohort of survivors of childhood acute lymphoblastic leukemia who are old enough to have completed their educational experience.

"This large study demonstrates that childhood acute lymphoblastic leukemia survivors have a greater likelihood of being placed in special education or learning disabled programs than their siblings, but that most are able to overcome these problems. Dose of cranial radiotherapy and age at diagnosis are the most important education-related risk factors," the researchers conclude.

The study consisted of 593 adult survivors of childhood acute lymphoblastic leukemia and 409 sibling controls. Outcome measures included enrollment in special programs, grades during high school,

graduation from high school, college admission, and college graduation.

"Our findings confirm that survivors experience some difficulties during the school years. On average, leukemia survivors had lower grades, higher enrollment rates into special education or learning disabled programs, and they spent a longer time in these programs. They were also at higher risk of missing school for long periods and/or repeating one year of school. On the other hand, our data show that most all survivors have rates of high school graduation, college entry, and college graduation that are similar to those of their brothers and sisters. Only survivors treated with 2,400 cGy cranial radiotherapy (a relatively high amount of irradiation therapy treatment) and those diagnosed at a preschool age were at a higher risk of poor educational performance and this group should be especially targeted for remediation," the authors write.

"Complications of treatment and the trauma of having cancer itself may continue to exert an influence well beyond the end of treatment. Time spent in the hospital or in an outpatient clinic reduces school attendance, with a consequent potential reduction in scholastic performance. Body changes, such as weight gain, hair loss, or growth deficits, have been reported to alter the patient's self-esteem, with diminished expectations and reduced school performance."