

## Progeria in a pediatric dental patient: literature review and case report

Michael F. Hasty, DDS William F. Vann, Jr., DMD, MS, PhD

### Abstract

*A case of a 10-year-old black male with progeria is presented. The report focuses on diagnosis, medical history, prognosis, treatment options, and recommendations for the management of future cases. The oral-facial characteristics and dental findings are emphasized in this case report.*

Progeria, or Hutchinson-Gilford syndrome, is a rare congenital disorder characterized by the general appearance of premature aging. The original description of this syndrome was made by Hutchinson (1886) who described a 3 1/2-year-old boy with "a very peculiar withered or old-mannish look." Later, Gilford (1897, 1904) described 3 patients with premature aging and coined the term "progeria."

Although infants with this condition are usually the products of an uncomplicated delivery, suspicious findings may be present at birth. These include scleroderma, midfacial cyanosis, and sculptured nose (DeBusk 1972). Typically the disease manifests itself by the end of the first year of life with loss of hair and failure to thrive (DeBusk 1972). Symptoms include alopecia, decreased subcutaneous fat, and relative enlargement of the joints.

All children with progeria look remarkably similar. Approximately 80% have almost identical characteristics (Brown 1985). The typical face exhibits a beak-like nose, micrognathia, crowding of the teeth, exophthalmos, prominent scalp veins, and loss of eyelashes and eyebrows (Manschot 1950; Thomson and Forfar 1950; Mostafa and Gabr 1954; Atkins 1954; DeBusk 1972; Brown 1985). Although the cranial vault appears relatively large compared to the small face, the vault size is normal with a tendency toward frontal bossing (DeBusk 1972; Beauregard and Gilchrest 1987). The cranial fontanelles close either relatively late or persist throughout life (Hutchinson 1886; Gilford 1904; Manschot 1950; Thomson and Forfar 1950; DeBusk 1972; Gamble 1984). The ears are often protrusive while the fingernails are

short, thin, and dystrophic (DeBusk 1972). The joints, especially the knee, elbow, and finger joints, are relatively enlarged and become progressively stiffer with age (DeBusk 1972; Brown 1985). Affected individuals have high-pitched voices that remain high pitched even with age (DeBusk 1972; Brown 1985).

Most patients die during their second decade due to acute myocardial infarction, congestive heart failure, or cerebrovascular accident secondary to atherosclerosis (DeBusk 1972). The mean life span is 13.4 years with a range of 7-27 years (DeBusk 1972). The oldest survivor was reported recently by Ogihara et al. (1983) who described a 45-year-old man with progeria.

In 13 cases verified by autopsy, cardiovascular findings confirm that the syndrome displays many features of the aging process (Baker et al. 1981). Findings reveal many vascular abnormalities including calcification of the aortic and mitral valves, the coronary arteries and aorta, as well as cardiac enlargement, myocardial infarction, generalized atherosclerotic changes, and narrowing of the small intramural arteries (DeBusk 1972; Baker et al. 1981).

Treatment for progeria is complicated because the pathogenesis of the atherosclerosis is not understood clearly. McNamara et al. (1970) placed a child patient on a polyunsaturated fat diet that failed to delay the development of atherosclerosis. Coronary artery bypass surgery was successful in controlling the pain of angina pectoris in an adolescent patient who also had cataracts (Dyck et al. 1987).

The diagnosis of progeria is confirmed with radiographs (Jyoti et al. 1981). Gilford (1904) described the first hand radiograph of a 16-year-old patient as being "the size...equal to that of a child of about 3, and the ossification...like that which is usual at about the twentieth year." Radiographic features (Franklyn 1976) include: (1) progressive disappearance of the clavicles starting from the ends; (2) progressive widening of the skull sutures with diminution of the jaws causing mi-

crognathia and crowding of the teeth; (3) attenuation of the terminal phalanges of the hands and feet without soft tissue loss; (4) coxa valga due to softening of the hip joints; and (5) thinning of the ribs and long bones with poor molding and delayed development. The radiographic findings are remarkably consistent and have been reported by numerous authors (Thiers and Nahan 1933; Doub 1953; Schwarz 1962; Macleod 1966; Ozonoff and Clemett 1967; Margolin and Steinbach 1968; Reichel et al. 1971).

The etiology of progeria is relatively obscure. Growth hormone responses are reported to be normal but patients display a degree of insulin resistance that resembles the aging state (Villem et al. 1969; Rosenbloom et al. 1970). Rosenbloom et al. (1983) described a case of true diabetes in a female patient. Villem et al. (1969) reported 2 male patients who displayed highly cross-linked collagen. He suggested that their muscle atrophy was indicative of reduced synthesis of actin and myosin. This hypothesis also may explain the taut, shiny, and wrinkled appearance of the skin. Goldstein (1969) added support to this theory when he cultured fibroblast from a 9-year-old boy with progeria. The cultured fibroblasts survived only 2 subcultures, in contrast to 20-30 subcultures in age-matched control subjects.

Reichel et al. (1971) proposed that progeria originates during early mesodermal development and differentiation because of involvement of blood vessels, muscle, and bone. Brown et al. (1978) suggested a basic defect in DNA metabolism. Hyaluronic acid, thought to be important in the morphogenesis of blood vessels, was evaluated by Zebrower et al. (1986) in 11 patients. They concluded that elevated hyaluronic acid may result in inhibition of angiogenesis, which could result in accelerated senescence.

Because progeria has no recognized chromosomal abnormality or biochemical marker and because patients have not been known to reproduce, a mode of inheritance is difficult to determine. Autosomal recessive inheritance has been proposed. This seems unlikely because there is a low incidence of consanguinity (Mostafa and Gabr 1954; Brown and Darlington 1980). Brown (1985) pointed out that a set of progeric twins from Brazil had 14 normal siblings. This further disproves the autosomal recessive route of transmission, because for an autosomal recessive condition to occur, approximately 25% of the siblings should be affected.

A more likely mode of transmission is that of a *de novo* dominant mutation related to advanced paternal age (DeBusk 1972; Brown 1985). The incidence of progeria in the United States has been estimated at 1 per 8,000,000 births (DeBusk 1972). DeBusk also noted that since 1886 there have been approximately 100 diagnosed cases worldwide (personal communication 1988).

Although progeria is a rare syndrome, it has been

reported widely in the medical literature, probably because of its fascinating clinical features. Only a few cases have been reported in the dental literature. Album and Hope (1958) described a 10 1/2-year-old white male with progeria who had micrognathia, limited mouth opening, microglossia, and crowding of the primary teeth. Radiographically, the pulp chambers appeared to be partially obliterated as a result of secondary dentin formation. Wesley et al. (1979) presented the clinical features of a 10-year-old patient with an extreme skeletal Class II malocclusion, anterior open bite, and a generally "retarded" dental development.

Gardner and Majka (1969) and Stanley (1972) presented the dental findings of a 10 1/2-year-old patient during autopsy. The histologic examination of a permanent lateral incisor revealed a large quantity of irregular secondary dentin that filled much of the pulp chamber. An unerupted permanent canine demonstrated a small amount of irregular secondary dentin formation. In an unpublished dental survey of 10 patients, Chialastri and Rosenbaum (personal communication 1988) noted the characteristic features of micrognathia, skeletal Class II malocclusion, generalized crowding, and delayed eruption of both the primary and permanent dentitions.

The purpose of this case report is to present a case of Hutchinson-Gilford syndrome (progeria) with special emphasis on the dental findings in this case.

## Case Report

### Medical History

SS is a black male born May 10, 1977 to nonconsanguinous parents (Figs 1, 2 - next page). He was the 5-pound, 4-ounce product of a full-term pregnancy with spontaneous vaginal delivery. Gestation was normal with no complications at birth. At approximately 6 months of age, he presented with atrophic skin to the Pediatric Rheumatology Clinic at Duke University. The provisional diagnosis was progressive systemic sclerosis vs. progeria. By age 1, the patient began to lose hair. A skin biopsy showed atrophic skin with increased collagen around sweat glands, a finding consistent with scleroderma. There was no follow-up care until 3 years, 2 months. At that age a thorough physical examination revealed a chronically ill child who was quite thin and had a relatively large cranium compared to his face. His weight was less than the 5th percentile, representing an increase in weight of only 0.6 kg from the previous year. He had fine, downy hair over the scalp, and the skin over his trunk, particularly at the axilla, was markedly freckled. The head and neck examination revealed a head circumference that was less than the 5th percentile. The scalp featured a prominent venous pattern. Chest

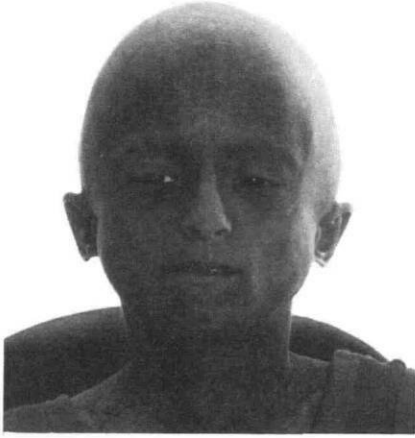

FIG 1 (left). Frontal view of SS at age 9 years, 11 months.

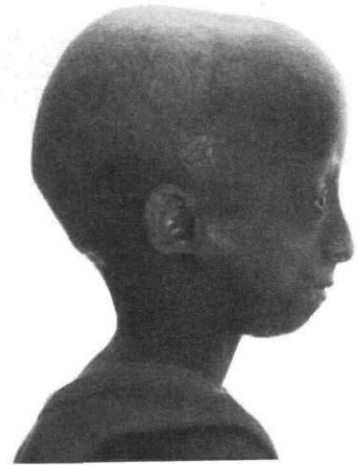

FIG 2. (right) Profile view of SS at age 9 years, 11 months.

and cardiac exams were normal. Both wrists and hips demonstrated a limited range of motion. The terminal phalanges of all the fingers appeared to be shortened. Strength was below normal but roughly appropriate for someone with such a reduced muscle bulk. At this appointment the presumptive diagnosis was progeria.

By age 9, the patient presented with almost complete alopecia and dry, pigmented skin. A cardiac examination revealed a Grade II/VI systolic murmur. The musculoskeletal examination disclosed arthritic changes resembling those of osteoarthritis, especially in the hands and hips (Fig 3). The hips had markedly reduced flexion and rotation.

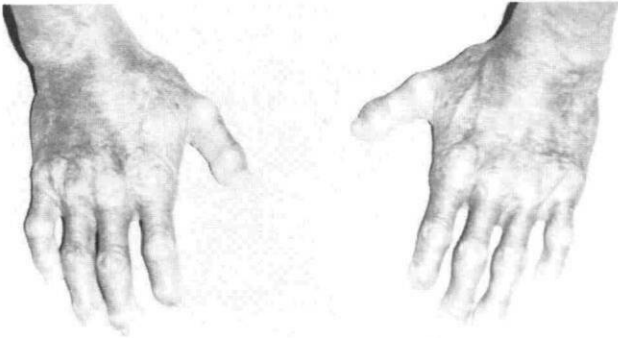


FIG 3. SS's hands at age 9 years, 11 months.

### Dental Findings

The earliest dental record for SS was a panoramic radiograph obtained at age 3 years, 8 months by a private dentist (Fig 4). All 20 primary teeth were present radiographically, although the second primary molars were not erupted fully. The dental age of the patient was younger than 2 years, or approximately 18-24 months behind his chronological age.

SS was referred to the University of North Carolina-Chapel Hill Department of Pediatric Dentistry at age 6 years, 10 months for evaluation of gingival recession associated with several primary molars. An extraoral exam revealed a characteristic progerian facies with almost complete alopecia, sculptured nose, and micrognathia. An intraoral exam revealed a complete primary dentition of 20 teeth. Even though the child was almost 7 years old, there were no permanent teeth present clinically.

Oral hygiene was poor with a generalized mild marginal gingivitis. Moderate gingival recession was associated with the mandibular first primary molars, causing thermal sensitivity for the patient. The permanent central incisors demonstrated localized areas of enamel hypoplasia.

Posterior bite-wing radiographs revealed second primary molars with partially obliterated pulp chambers and canals. No radiographic or clinical decay was noted. There was interradicular and horizontal bone loss noted mesial to the mandibular first primary molars. The second premolars were not evident on the panoramic radiograph (Fig 5).

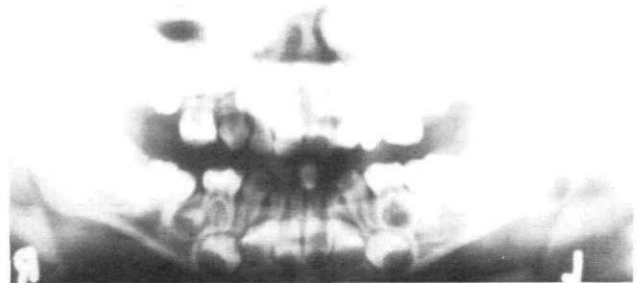

Fig 4. SS at age 3 years, 8 months. Note that the dental age is younger than 2 years.

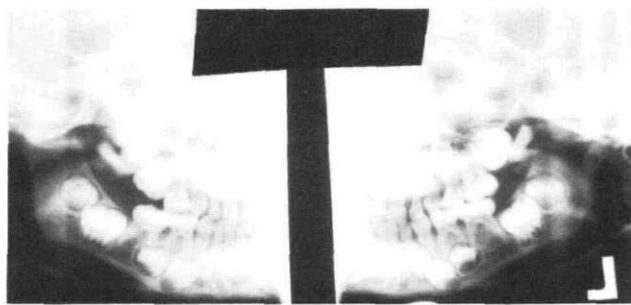


FIG 5. Age 6 years, 10 months.

The child's pediatrician recommended antibiotic coverage for SBE for dental treatment secondary to his heart murmur. After a periodontal consultation for the gingival recession, it was recommended that the patient's mother apply a stannous fluoride gel to the exposed root surfaces of the mandibular first primary molars to reduce sensitivity. After this first treatment appointment, the patient was unavailable for follow-up evaluation.

At age 9 years, 11 months, SS presented for an emergency visit with a chief complaint of "crooked teeth" and "bleeding gums." Limited mouth opening was observed secondary to taut perioral tissues. An intraoral examination revealed an early mixed dentition. The lower left first primary molar was absent for unknown reasons. The only permanent teeth that were present clinically were the 4 permanent maxillary incisors and 3 permanent mandibular incisors. Both permanent maxillary lateral incisors were erupting lingual to their predecessors.

Moderate decay was present on the primary molars as well as the mesial surfaces of the maxillary central incisors. Moderate amounts of plaque were present throughout the dentition. The patient demonstrated a generalized marginal gingivitis. Gingival recession was associated with several primary molars and periodontal probing of these teeth revealed 3- to 5-mm periodontal pockets. Hemorrhage was present at the crevicular margin of several of the primary molars. The hard palate was not vaulted. The soft palate, buccal mucosa, tongue, and floor of the mouth all appeared to be within normal limits.

A radiographic survey included 2 bite-wings, 2 periapicals, and a panoramic radiograph (Fig 6). The 4 second premolars were absent on the radiographs. Horizontal and vertical bone loss with furcal involvement was apparent in all 4 quadrants involving the primary molars. Subgingival calculus was present radiographically involving the mandibular right first and second primary molars. The pulp canals and chambers of the second primary molars were partially obliterated. Also, the mandibular condyles were severely atrophic.

A tentative diagnosis of localized prepubertal periodontitis was made based on clinical and radiographic features. A microbiological sample was obtained from a periodontal pocket using an endodontic point. The microorganisms present were black-pigmented *Bacteroides*, *Haemophilus actinomycetemcomitans*, and normal oral flora. The presence of gram-negative anaerobic bacteria was considered an unusual finding. SS satisfied many of the criteria for localized prepubertal periodontitis, including early onset (6 years), minimal gingivitis, pocket formation, and moderately rapid but localized bone loss (Page et al. 1983). However, the child was not tested for defective peripheral blood leukocyte function.

Treatment included extraction of 4 primary molars due to significant mobility, gingival recession, root resorption, and bone loss. The maxillary canines and a remaining primary incisor were extracted due to extreme mobility and to facilitate the facial migration of the permanent lateral incisors. Because the patient had poor plaque control with concomitant gingivitis, he was placed on a chlorhexidine gluconate (0.12%) mouth rinse.

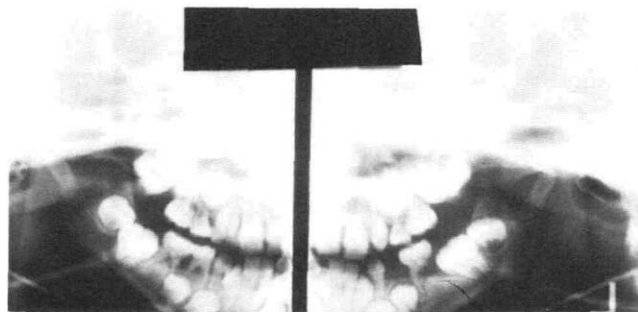


Fig 6. SS at age 9 years, 11 months. Note bone loss in the primary molar areas.

To date the child has only been seen twice for palliative care. Restorative and preventive care have not been implemented fully, and definitive care in the future is unlikely because of poor parental compliance.

## Discussion

Although the literature is rather sparse regarding the dental aspects of progeria, several common features seem to be present in reported cases. The eruption and exfoliation times of the primary dentition are usually markedly delayed (DeBusk 1972). The permanent dentition is often delayed in eruption and may be characterized by hypodontia or oligodontia. This was a consistent finding in every case reviewed from a dental perspective.

Patients usually have a hypoplastic mandible associated with a severe skeletal Class II malocclusion, a steep mandibular plane angle, and an anterior open bite. It has been hypothesized that the development of mandibular hypoplasia is secondary to the taut perioral tissues that restrict mandibular growth. This would seem to be a plausible hypothesis considering the high prevalence of scleroderma and mandibular hypoplasia; however, a cause-and-effect relationship should not be assumed. This phenomenon may simply reflect the fact that the facial bones are generally hypoplastic, resulting in craniofacial disproportions. Thus, a genetic etiology rather than an environmental one would appear to be a more likely explanation for the mandibular hypoplasia.

Previous dental case reports have not mentioned periodontal problems associated with progeria. Our patient had significant periodontal problems. Although peripheral blood leukocyte function tests were not undertaken, a diagnosis of localized prepubertal periodontitis was made because the clinical findings fit the diagnostic criteria. The identification of *H. actinomycetemcomitans* in the subgingival microflora supported the diagnosis and pathophysiology of prepubertal periodontitis, even though the presence of black-pigmented *Bacteroides* was suggestive of a more adult form of periodontal disease. There was also evidence of subgingival calculus which is not a usual characteristic of prepubertal periodontitis.

Progeria mimics the aging process in many regards. However, some systems appear to be immature or dysplastic. The dental development of these children is markedly delayed. The eruption times of both the primary and permanent dentitions are unusually tardy, although the sequence is that which would be expected in an early mixed dentition. The permanent premolars and canines rarely erupt, even in older individuals. Varying degrees of oligodontia and anodontia are manifested. In addition, the permanent teeth are often hypoplastic and discolored, although they are usually of normal size and shape. Finally, there is significant crowding and displacement of the permanent anterior teeth.

The authors thank Drs. W. Ted Brown, Roslyn Moore Crisp, and Carol R. Drinkard for their contributions and Ms. Jo Ann Blalock for the preparation of this manuscript.

Dr. Hasty is a fellow and Dr. Vann is an associate professor and chairman, pediatric dentistry, University of North Carolina. Reprint requests should be sent to: Dr. Michael F. Hasty, Dept. of Pediatric Dentistry, CB #7450, Brauer Hall, University of North Carolina School of Dentistry, Chapel Hill, NC 27599-7450.

Album MM, Hope JW: Progeria — report of a case. *Oral Surg* 11:985-98, 1958.

- Atkins L: Progeria — report of a case with post-mortem findings. *N Engl J Med* 250:1065-69, 1954.
- Baker PB, Baba N, Boesel CP: Cardiovascular abnormalities in progeria — case report and review of the literature. *Arch Pathol Lab Med* 105:384-86, 1981.
- Beauregard S, Gilchrest BA: Syndromes of premature aging. *Dermatol Clin* 5:109-21, 1987.
- Brown WT: Genetics of human aging. *Rev Biol Res Aging* 2:105-14, 1985.
- Brown WT, Little JB, Epstein J, Williams JR: DNA repair defect in progeric cells. *Birth Defects* 14:417-30, 1978.
- Brown WT, Darlington GJ: Thermolabile enzymes in progeria and Werner syndrome — evidence contrary to the protein error hypothesis. *Am J Hum Genet* 32:614-19, 1980.
- DeBusk FL: The Hutchinson-Gilford progeria syndrome. *J Pediatr* 80:697-724, 1972.
- Doub HP: Progeria. *Med Radiogr Photogr* 29:60-62, 1953.
- Dyck JD, David TE, Burke B, Webb GD, Henderson MA, Fowler RS: Management of coronary artery disease in Hutchinson-Gilford syndrome. *J Pediatr* 11:407-10, 1987.
- Franklyn PP: Progeria in siblings. *Clin Radiol* 27:327-33, 1976.
- Gabr M, Hashem N, Hashem M, Fahmi A, Safouh M: Progeria, a pathologic study. *J Pediatr* 57:70-77, 1960.
- Gamble JG: Hip disease in Hutchinson-Gilford progeria syndrome. *J Pediatr Orthop* 4:585-89, 1984.
- Gardner PG, Majka M: The early formation of irregular secondary dentin in progeria. *Oral Surg* 28:877-84, 1969.
- Gilford H: On a condition of mixed premature and immature development. *Med Chirurg Trans* 80:17-45, 1897.
- Gilford H: Progeria — a form of senilism. *Practitioner* 73:188-217, 1904.
- Goldstein S: Lifespan of cultured cells in progeria. *Lancet* I:424, 1969.
- Hutchinson J: Congenital absence of hair and mammary glands. *Med Chirurg Trans* 69:473-77, 1886.
- Jyoti V, Gadekar HA, Harchandani K: Progeria. *Indian Pediatr* 18:827-28, 1981.
- Macleod W: Progeria. *Br J Radiol* 39:224-26, 1966.
- Manschot WA: A case of progeronanism (progeria of Gilford). *Acta Paediatr* 39:158-64, 1950.
- Margolin FR, Steinbach HL: Progeria — Hutchinson-Gilford syndrome. *Am J Roentgenol* 103:173-78, 1968.
- McNamara BGP, Farn KT, Mitra AK, Lloyd JK, Fosbrooke AS: Progeria — case report with long-term studies of serum lipids. *Arch Dis Child* 45:553-60, 1970.
- Mostafa AH, Gabr M: Heredity in progeria with follow-up of two affected sisters. *Arch Pediatr* 71:163-72, 1954.

- 
- Ogihara T, Hata T, Tanaka K, Fukuchi K, Tabuchi Y, Kumahara Y: Hutchinson-Gilford progeria syndrome in a 45-year-old man. *Am J Med* 81:135-38, 1986.
- Ozonoff MB, Clemett AR: Progressive osteolysis in progeria. *Am J Roentgenol* 100:75-79, 1967.
- Page RC, Bowen T, Altman L, Vandesteen E, Ochs H, Mackenzie P, Osterberg S, Engel LD, Williams BL: Prepubertal periodontitis. I. Definition of a clinical disease entity. *J Periodontol* 54:257-71, 1983.
- Reichel W, Bailey JA, Zigel S, Garcia-Bunvel R, Knox G: Radiological findings in progeria. *J Am Geriatr Soc* 19:657-74, 1971.
- Reichel W, Bailey JA, Zigel S: Radiological findings in progeria. *J Am Geriatr Soc* 19:369-75, 1971.
- Rosenbloom AL, Karacan IJ, DeBusk FL: Sleep characteristics and endocrine response in progeria. *J Pediatr* 77:692-95, 1970.
- Rosenbloom AL, Kappy MS, DeBusk FL, Francis GL, Philpot TJ, Maclaren NK: Progeria — insulin resistance and hyperglycemia. *J Pediatr* 102:400-402, 1983.
- Schwarz E: Roentgen findings in progeria. *Radiology* 79:411-14, 1962.
- Stanley HR: The effect of systemic diseases on the human pulp. *Oral Surg* 33:606-48, 1972.
- Thiers J, Nahan: Etude radiographique due squelette dans un cas de progeria de Gilford (nanisme senile) dysostose cleidocranienne associee. *J Radiol Electrol Med Nucle* 17:675, 1933.
- Thomson J, Forfar JO: Progeria (Hutchinson-Gilford syndrome) — report of a case and review of the literature. *Arch Dis Child* 25:224-34, 1950.
- Villee DB, Nichols G Jr, Talbot NB: Metabolic studies in two boys with classical progeria. *Pediatrics* 43:207-16, 1969.
- Wesley RK, Delaney JR, Litt R: Progeria — clinical considerations of an isolated case. *ASDC J Dent Child* 46:487-92, 1979.
- Zebrower M, Kieras FJ, Brown WT: Urinary hyaluronic acid elevation in Hutchinson-Gilford progeria syndrome. *Mech Aging Dev* 35:39-46, 1986.
- 

**The American Board of Pediatric Dentistry  
Announces the  
Following New Diplomates**

**William S. Deeley ~ Hampton, VA**  
**Christopher J. Luccy ~ Greensburg, PA**  
**Harry E. Martin ~ Overland Park, KS**  
**Gayle V. Plauka ~ Chesapeake, VA**  
**Douglas R. Reich ~ Philadelphia, PA**  
**Michael B. Rulnick ~ Vineland, NJ**  
**Preston G. Shelton ~ Baltimore, MD**