



Custom oral appliance for noninvasive immobilization during stereotactic radiotherapy

Carole Havelka, DDS, MS Linda P. Nelson, DMD, MScD Stephen Shusterman, DMD Marc Bellerive, MS

Stereotactic pertains to a precise positioning in space. Stereotactic radiotherapy is a successful noninvasive modality for treating intracranial malignancies. Stereotactic radiosurgery was developed as a noninvasive tool to allow access to areas of the head that were previously treated by traditional surgical methods with a high rate of morbidity. As radiotherapy was refined, different stereotactic systems allowed for increasingly precise delivery of therapeutic radiation while minimizing collateral damage to normal tissues. Fractionated irradiation techniques generally have been found to be better tolerated by normal tissue and to allow for higher cumulative target doses as a result of repair between fractions.¹ Intracranial neoplasms, such as pituitary adenoma, craniopharyngioma, large meningiomas, large acoustic neuromas, gliomas, as well as retinoblastomas are the lesions targeted for stereotactic radiotherapy.² Even in these relatively small lesions, it is imperative that the beam position allow safe delivery of radiation therapy without an excessive dose to critical normal structures, such as the eyes. Some stereotactic devices use pins for fixation, which can cause superficial skin infections and cannot be tolerated for more than 58 days.¹ Other devices have been developed to permit longer treatment times with lower doses of radiation at each session. For example the Laitinen stereoadaptor has a head frame that is mounted in a noninvasive way to the patient's head by means of two ear plugs and a nasal support.³ A second example is the Gill-Thomas frame, which is stabilized on the patient's head with polyethylmethacrylate polymer maxillary and mandibular dental impressions, a vinyl polysiloxane occipital support and three quick release nylon straps. This frame was modified in Boston to be the Gill-Thomas-Cosman [GTC] frame (Radionics, Burlington, MA) and uses a velcro headstrap, a vinyl polysiloxane occipital support with modified support mounting, and a specifically designed intraoral appliance fabricated in the pediatric dental clinic for repositioning.

Fractionated irradiation techniques generally have been found to be better tolerated by normal tissue and

to allow for higher cumulative target doses as a result of repair between fractions.

Stereotactic radiotherapy often is performed by having the patient wear a stereotactic frame secured by pins to the soft and hard tissues of the cranial vault. The Gill-Thomas frame, which was invented in England, used extraoral devices to secure it in position, together with an intraoral dental impression. The GTC frame² uses an intraoral device to allow rapid, precise alignment of the frame to the patient's head⁴ (Fig 1). This paper will review stereotactic radiation therapy and the current immobilization system based on the GTC frame. Because this technique achieves a high success rate, pediatric dentists should be knowledgeable in fabricating this appliance.

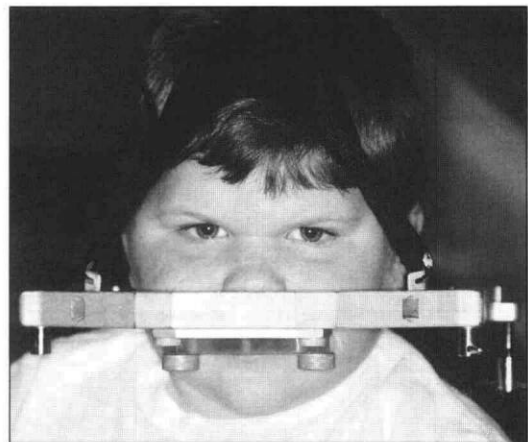


Fig 1. The Gill-Thomas-Cosman frame.

Fabricating the dental appliance

1. Alginate impressions and a wax bite are taken of the patient's upper and lower teeth.
2. The patient's facial midline is marked on the tray and later transferred to the stone casts. The marking of the midline allows for proper alignment of the oral appliance within the frame and permits the patient to be positioned comfortably.
3. The impressions are poured in die stone@.

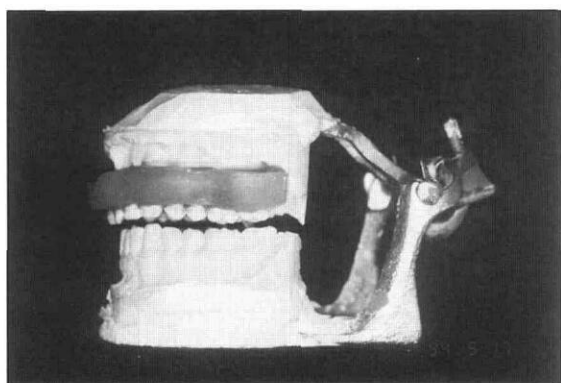


Fig 2. Casts mounted with a 2-mm openbite. Wax is placed on the buccal surfaces of the maxillary teeth, leaving 3 mm uncovered at the incisal edges.

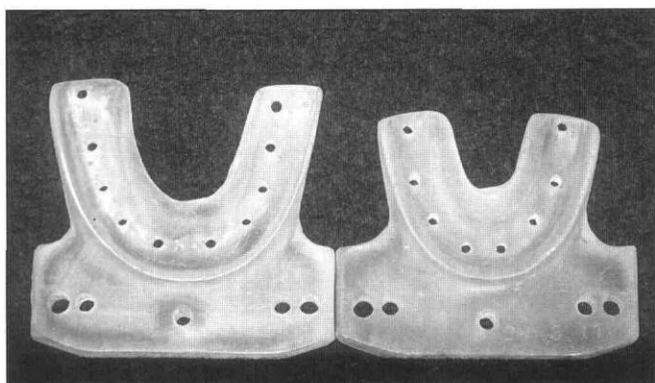


Fig 3. Prefabricated acrylic molds. Large and small sizes shown.




Fig 4. The "depth confirmation helmet."

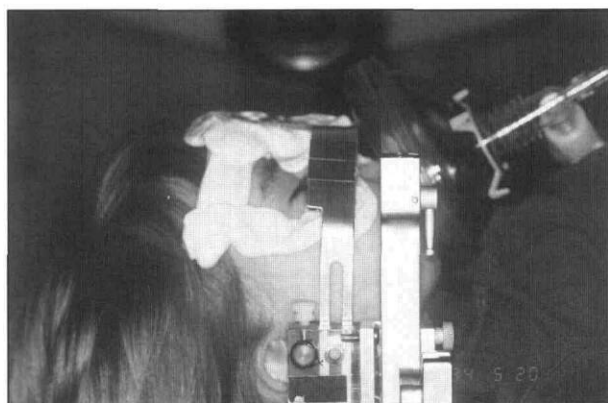


Fig 5. The Boston Children's frame with face mask.

4. The casts are mounted with a 2-mm openbite on a hinge-type articulator, using the wax bite (Fig 2).
5. A prefabricated acrylic mold in one of three possible sizes is chosen (Fig 3). The junction between the mold and the frame has an angulation of 30°.
6. Adams clasps are fabricated for the maxillary first molars and ball clasps for the posterior interproximal areas.
7. Wax is placed on the buccal surfaces of the maxillary teeth to remove the undercuts, leaving 3 mm uncovered at the incisal edges (Fig 2).
8. The prefabricated acrylic mold is then held on the upper teeth using the midline marking and the occlusal plane to achieve the correct three dimensional position.
9. Powder and liquid is mixed to make acrylic, which is added between the maxillary teeth and the prefabricated mold.
10. The acrylic is then cured under pressure.
11. Acrylic is placed between the mandibular teeth and the mold and similarly cured, to give mandibular occlusal registration.
12. The appliance is separated from the casts and

excess acrylic is removed. It is important to smooth the outside acrylic surfaces to increase patient comfort during extended wear and to ensure that undercuts are not present for easy insertion and removal.

13. The appliance is then ready for try-in with the patient (Fig 6-9).

Technique for use of GTC frame

The patient is placed in the treatment position with the head ring bolted to a couch-mounted system. To check that the position of the head ring has not changed from treatment to treatment over a course of 30 sessions, a rod is inserted through the "depth confirmation helmet" (Fig 4). This helmet consists of a hemispherical dome, which allows a measurement of the depth to the cranial base from 25 fixed positions. Eighty percent of these 25 fixed measurement points are required to be within ± 0.5 –1.0 mm. A complete set is measured prior to each of the 30 fractionated treatments. At our institution to date more than 140 patients ranging in age from 5 to 71 years have been treated with stereotactic radiation therapy using 25 to 30 treatment fractions over a 6-week duration. For children younger than age 7 years, who are unable to cooperate

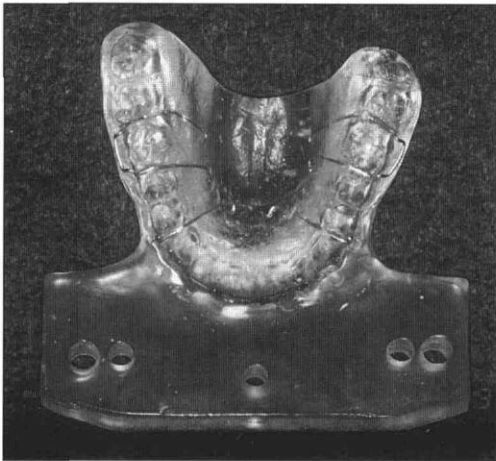

Fig 6. Intraoral component of stereotactic appliance, top view.

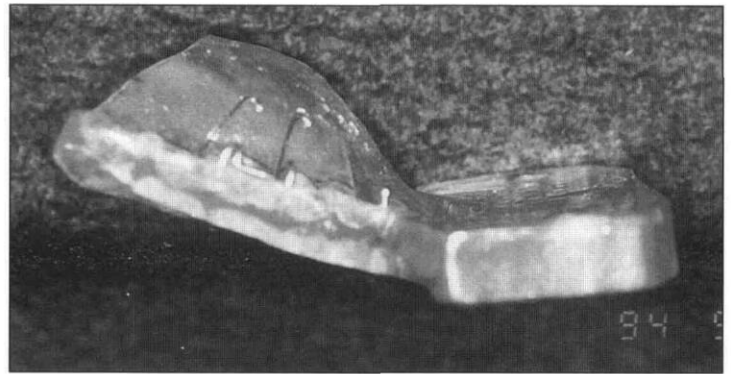


Fig 7. Intraoral component of stereotactic appliance, side view.

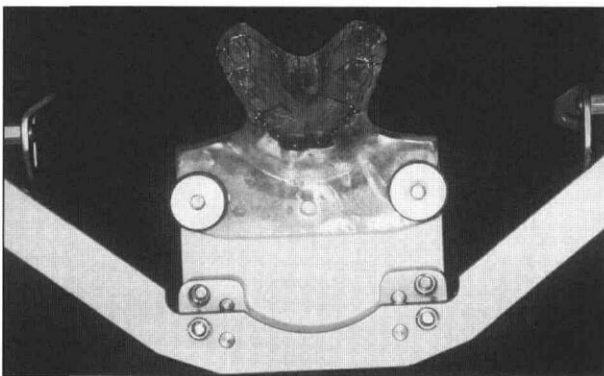


Fig 8. Intraoral component of stereotactic appliance mounted on frame.

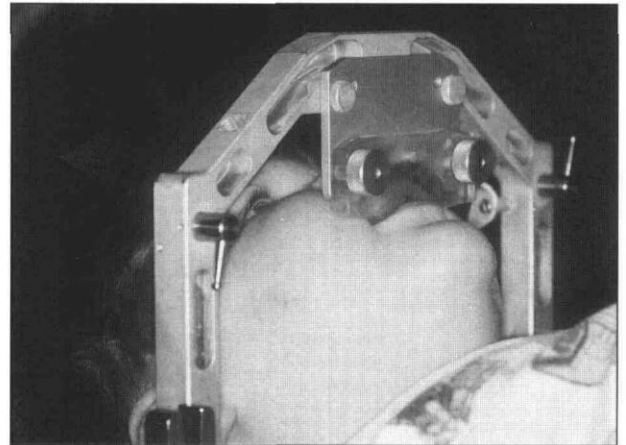


Fig 9. The Gill-Thomas-Cosman frame is shown with intraoral component seated in patient's mouth.

for the fixation using an intraoral device, the Boston Children's frame is used under general anesthesia for each of the 25 to 30 treatment fractions over a 6-week duration. This frame uses the nasal glabellar region (face mask) rather than the oral cavity as the site of stabilization (Fig 5). The cooperative children (usually between 4 and 6 years) can use the Boston Children's frame without general anesthesia.

Discussion

An ideal radiation therapy intracranial fixation device should be noninvasive, well-tolerated, and accurately relocatable. When in position it should be rigidly fixed relative to the skull and should provide complete immobilization. The mounting of the head should be adaptable and the frame should be compatible with as many forms of imaging as possible and suitable for stereotactic instruments and radiotherapy.⁵ The GTC frame, with its modified intraoral appliance, meets these requirements and allows at least 80% of the fixed measurement points to be within ± 0.5 –1.0 mm during each of the 30 days of fractionated stereotactic radiotherapy. The GTC frame can be worn for these multiple treatment sessions. Additionally, the frame eliminates the potential source of tissue necrosis and infection created

by the contact points of the skull vault pins used in stereotactic radiotherapy. A disadvantage of the GTC frame is that the patient must be able to tolerate a maxillary intraoral appliance, which may be particularly difficult for young children. Thus, the Boston Children's frame (face mask) is necessary (Fig 5). Additionally, in obese patients, the angle at which the oral appliance attaches to the frame has to be increased to prevent an uncomfortable tilt of the head during radiotherapy.

Conclusion

The Gill-Thomas-Cosman frame, with its modified intraoral appliance, meets the requirements of an ideal radiation therapy intracranial fixation device. As this technique becomes more mainstream, it is important for the pediatric dentist to understand the rationale for stereotactic radiotherapy, its use, and appliance fabrication.

Dr. Havelka is senior staff in pediatric dentistry, Children's Hospital, Boston, and clinical instructor in pediatric dentistry, Harvard School of Dental Medicine. Dr. Nelson is senior staff in pediatric dentistry, Children's Hospital, Boston, and clinical instructor in pediatric dentistry, Harvard School of Dental Medicine. Dr. Shusterman is dentist-in-chief, Children's Hospital, Boston, and assistant clinical professor in pediatric dentistry, Harvard School

of Dental Medicine. Dr. Bellerive is assistant chief, Stereotactic Center, Brigham and Women's Hospital, and medical physicist, Joint Center for Radiation Therapy, Harvard Medical School.

1. Schwade JG, Houdek PV, Landy HJ, Bujnoski JL, Lewin AA, Abitol AA, Serago CF, Pisciotta VJ: Small-field stereotactic external-beam radiation therapy of intracranial lesions: fractionated treatment with a fixed-halo immobilization device. *Radiol* 176:563-65, 1990.
2. Delannes M, Daly NJ, Bonnet J, Sabatier J, Tremoulet M: Fractionated radiotherapy of small inoperable lesions of the brain using a non-invasive stereotactic frame. *Int J Radiat Oncol Biol Phys* 21:749-55, 1991.
3. Graham JD, Warrington AP, Gill SS, Brada M: A non-invasive, relocatable stereotactic frame for fractionated radiotherapy and multiple imaging. *Radiother Oncol* 21:60-62, 1991.
4. Kooy HM, Dunbar SF, Tarbell NJ, Mannarino E, Ferarro N, Shusterman S, Bellerive M, Finn L, McDonough CV, Loeffler JS: Adaptation and verification of the relocatable Gill-Thomas-Cosman frame in stereotactic radiotherapy. *Int J Radiat Oncol Biol Phys* 30:685-91, 1994.
5. Gill SS, Thomas DG, Warrington AP, Brada M: Relocatable frame for stereotactic external beam radiotherapy. *Int J Radiat Oncol Biol Phys* 20:599-603, 1991.

Future Annual Sessions of the American Academy of Pediatric Dentistry

49th Annual Session
May 24-28, 1996

Chicago

Chicago Marriott Hotel

51st Annual Session
May 21-26, 1998

San Diego

San Diego Marriott Hotel & Marina

50th Annual Session
May 22-27, 1997

Philadelphia

Philadelphia Marriott Hotel

52nd Annual Session
May 27-June 1, 1999

Toronto

Sheraton Centre of Toronto Hotel & Towers