

## Caries-like lesion formation around occlusal alloy and preventive resin restorations

M. John Hicks, DDS, MS, PhD

### Abstract

*Secondary caries-like lesion formation around occlusal alloy and preventive resin restorations was studied using an artificial caries system and polarized light microscopy. Both alloy and resin restorations prevented secondary lesion formation to a significant extent. However, the preventive resins experienced no lesion formation along the enamel-resin interface. Preventive resins could serve as an alternative to occlusal alloy restorations in certain clinical situations.*

The dental profession long has recognized the problem of dealing with pit and fissure caries. During the 1920s, two different clinical techniques were introduced to combat the problem of occlusal caries. Thaddeus Hyatt advocated the prophylactic odontotomy.<sup>1,2</sup> This procedure consisted of preparing a conservative Class I cavity that included all pits and fissures and then placing an alloy restoration. The rationale for this prophylactic restoration was that the procedure prevented future insult to the pulp from caries and required less time to restore than when the tooth eventually succumbed to caries. Bödecker presented a more conservative approach toward occlusal caries prevention.<sup>3</sup> The eradication of fissures was advocated to transform deep, retentive areas into cleansable ones. Essentially, these two clinical techniques were employed until the widespread use of sealants became prevalent.

With the introduction of sealants, it became possible to prevent caries in a sound occlusal surface to a significant extent. However, the dental profession still is confronted with the problem of the questionable occlusal surface. The question has been whether to seal or to restore the surface. A clinical procedure for caries restoration and simultaneous caries prevention using the acid-etch technique, known as the preventive resin restoration, was introduced by Simonsen in 1978.<sup>4</sup> This restoration offers an alternative to either sealing over a questionable oc-

clusal surface or restoring that surface with an alloy. The technique involves both widening of the pits and fissures and removal of enamel which appears to be affected by caries. This cavity, prepared in enamel, then may be etched and sealed with a resin material.

The purpose of this in vitro study was to compare caries-like lesion formation around Class I occlusal alloy restorations and Type A preventive resin restorations. The Type A preventive resin restoration involves minimal preparation of the pits and fissures with either a No. ¼ or ½ round bur prior to sealant placement.<sup>5</sup> The artificial caries system<sup>6</sup> employed in this study has been used previously to investigate secondary caries formation around Class V alloy and composite resin restorations.<sup>7-10</sup>

The histopathology of caries-like lesions associated with secondary caries has been described.<sup>7</sup> The lesions consist of two parts, an outer surface lesion and a cavity wall lesion. The outer surface lesion has the characteristic features of primary enamel caries. The wall lesion is positioned adjacent to the enamel-restoration interface. It is thought that the wall lesion is formed by diffusion of hydrogen ions from the artificial caries medium into the microspace between the enamel and restoration. This results in a caries-like attack on the enamel surface of the cavity wall. The caries-like lesion, once formed, progresses perpendicular to the cavity wall. Therefore, the ability of a restorative material to resist a secondary caries-like attack may be quantified by measuring the depth of the cavity wall lesion perpendicular to the enamel-restoration interface, then comparing this depth with the outer surface lesion depth.

### Methods and Materials

Thirty extracted molar and premolar teeth with occlusal enamel caries were selected for this in vitro study (Figure 1). The criteria for selection of the teeth were: (1) the fissures must be intact; (2) the fissures must "catch"

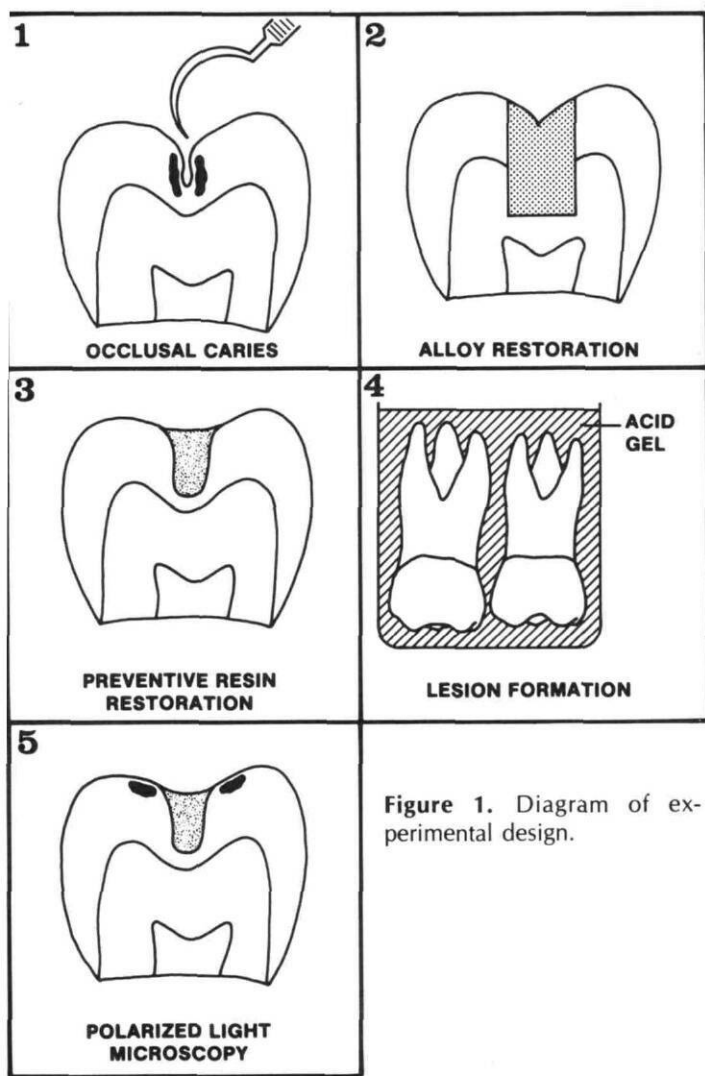


Figure 1. Diagram of experimental design.

the explorer; and (3) an opaque, chalky appearance along the fissures suggestive of clinical incipient occlusal caries must be present. The teeth were assigned randomly to two separate groups according to the restorative treatment to be performed. The occlusal surfaces were restored with either an alloy,<sup>a</sup> or an unfilled resin.<sup>b</sup>

With the occlusal alloy portion of the study, Class I cavity preparations extending into dentin were performed using inverted cone burs (No. 33) in a high-speed handpiece. Following a thorough rinsing and drying procedure, two coats of a cavity varnish were applied to the cavity preparation. The occlusal preparations then were restored with a spherical alloy.<sup>a</sup> Subsequently, the specimens were stored in a humid environment for 20 weeks.

In the preventive resin portion of the study, Type A preventive cavities were prepared in the occlusal surfaces of the 15 remaining specimens. The Type A preventive cavity involved minimal preparation of the pits and fissures with either a No. ¼ or ½ round bur prior to sealant placement.<sup>5</sup> With this study, No. ½ round burs in a high-speed handpiece were used to remove enamel

<sup>a</sup> Dispersalloy, Johnson & Johnson Co.; East Windsor, N.J. 08561.

<sup>b</sup> Delton, Johnson & Johnson Co.; East Windsor, N.J. 08561.

and questionable enamel. This resulted in widened and deepened fissures along the entire occlusal surface. The preparations were examined visually and tactilely to make certain that the enamel caries had been removed. All preparations were maintained within enamel. At this time, the occlusal surfaces were cleaned thoroughly with a fluoride-free prophylaxis paste using a slow-speed handpiece. Following a water rinse and air drying, the prepared fissures and surrounding occlusal surfaces were etched for 60 seconds with the etching solution provided by the manufacturer. The teeth were washed with water for 30 seconds and air-dried for 30 seconds. An unfilled resin<sup>b</sup> was placed into the etched preventive cavities (attention was given to confining the resin material only to the prepared fissures). The specimens with preventive resin restorations then were stored in a humid environment for 20 weeks.

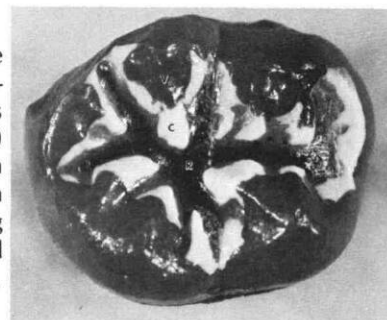
After removal from the storage medium, an acid-resistant varnish was applied to the teeth leaving a 1 mm rim of exposed sound enamel adjacent to the restorations. At this time the teeth with alloy and preventive resin restorations were exposed to an acidified gelatin (pH 4.0). This artificial caries system produces lesions that are indistinguishable from naturally occurring caries.<sup>6</sup>

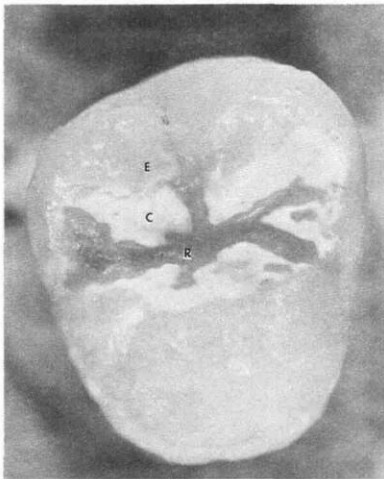
After an appropriate exposure period (10-12 weeks), caries-like lesion formation had occurred adjacent to the restorations (Figure 2). A number of longitudinal sections were prepared from the specimens using a Silverstone-Taylor Hard Tissue Microtome<sup>c</sup> (Figure 3). Ground sections were prepared to a thickness of approximately 100 µm for polarized light study.

The prepared sections were examined by polarized light microscopy while imbedded in water. Two zones of enamel caries may be seen when a lesion is viewed in water, the negatively birefringent surface zone and the positively birefringent body of the lesion. Ten sections from each of the restored teeth were evaluated for evidence of secondary caries formation. If microleakage had occurred between the cavity wall and the restoration, a cavity wall lesion would be present. The depth of the lesion, as measured perpendicular to the cavity wall, determines the degree to which a restorative material can prevent a secondary caries attack. The maximum depth of each wall lesion was measured along a traverse perpendicular to the enamel cavity wall. For comparative purposes, the

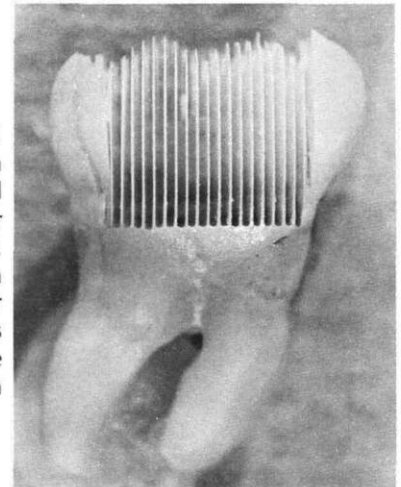
<sup>c</sup> Scientific Fabrications; Littleton, Colo. 80123.

Figure 2a. The typical appearance of an occlusal surface following exposure to the artificial caries medium. The caries-like lesion (C) surrounding the preventive resin restoration (R) can be seen as an opaque white band. The remaining occlusal surface has been protected with an acid-resistant varnish (V).





**Figure 2b.** The acid-resistant varnish has been removed from this tooth prior to sectioning. The caries-like lesion (C) can be distinguished easily from the preventive resin restoration (R) and sound enamel (E). The ability of the acid-resistant varnish to protect the underlying sound enamel is evident.



**Figure 3.** Longitudinal sections 100-125  $\mu\text{m}$  in thickness were prepared using a Silverstone-Taylor Hard Tissue Microtome. Ten sections from each tooth were prepared for polarized light study. As many as 19 sections were available for study with some specimens.

maximum depth of each outer surface lesion was measured along a traverse from the enamel surface to the advancing front of the lesion. Data were collected from 150 sections for each restorative material. Student's *t*-tests were performed with a significance level of  $p \leq 0.05$ .

## Results

Outer surface lesions were present for each section examined, regardless of the restorative material used. The mean depth for outer lesions from teeth restored with the alloy material was 180  $\mu\text{m}$  (Table 1). The mean outer lesion depth for occlusal surfaces restored with the resin material was 205  $\mu\text{m}$ . These depths were comparable for both restorative treatment procedures and were not significantly different. However, mean depths for outer lesions and cavity wall lesions were significantly different for both treatment groups. In addition, the difference between the mean depths for cavity wall lesions for teeth restored with either alloy or preventive resin was significant at  $p < 0.05$ . The mean cavity wall depth for an occlusal cavity restored with the alloy material was 42  $\mu\text{m}$ . Each section examined for the alloy restoration treatment group possessed a wall lesion. These wall lesions ranged from 18  $\mu\text{m}$  to 87  $\mu\text{m}$ . In marked contrast, no cavity wall lesions were observed for occlusal surfaces restored with preventive resins. This is remarkable considering that the outer surface lesion depths were similar for both the alloy and preventive resin treatment groups.

### Histopathologic Appearance of Secondary Caries-Like Lesions

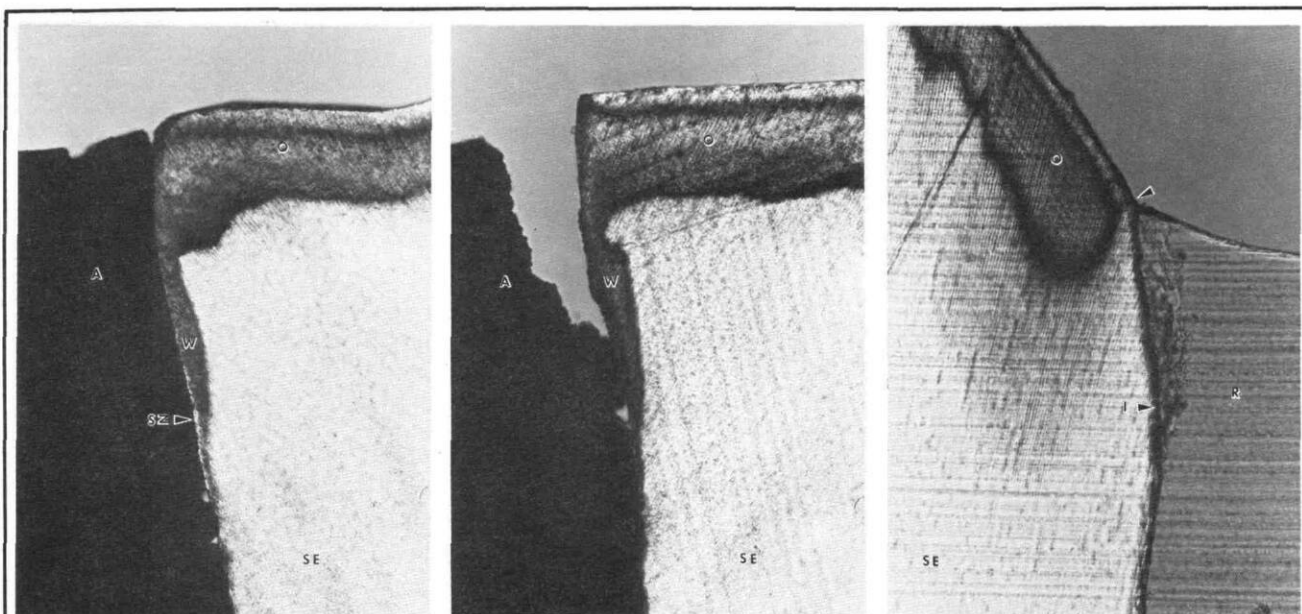
The occlusal surfaces of the teeth restored with the alloy material possessed both outer surface and cavity wall lesions in each case (Figures 4 & 5). The outer surface lesions possessed surface zones approximately 25-30  $\mu\text{m}$  in depth. The bodies of the lesion had relatively smooth or flat advancing fronts. This indicated that the acidified gel was providing a constant diffusion gradient of hydrogen ions. However, the presence of the surface zones provided evidence that the dynamic process associated with enamel caries had occurred. The cavity wall lesions had a characteristic appearance. Typically,

the cavity wall lesions were elongated in shape with the portion of the lesion situated toward the dentinoenamel junction tapering down to a pseudoisotropic band of demineralized enamel measuring approximately 10  $\mu\text{m}$  in depth. The most superficial portion of the wall lesion was usually 40-50  $\mu\text{m}$  in depth when measured perpendicular to the prepared cavity wall. This area represented the greatest depth of enamel affected by the secondary caries attack. In the majority of specimens, the wall lesions extended along the cavity walls to lengths of 550-750  $\mu\text{m}$  from the enamel surface toward the dentinoenamel junction. Surface zones for the cavity wall lesions appeared either negatively birefringent or pseudoisotropic. The surface zones in the portions of the lesions that were affected to a greater depth ( $< 30 \mu\text{m}$ ) were, most often, pseudoisotropic. Negatively birefringent surface zones were found when the wall lesion depth was  $\leq 30 \mu\text{m}$ . Of particular interest was the fact that the alloy restorations did not survive the section preparation procedure very well. Large fragments of the alloy restorations were lost from the surfaces of the restorations with smaller fragments lost adjacent to the cavosurfaces. Total loss of the restoration occurred during sectioning and grinding of the sections with approximately 30 per cent of the specimens.

**Table 1.** Secondary Caries-Like Lesion Formation Around Alloy and Preventive Resin Restorations

Restoration Type	No. of Teeth	No. of Sections Examined	Wall Lesion Depth ( $\bar{x} \pm \text{S.D.}$ )	Outer Lesion Depth ( $\bar{x} \pm \text{S.D.}$ )
Alloy	15	150	42 $\pm$ 10 $\mu\text{m}^{\text{a,b}}$	180 $\pm$ 38 $\mu\text{m}^{\text{b}}$
Preventive Resin	15	150	0 $\pm$ 0 $\mu\text{m}^{\text{a,c}}$	205 $\pm$ 45 $\mu\text{m}^{\text{c}}$

*Student's t-test — Significant Differences at  $p < 0.05$ : (a) between wall lesion depths for alloy and preventive resin restorations, (b) between wall lesion and outer lesion depths for alloy restorations, and (c) between wall lesion and outer lesion depths for preventive resin restorations.*



**Figure 4.** Secondary caries-like lesion formation has involved both the outer surface and cavity wall of this specimen restored with an alloy (A). The outer surface lesion (O) is composed of a negatively birefringent surface zone and positively birefringent body of the lesion. The depth of the outer lesion is 170  $\mu\text{m}$ . The cavity wall lesion (W) can be seen running parallel to the adjacent alloy restoration. The wall lesion extends 40  $\mu\text{m}$  into the enamel at its greatest depth. The lesion tapers down to a pseudoisotropic band of affected enamel measuring approximately 10-15  $\mu\text{m}$  in depth. A surface zone (SZ) can be seen along the cavity wall, indicating the perpendicular direction of attack by the artificial caries medium. SE = Sound Enamel. (Water imbibition, Polarized Light 160x).

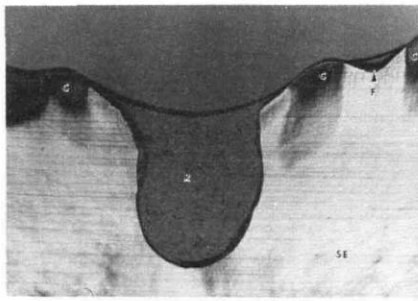
**Figure 5.** Secondary caries-like formation has occurred as indicated by the presence of an outer surface lesion (O) and a cavity wall lesion (W). The outer lesion depth is 190  $\mu\text{m}$ , while the wall lesion depth is 70  $\mu\text{m}$  at its greatest point. The wall lesion appears as an extended wedge-shape with its apex directed toward the dentino-enamel junction. The alloy restoration (A) has been lost partially during section preparation. Although a negatively birefringent surface zone is present with the outer lesion, either a pseudoisotropic surface zone or a positively birefringent surface layer overlies the wall lesion. SE = Sound Enamel. (Water imbibition, Polarized Light 160x).

**Figure 6.** Only an outer surface lesion (O) can be seen with this photomicrograph of a tooth restored with a preventive resin (R). The boundary (arrow) of the outer lesion terminates at the point where the etched enamel is bonded to the resin material. No evidence of a cavity wall lesion can be seen along the enamel-resin interface (I). The resin appears to be adapted closely to the enamel cavity wall. SE = Sound enamel. (Water imbibition, Polarized Light 160x).

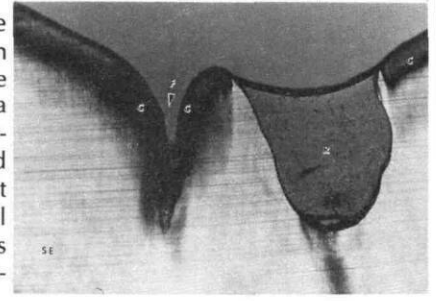
In contrast, no wall lesions were observed for teeth restored with the resin material (Figure 6), although the outer surface lesion depths were comparable for both restorative treatment groups (Table 1). In fact, the mean outer lesion depth was greater for the preventive resin treatment group. Typically, the outer surface lesion terminated at the point where bonding had occurred between the etched-enamel cavity wall and preventive resin. The enamel-resin interface was intact and appeared to be an intimate one. No evidence of restoration loss was noted with specimens restored with resin, unlike the alloy restorations. Occasionally, supplementary grooves that were not included in the Type A cavity preparation were sealed (Figure 7). The presence of even a minimal thickness of resin protected the supplementary grooves from the caries-like attack. In addition, fissures that were caries free and not restored were observed to have developed caries-like lesions along the walls and bases

of their fissures (Figure 8). However, adjacent fissures that had been prepared and sealed with the preventive resin possessed outer lesions that extended up to the point where the preventive resin commenced, but no cavity wall lesions existed.

Also of interest was the width of the cavity preparations at the cavosurfaces. Since the Type A preventive cavity was prepared using a No.  $\frac{1}{2}$  round bur, the preparation was dependent on the size of the fissure prepared and the amount of affected enamel. In general, the typical preventive cavity was from .5 to 1 mm in width at the cavosurface. With the alloy preparation, it was necessary to practice extension for prevention. This resulted in preparations ranging from 1.5 to 2.5 mm in width at their cavosurfaces.



**Figure 8.** (right) The contrast between the protection against caries-like lesion formation afforded by a preventive resin (R) and the susceptibility of an untreated fissure (F) to a caries-like attack is evident in this photomicrograph. Caries-like lesions (C) have formed along the walls of the fissures and adjacent to the interface between the surface enamel and preventive resin. No cavity wall lesions can be seen. SE = Sound Enamel. (Water imbibition, Polarized Light, 80x).



**Figure 7.** (left) The ability of resin-treated enamel to resist a caries-like attack is illustrated further with this specimen. A supplementary fissure (F) has been sealed with a minimal thickness (<50  $\mu\text{m}$ ) of resin. The supplementary fissure has been protected by the resin, as evidenced by the caries-like lesions (C) present in adjacent enamel that was not sealed. Most likely, the resin covering the supplementary fissure would not be detected clinically. Also, no lesions can be seen along the cavity walls of the preventive resin restoration (R). SE = Sound Enamel. (Water imbibition, Polarized Light, 80x).

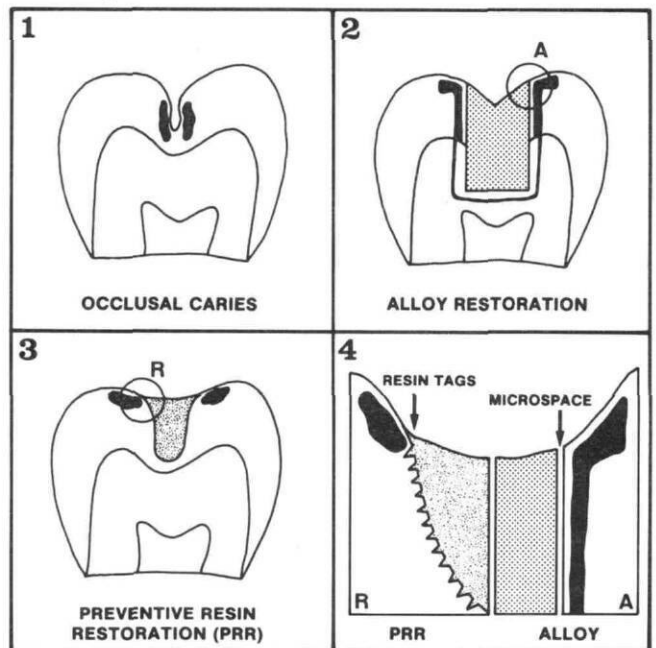
## Discussion

It is particularly important that a restorative material be able to resist a secondary caries attack at its margin. Both alloy and preventive resin restorations were capable of affecting that portion of the secondary caries-like lesion formed due to microleakage, the cavity wall lesion. Wall lesion depths for alloy and preventive resin restorations were significantly less than depths for outer surface lesions. With preventive resin restorations, no cavity wall lesions were formed. In unfilled cavities, the wall lesion depth has been reported to be equal to or greater than that for the outer surface lesion.<sup>10,11</sup> This would tend to suggest that once a restoration is placed in a cavity, access to the cavity by hydrogen ions is restricted to a substantial extent.

Secondary caries-like lesion formation has been shown to be dependent upon the degree to which a restorative material can prevent microleakage at the enamel-restoration interface (Figure 9). The ability of resin-treated enamel to resist either an in vitro or in vivo caries attack is well documented.<sup>12-14</sup> The enamel-resin interface is composed of interdigitating etched enamel prisms and resin tags. These resin tags provide protection for the enamel against acid dissolution. In fact, sealed enamel has been shown to be more resistant to dissolution by organic acids than sound enamel alone.<sup>11-13</sup> Even enamel surfaces that have lost their protective resins experience a lessened solubility rate<sup>13</sup> and caries incidence<sup>14</sup> than sound enamel. Residual resin tags that cannot be detected either clinically or microscopically have been suggested to be responsible for this continued protection against demineralization.

In the present study, occlusal alloy restorations experienced significantly greater degree of involvement with secondary caries than preventive resins. No doubt the presence of wall lesions was due to diffusion of hydrogen ions along a microspace between the cavity wall and alloy restoration. The formation of wall lesions also may be due to defects in the restorative material at the periphery

of the restoration, or to defects in the enamel adjacent to the cavity wall.<sup>11</sup> Although wall lesion formation occurred, the alloy restoration prevented the progress of the lesion to a significant extent. The wall lesions were never equal to the outer surface lesions in depth. The dif-



**Figure 9.** Secondary caries-like lesion formation around alloy and preventive resin restorations. The restoration of a questionable occlusal surface with a resin may result in a more conservative approach. The involvement of the cavity wall with caries-like lesions may depend upon the ability of the restorative material to adapt to the cavity. With alloy restorations, a microspace may exist between the restoration and enamel cavity wall. With time, corrosion products may partially occlude this space. However, this microspace may allow diffusion of hydrogen ions along the cavity wall and result in wall lesion formation in both the enamel and dentin. With preventive resin restorations, the enamel-resin interface is composed of interdigitating etched-enamel prisms and resin tags. This interface may prevent formation of caries-like lesions along the cavity walls.

ference between these depths was significant. In the clinical situation, the alloy restoration may respond differently due to the formation of corrosion products that could further reduce the microspace between the alloy and cavity wall. Also, metal ions in the alloy may have a detrimental effect on the microorganisms in plaque that are responsible for wall lesion formation.<sup>15</sup>

An added benefit of the acid-etch technique is its effect on microorganisms. Studies involving resin placement over frank carious lesions have shown that significant reductions in the number of viable microorganisms occur within the first two weeks and result in a 99.9% decrease in viable microorganisms after a two-year period.<sup>16-18</sup> In fact, it has been shown that the acid-etching procedure itself may reduce viable microorganisms by up to 75%.<sup>18</sup>

The preventive resin restoration may serve as an alternative to the alloy restoration in certain clinical situations. First, the preventive resin is a conservative method for restoring either a questionable occlusal surface or an occlusal surface with caries in isolated pits and fissures. Since supplementary grooves would be protected with a resin, it would not be necessary to practice extension for prevention. Second, the preventive resin may be useful especially with young children. The procedure requires only minimal preparation and may involve only isolated areas where dentin will be exposed. The limited amount of preparation could alleviate the need for anesthesia. Third, should marginal breakdown occur, the resin may be repaired easily, whereas an alloy restoration must be replaced entirely. Fourth, if recurrent caries should develop, only the affected tissue needs to be removed and resin added to the existing preventive resin.

The preventive resin restoration may not be an alternative to the occlusal alloy in other clinical situations. With occlusal surfaces requiring extensive restoration of stress-bearing areas, an alloy restoration may be preferable until more conclusive research regarding the longevity and physical strength of posterior resins is completed. Preventive resins definitely would be contraindicated when a dry field cannot be maintained.

## Conclusions

The results from this in vitro study indicate that:

1. Preventive resin restorations provide an effective barrier against a caries-like attack. This is thought to be due to the presence of resin tags in intimate contact with etched enamel prisms.
2. Occlusal alloy restorations are not as effective as preventive resin restorations in providing protection against a caries-like attack. The presence of lesions along the cavity walls may be due to a microspace

between the prepared enamel and alloy restoration.

3. The preventive resin restoration may serve as an alternative to the occlusal alloy restoration in certain clinical situations.

Supported by NIH-NRSA Individual Postdoctoral Fellowship 5F32 DE0 5256-03.

The author thanks Mr. Harvey F. Evans, Jr. for his technical assistance, and Ms. Wanda Valentine for helping prepare this manuscript.

Dr. Hicks is an assistant professor, Dental Research Unit and Department of Growth and Development, School of Dentistry, University of Colorado Health Sciences Center; Denver, Colo. 80262. Reprint requests should be sent to him.

1. Hyatt, T.P. Occlusal fissures: their frequency and danger. How shall they be treated? *Dent Items of Interest* 46:493-507, 1924.
2. Hyatt, T.P. Prophylactic odontotomy: the ideal procedure in dentistry for children. *Dent Cosmos* 78:353-70, 1936.
3. Bödecker, C.F. The eradication of enamel fissures. *Dent Items of Interest* 51:859-66, 1929.
4. Simonsen, R.J. Preventive resin restorations (I). *Quintessence Int* 1:69-76, 1978.
5. Simonsen, R.J. Preventive resin restorations: three-year results. *JADA* 100:535-39, 1980.
6. Silverstone, L.M. The histopathology of enamel lesions produced in vitro and their relation to enamel caries. PhD Thesis, University of Bristol, 1967.
7. Hals, E., Nernaes, A. Histopathology of in vitro caries developing around silver amalgam fillings. *Caries Res* 5:58-77, 1971.
8. Hals, E., Kvinnsland, I. Structure of experimental in vitro and in vivo lesions around composite (Addent XV®) fillings. *Scand J Dent Res* 82:517-26, 1974.
9. Kidd, E.A.M. Microleakage in relation to amalgam and composite restorations. A laboratory study. *Br Dent J* 141:305-10, 1976.
10. Kidd, E.A.M. The histopathology of artificial lesions created in vitro in relation to unfilled and filled cavities. *Caries Res* 11:173-77, 1977.
11. Hicks, M.J., Silverstone, L.M. Fissure sealants and dental enamel. A histological study of microleakage in vitro. *Caries Res* 16:353-60, 1982.
12. Hicks, M.J., Silverstone, L.M. The effect of sealant application and sealant loss on caries-like lesion formation in vitro. *Pediatr Dent* 4:111-14, 1982.
13. Silverstone, L.M. Fissure sealants: the susceptibility to dissolution of acid-etched and subsequently abraded enamel in vitro. *Caries Res* 11:46-51, 1977.
14. Hinding, J. Extended cariostasis following loss of pit and fissure sealants from human teeth. *J Dent Child* 41:201-3, 1974.
15. Tinanoff, N., Weeks, D.B. Current status of SnF<sub>2</sub> as an anti-plaque agent. *Pediatr Dent* 1:199-204, 1979.
16. Handelman, S.L., Washburn, F., Wopperer, P. Two-year report of sealant effect on bacteria in dental caries. *JADA* 93:697-70, 1976.
17. Handelman, S.L., Leverett, D.H., Solomon, E.S., Brenner, C.M. Use of adhesive sealants over occlusal carious lesions: radiographic evaluation. *Community Dent Oral Epidemiol* 9:256-59, 1981.
18. Jensen, O.E., Handelman, S.L. Effect of an autopolymerizing sealant on viability of microflora in occlusal dental caries. *Scand J Dent Res* 99:382-88, 1980.