

## The effect of glutaraldehyde pulpotomy treatment on pulpal enzymes

Sharon D. Hill, DDS, MS N. Sue Seale, DDS, MSD E. Matthew Quintero, BS Ingrid Y. Guo, PhD

### Abstract

*The enzymes lactate dehydrogenase (LD), succinate dehydrogenase (SD), alkaline phosphatase (AP), and glucose-6-phosphate dehydrogenase (G-6-PD) were evaluated at specific locations in pulp tissue following glutaraldehyde pulpotomies. Pulpotomies were performed on maxillary first molars in 40 rats after sacrifice at times 0, 24 hr, seven days, or one month, and experimental teeth were treated with 6% buffered glutaraldehyde. Teeth were prepared for frozen sectioning and the sections were subjected to incubation media to detect each enzyme. Significant differences were found regarding the location of staining and the time intervals at which stain was present or absent. Staining for LD and AP was the most intense throughout the four observation time periods, though staining for these enzymes as well as for G-6-PD had begun to diminish by day seven in the coronal thirds. Staining was completely absent in the coronal thirds at one month but remained in the middle and apical thirds throughout one month. SD was the only enzyme that was totally absent in the coronal third at seven days and totally absent in the middle third at one month. These findings suggest that LD, AP, and the biochemical mechanisms that they represent remain active longer than SD and G-6-PD following exposure to glutaraldehyde. This information is important in identifying mechanisms that are important for repair, healing, and recovery following pulpal injury. (Pediatr Dent 15:337-42, 1993)*

### Introduction

In the past, the goal of pulpotomy treatment in primary teeth has been removing the diseased coronal pulp tissue followed by applying a substance capable of exerting some form of histological tissue fixation on the remaining pulpal tissues. When the undesirable and potentially harmful effects of formocresol were identified, glutaraldehyde—another tissue fixative—was suggested. Glutaraldehyde is also well known for its high degree of protein cross-linking and limited diffusibility past the point of application. Most studies have shown glutaraldehyde to be less toxic and to have fewer damaging side effects than formocresol,<sup>1-3</sup> while other reports conclude that the differences between the two agents in terms of systemic distribution, cytotoxicity, and mutagenicity are not great enough to advocate the use of one agent over the other.<sup>4,5</sup>

The search for a suitable pulpotomy agent has focused primarily on finding one that is not cytotoxic, carcinogenic, or mutagenic. Another important criterion that has not received as much emphasis has been the ability of the agent to promote healing. Repair and healing with continued viability should be a primary goal of the procedure, especially since the healing potential of the pulp is well recognized.<sup>6</sup>

One determinant of pulp viability is assessing specific enzymes that may provide information regarding pathologic or injury response processes, the alteration of normal physiologic processes, and repair and healing processes.

Since important characteristics of pulpotomy agents in the past have focused on their ability to fix tissues, investigations utilizing enzyme analysis of pulpal tissues following exposure to glutaraldehyde or formocresol have

viewed enzyme suppression as favorable, indicating that adequate tissue fixation had occurred.<sup>7,8</sup> These studies involved removing the pulp tissue from the tooth, incubating the tissue in the test substance, and measuring the enzyme activity in a spectrophotometer. Limitations of this technique include: 1) the tissue is exposed to greater amounts of the substance than would be used clinically; 2) the tissue is exposed to the substance longer than in the clinical application; and 3) specific areas of the pulp tissue cannot be evaluated. Nevertheless, these types of analyses are very important since they provide an effective measure of the biochemical activity present in tissues.

Histochemical enzyme analysis permits direct visualization and staining of localized areas of enzyme activity in intact histologic sections of prepared tissue. Morphologic features of the tissue are preserved and the tissues are treated by an *in vivo* procedure first, providing a more accurate picture of what occurs clinically.

The success of histochemical enzyme localization is well documented in soft tissues and also has been demonstrated in mineralized tissues e.g., bones and teeth.<sup>9,10</sup> However, studies utilizing histochemical enzyme assays for pulp tissue are limited. There are reports on the evaluation of human dental pulp following formocresol pulpotomies using this method as well as limited reports utilizing histochemistry to observe pulpal responses to stress.<sup>11,12</sup> These studies are quite dated and more recent reports on histochemical enzyme analysis of pulpal tissues do not appear in the literature.

In order to further determine the cytotoxicity of glutaraldehyde following pulpotomy treatment and to assess its effects on radicular tissues, enzyme analyses using histo-

chemical techniques were performed. Objectives of this study were to determine the presence, absence, localization, and time intervals of changes in specific respiratory and hydrolytic enzymes following treatment. If one of the most important characteristics of the pulpotomy agent is to maintain viability and to encourage the pulp to heal, retention of enzyme activity could be viewed as desirable. The enzymes selected in this study were felt to be representative of the biochemical processes important in pulpal response mechanisms to injury, like inflammation and hard tissue formation, which are also important events in repair and healing.

## Methods and materials

The study sample consisted of maxillary first molar teeth in 50 young male Sprague-Dawley (Harlan Sprague-Dawley Animal Co., Indianapolis, IN) rats weighing approximately 350 gm each. The rats were divided randomly into five groups of 10 each as follows: Group A was sacrificed immediately after pulpotomy treatment; Group B was sacrificed 24 hr post treatment; Group C was sacrificed seven days post treatment, and Group D was sacrificed one month post treatment. Group E did not receive any treatment and served as a control to identify enzyme activity in intact, untreated pulp tissue.

Animals were administered sodium pentobarbital (4.2 mg/100g) by intraperitoneal injection and atropine sulfate (0.5 mg/kg) by subcutaneous injection 15 min prior to pentobarbital administration to dry excessive oral secretions. All groups except for A and E also received 60,000 units of penicillin G procaine following completion of procedures.

The teeth were examined to determine that they were free from visible pathology or abnormalities. The access opening was made from the occlusal surface using a 1/2 round minibur in a high-speed handpiece with continuous water spray. Removing the coronal pulp tissue was accomplished at slower speed using the same bur. The teeth were checked visually for perforation through an illuminating magnifying lamp. Hemostasis was obtained by applying light pressure with medium-sized paper points over the amputation site. When hemorrhage was completely controlled, 1 µl of a 6% solution of buffered glutar-

aldehyde (H<sub>3</sub>PO<sub>4</sub> buffer, pH = 7.2) prepared fresh from a 25% stock solution (Sigma Chemical Co., St. Louis, MO) was deposited into the pulp chamber. It was allowed to remain in the chamber for 4 min before lightly rinsing it out with approximately 1.0 ml of sterile water and blotting the area dry. A small piece of gold foil sheet then was placed over the amputation site followed by the placement of Cavit® (Premier Dental Products Co., Norristown, PA). Gold foil, a relatively inert material, was used for direct placement over the pulp stumps to avoid direct contact of the pulpal tissues with a potentially irritating substance.

Glutaraldehyde pulpotomies were performed on either the right or left maxillary first molar in the treated animals. Pulpotomies with sterile water only were performed on the opposite maxillary molar in each animal to serve as a control for the effect of the surgical trauma alone. Sections from kidney, liver, and untreated teeth were used to determine the color and intensity of the enzyme reaction (positive controls). Negative controls consisted of exposing randomly selected tissue sections to incubation media without adding substrate.

Following animal sacrifice in a CO<sub>2</sub> chamber, two blocks (right and left halves), approximately 10 mm long and containing three molars each, were dissected from the posterior maxilla. Demineralization was accomplished by placing the blocks in 500 ml of a neutral buffered solution of 10% EDTA (Sigma Chemical Co., St. Louis, MO) in 0.1 M tris buffer adjusted to a pH of 6.95 with KOH for four days at 4° C.<sup>13</sup> The tissues were not subjected to fixative agents at any time during preparation. Demineralized specimens were embedded in OCT Compound Embedding Media® (Miles Scientific, Naperville, IL) in single plastic wells approximately 12 mm in diameter. The frozen tissue blocks then were attached to a chuck and sagittally sectioned at 8.0 µm thickness with a cryostat.

Histochemical analysis was carried out by incubating the sections in media specific for the following enzymes: alkaline phosphatase (AP), glucose-6-phosphate dehydrogenase (G-6-PD), lactate dehydrogenase (LD), and succinate dehydrogenase (SD). AP and G-6-PD were demonstrated according to the Kiernan method, using alpha naphthyl acid phosphate and D-glucose 6-phosphatase

**Table 1. Teeth used for data analysis**

	Group																			
	A					B					C					D				
Rat #/Tooth																				
<sup>†</sup> 1L 4L 3R 2L 6R	8L	10R	6L	7L	4L	10L	9R	8R	7L	3L	6R	2R	3R	4L	10L					
C1/3	•	•	•	•	•	•	•	•	•	•	•	•	•	•	•					
M1/3	•	•	•	•	•	•	•	•	•	•	•	•	•	•	•					
A1/3	•	•	•	•	•	•	•	•	•	•	•	•	•	•	•					

Group A = immediate; Group B = 24 hr; Group C = 7 days; Group D = 1 month; <sup>†</sup> Triplicate sections were stained from each tooth for each enzyme; L = Left molar; R = Right molar; C1/3 = Coronal; M1/3 = Middle; A1/3 = Apical; • Stain designated as present (3), trace (2), or absent (1).

**Table 2. Staining for alkaline phosphatase with regard to location and time period after treatment\***

Group	Coronal 1/3	Middle 1/3	Apical 1/3	Total Staining
A	3.00	3.00	3.00	3.00 (SD 0.00)
B	2.90	2.90	3.00	2.95 (SD 0.20)
C	2.00	3.00	3.00	2.71 (SD 0.58)
D	1.10	2.30	3.00	2.08 (SD 0.87)

\*Mean findings of a total of 15 observations per location and time period. Present = 3; Trace = 2; Absent = 1. Group A = immediate; Group B = 24 hr; Group C = 7 days; Group D = 1 month.

**Table 3. Staining for lactate dehydrogenase with regard to location and time period after treatment\***

Group	Coronal 1/3	Middle 1/3	Apical 1/3	Total Staining
A	2.70	3.00	3.00	2.91 (SD 0.28)
B	2.90	2.60	2.60	2.73 (SD 0.65)
C	2.20	2.90	3.00	2.68 (SD 0.46)
D	1.20	2.50	2.90	2.17 (SD 0.83)

\*Mean findings of a total of 15 observations per location and time period. Present = 3; Trace = 2; Absent = 1. Group A = immediate; Group B = 24 hr; Group C = 7 days; Group D = 1 month.

**Table 4. Staining for glucose-6-phosphate dehydrogenase with regard to location and time period after treatment\***

Group	Coronal 1/3	Middle 1/3	Apical 1/3	Total Staining
A	2.60	2.60	2.60	2.60 (SD 0.00)
B	2.60	2.60	2.60	2.60 (SD 0.00)
C	2.00	2.70	2.70	2.40 (SD 0.81)
D	1.10	1.80	2.50	1.77 (SD 0.90)

\*Mean findings of a total of 15 observations per location and time period. Present = 3; Trace = 2; Absent = 1. Group A = immediate; Group B = 24 hr; Group C = 7 days; Group D = 1 month.

**Table 5. Staining for succinate dehydrogenase with regard to location and time period after treatment\***

Group	Coronal 1/3	Middle 1/3	Apical 1/3	Total Staining
A	3.00	3.00	3.00	3.00 (SD 0.00)
B	2.70	2.90	3.00	2.93 (SD 0.25)
C	1.00	2.60	3.00	2.20 (SD 0.92)
D	1.00	1.10	1.50	1.22 (SD 0.47)

\*Mean findings of a total of 15 observations per location and time period. Present = 3; Trace = 2; Absent = 1. Group A = immediate; Group B = 24 hr; Group C = 7 days; Group D = 1 month.

respectively, as substrates.<sup>14</sup> SD was demonstrated using a modification of Kiernan's Nitro BT method with sodium succinate as the substrate;<sup>14</sup> and LD was demonstrated according to the Troyer method with Na-DL-lactate as the substrate.<sup>15</sup>

Activity was recorded as present, trace, or absent in the coronal, middle, and apical thirds of the radicular pulp of each specimen. Differences between time intervals within

groups were analyzed by descriptive statistics and the Kruskal-Wallis one-way analysis of variance with post-hoc Mann-Whitney U tests. Friedman two-way analysis of variance for related samples was used to compare differences in staining location within the same group.

## Results

Staining was successfully demonstrated for all four enzymes. Data analysis is based on five glutaraldehyde-treated molars from each of the four groups (Table 1). Even though the original study design provided for 10 treated molars from each group, some teeth were lost during dissection or cryostat sectioning. The same teeth were used to evaluate all four enzymes. Three sections from each tooth were stained to establish consistency in staining. Observations were made in the coronal, middle, and apical thirds of each section, which provided for a total of 45 observations per time period. Summary data for individual enzymes are reported in Tables 2, 3, 4 and 5. Within enzyme groups, Kruskal-Wallis one-way analysis and post-hoc Mann-Whitney U tests revealed significant differences in staining between time intervals following treatment (Table 6). Also within enzyme groups, Friedman two-way analysis of variance revealed significant differences in staining between different

locations of the pulp tissue (Table 7). Surgical trauma alone did not noticeably affect the staining, positive controls exhibited the presence of staining throughout the pulp, and negative controls yielded no staining.

### Alkaline phosphatase

Animals sacrificed immediately or at 24 hr (Groups A and B) retained the presence of AP in all three sections of

**Table 6. Kruskal-Wallis one-way analysis of variance on time interval**

Time Interval	Kruskal-Wallis Test Statistic	DF	P-value
AP	57.682	3	0.000*
LD	30.457	3	0.000*
G-6-PD	27.096	3	0.000*
SD	118.513	3	0.000*

\*  $P < .05$ ; based on a total of 45 observations per time period.

the radicular pulp. The enzyme began to diminish over time in areas closest to the point of glutaraldehyde application. Only traces of AP were present in the coronal third by seven days, but staining was still present throughout the middle and apical third (Group C). Almost all traces of stain were gone in the coronal thirds at one month (Group D), and though staining was present in the middle third and apical thirds of this group, the stain was not as dark as in the previous time period.

#### Lactate dehydrogenase

LD remained in the entire section of radicular pulp during the first 24 hr (Groups A and B), but began to diminish by day seven in the coronal third where only a trace was noted (Group C). Staining was still present in the middle and apical thirds of Group C, however. By one month (Group D), no staining was present in the coronal third, but staining was present in the middle and apical thirds.

#### Glucose-6-phosphate dehydrogenase

Activity for G-6-PD was present in the coronal, middle, and apical third sections of the radicular pulp for the first 24 hr (Groups A and B). Only a trace of enzyme was present in the coronal third section by day seven (Group C) and none in the coronal third by one month (Group D). Enzyme was still present in the apical and middle thirds at seven days but diminished to a trace in the middle third by one month.

#### Succinate dehydrogenase

Activity for SD was present throughout all sections of the radicular pulp in the immediate and 24-hr sacrifice groups (Groups A and B). By day seven, there was no evidence of any staining in the coronal third, though it remained in the middle and apical thirds. At the one-month observation, the only area with any visible activity was the apical third. Even in those areas, the staining intensity was much weaker than it had been earlier.

#### Discussion

Enzyme activity is a well-known marker of various biological processes including tooth development and injury response mechanisms. The dehydrogenases and hy-

**Table 7. Friedman two-way analysis of variance on location**

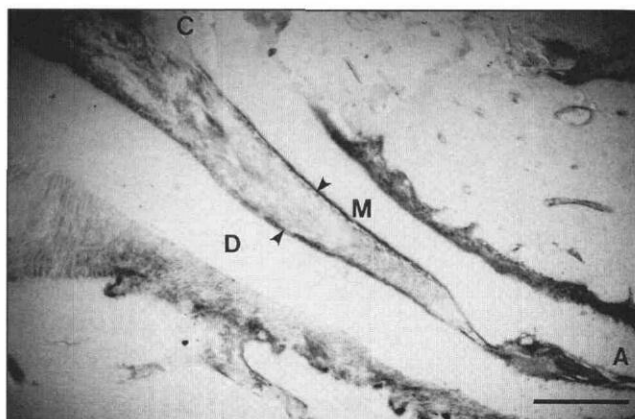
Time Interval	Friedman Test Statistic	DF	P-value
AP	16.033	2	0.000*
LD	20.433	2	0.000*
G-6-PD	10.258	2	0.005*
SD	12.900	2	0.001*

\*  $P < .05$ ; based on a total of 60 observations per location (C1/3, M1/3, A1/3).

drolytic enzymes are two enzyme groups that play important roles in these processes. Hydrolytic enzymes, e.g. AP, have been identified in various stages of tooth development and hard tissue formation, while the dehydrogenases generally are regarded as measures of metabolic activity and initiators of the energy needed for cellular differentiation and mineralization.<sup>16,17</sup>

The enzymes evaluated in this study, LD, AP, G-6-PD, and SD have been noted to exhibit marked activity in the odontoblastic layer, a finding supported by the results of this study. When staining was present, the intensity in the odontoblastic layer of the radicular pulp tissue was greater for all enzymes (Fig 1). This is of particular interest since cellular proliferation in the pulp tissue originates in the odontoblastic layer. Further studies are needed to determine what relationship—if any—this enzyme activity has to cellular proliferation and whether active cell proliferation in the odontoblastic layer is indicative of repair.

Staining for LD and AP was the most intense throughout the four observation times, though staining for both enzymes had diminished in the tissue sections closest to the application site by day seven, and was completely absent in those areas at one month. The fact that these two enzymes stained with greater intensity in this study sug-



**Fig 1. Succinate dehydrogenase activity in a section from a Group A maxillary first molar following glutaraldehyde pulpotomy treatment. Staining is visible in the apical (A), middle (M), and coronal (C) thirds and in the odontoblastic layer (arrows). D = dentin. Bar: 50  $\mu$ m. (Magnification 350x).**

gests that they may play greater roles in pulpal response mechanisms to injury. In addition to high activity in the bud, cap, and bell stages of tooth development, AP is also important in the mineralization process and synthesis of fibrous proteins.<sup>18</sup> Our findings for AP support those of Zach et al.<sup>19</sup> in which increased concentrations of the enzyme were found in pulp tissue in response to pulpal injury. Further, pulp mesenchymal cells stimulated by AP have been shown to differentiate into odontoblasts, which may then elaborate reparative dentin in response to injury.<sup>19</sup>

While the presence of AP appears to indicate a positive response of the pulp to injury, the intense staining of LD in these tissues may indicate other processes as well. A marker of anaerobic glycolysis, LD has been detected in developing teeth of rats.<sup>20</sup> In addition to this, LD is also believed to play a major role in pulp necrosis since its activity increases when pulps become necrotic.<sup>21</sup> Loss of cellular activity of this enzyme (release of the enzyme into the surrounding matrix) is considered to result from membrane damage and thus is used frequently as a marker for necrosis. It is important to note that even in the presence of dentin bridge formation, the underlying pulp tissue may remain chronically inflamed and eventually undergo complete necrosis.<sup>18</sup> Though observations for clinical necrosis were not included in this study, the possibility for such activity based on the intense staining of LD cannot be discounted.

Despite the less intense staining that G-6-PD displayed in this study, the possible importance of this enzyme in pulpal injury response mechanisms should not be disregarded. The fact that light staining was present in the control tissues as well as the experimental teeth suggests that the lighter staining intensity may have been a result of technique-sensitive parameters. Reports of histochemical analyses for hard tissues that require prior demineralization procedures are limited. The techniques for these analyses, as well as the prior tissue preparation, may require modifications to obtain better staining reactions.

The significance of the early reduction in SD activity and its continued decrease into the apical third at one month is unknown at this point and requires further investigation. Aerobic metabolic processes that generate cellular energy utilize this particular enzyme. Though odontoblasts that are actively manufacturing dentin during tooth formation have been shown to utilize more oxygen, only partially deficient aerobic metabolism has been identified in odontoblastic metabolism.<sup>22</sup> The results of this study do not provide conclusive evidence that dentin manufacture is occurring in response to pulpal injury in these tissues. While this seems to contradict the speculation regarding the findings for AP, it may be that aerobic glycolysis becomes even more deficient in the manufacture of reparative dentin.

The results of this study are similar to those of earlier studies involving the histochemical enzyme analysis of teeth following formocresol pulpotomies.<sup>11</sup> The distribu-

tion pattern of the enzymes was similar, in that staining was demonstrated in pulps of all teeth, with an unstained zone observed from the point of the amputation wound extending 1–2 mm apically. The most important differences pertain to the time at which the unstained zone was first seen. It was observed immediately in the formocresol-treated teeth but was not apparent in this study until the seven-day observation. The trend for a continued decrease in these enzymes over a period of time in this study was surprising since glutaraldehyde is known for its high cross-linking properties and limited diffusion through tissues.<sup>23</sup> Yet the apparent effect continued through the one-month time period. Further studies with longer observation times as well as other studies to determine the quality and quantity of the enzymes remaining are needed before final conclusions regarding the significance of these findings can be made.

In summary, the enzymes LD, SD, AP, and G-6-PD were demonstrated and localized in radicular pulp tissue following glutaraldehyde pulpotomies. LD and AP stained with the greatest intensity, though all four enzymes were very apparent in the odontoblastic layer. Staining for all enzymes continued to decrease throughout the one-month observation, but enzyme did remain in the apical thirds in all cases. The presence and localization of the enzymes in this study are encouraging observations in an attempt to determine associations between various enzymes and processes involving pulpal injury responses, e.g., inflammation, necrosis, protein synthesis, and dentin bridge formation. Once the mechanisms involved in these processes are better understood, agents that possess these characteristics can be identified.

Dr. Hill is assistant professor, Dr. Seale is professor and chairman, and Mr. Quintero is research assistant, Department of Pediatric Dentistry, and Dr. Guo is assistant professor, Department of Community Health and Preventive Dentistry, all at Baylor College of Dentistry, Dallas, Texas.

1. Jeng HW, Feigal RJ, Messer HH: Comparison of the cytotoxicity of formocresol, formaldehyde, cresol, and glutaraldehyde using human pulp fibroblast cultures. *Pediatr Dent* 9:295–300, 1987.
2. Ranly DM, Horn D, Hubbard GB: Assessment of the systemic distribution and toxicity of glutaraldehyde as a pulpotomy agent. *Pediatr Dent* 11:8–13, 1989.
3. Hill SD, Berry CW, Seale NS, Kaga M: Comparison of antimicrobial and cytotoxic effects of glutaraldehyde and formocresol. *Oral Surg Oral Med Oral Pathol* 71:89–95, 1991.
4. Sun HW, Feigal RJ, Messer HH: Cytotoxicity of glutaraldehyde and formaldehyde in relation to time of exposure and concentration. *Pediatr Dent* 12:303–7, 1990.
5. Feigal RJ, Messer HH: A critical look at glutaraldehyde. *Pediatr Dent* 12:69–71, 1990.
6. Sveen OB, Hawes RR: Differentiation of new odontoblasts and dentine bridge formation in rat molar teeth after tooth grinding. *Arch Oral Biol* 13:1399–1412, 1968.
7. Cunningham KW, Lazzari EP, Ranly DM: The effect of formocresol and glutaraldehyde on certain enzymes in bovine dental pulp. *Oral Surg Oral Med Oral Pathol* 54:100–3, 1982.
8. Ranly DM: A comparative study of the effects of formaldehyde, glutaraldehyde, and dimethylsuberimidate on enzyme activity in the bovine dental pulp. *Acta Odontol Pediatr* 5:5–8, 1984.
9. Gibson W, Fullmer H: Demonstration of 5'-nucleotidase activity

- in decalcified bones and teeth. *J Histochem Cytochem* 14:934-35, 1966.
10. Gibson WA, Fullmer HM: Histochemistry of the periodontal ligament: II. The phosphatases. *Periodontics* 5:226-32, 1967.
  11. Rölling I, Hasselgren G, Tronstad L: Morphologic and enzyme histochemical observations on the pulp of human primary molars 3 to 5 years after formocresol treatment. *Oral Surg Oral Med Oral Pathol* 42:518-28, 1976.
  12. Zach L, Cohen G: Pulpal response to stress: histochemical studies. *J Dent Res* 43:806 (Abst. 148), 1964.
  13. Fullmer HM, Link CC Jr: A demineralization procedure for enzymatic histochemical use: a quantitative succinic dehydrogenase assay. *Stain Technol* 39:387-96 1964.
  14. Kiernan JA: *Histological and Histochemical methods: Theory and Practice*, 1st Ed. Oxford: Pergamon Press, pp 201-43, 1981.
  15. Troyer H: *Principles and Techniques of Histochemistry*, 1st Ed. Boston: Little, Brown, and Co, pp 195-301, 1980.
  16. Matthiessen ME: Enzyme histochemistry of the prenatal development of human deciduous teeth. I. Alkaline phosphatase, acid phosphatase and unspecific AS-Esterase, *Acta Anat* 63:523-44, 1966.
  17. Larmas L, Larmas M: A histochemical study of various dehydrogenases in human tooth ontogeny. *Arch Oral Biol* 21:371-77, 1976.
  18. Seltzer S, Bender IB: *The Dental Pulp*, 3rd Ed. JB Lippincott, pp 3-5; 263-96, 1984.
  19. Zach L, Topal R, Cohen G: Pulpal repair following operative procedures: radiographic demonstration with tritiated thymidine. *Oral Surg Oral Med Oral Pathol* 28:587-97, 1969.
  20. Linde LA, Ljunggren AE: Lactate dehydrogenase isoenzymes in odontoblasts from rat incisors. *Arch Oral Biol* 15:549-50, 1970.
  21. LeBell Y, Larmas M: A quantitative study of lactate and malate dehydrogenase and aspartate transaminase activities in the human dental pulp. *Arch Oral Biol* 23:925-28, 1978.
  22. Fisher AK: Respiratory variations within the normal dental pulp. *J Dent Res* 46:424-28, 1967.
  23. 's-Gravenmade EJ: Some biochemical considerations of fixation in endodontics. *J Endod* 1:233-37, 1975.

### Rebalancing number of generalists vs. specialists is large U.S. medical task

To solve the primary care crisis by rebalancing the number of generalists vs. specialists, physicians will have to accept new reforms and a fundamentally changed system, notes an editorial in the *Journal of the American Medical Association*.

"Simply stated, other developed industrialized countries for many years have practiced medicine with roughly 50 per cent of physicians in primary care and 50 per cent in specialties and subspecialties," writes George Lundberg, MD, editor of JAMA and Richard Lamm, director of the Center for Public Policy and Contemporary Issues, University of Denver, and a former Colorado governor.

"In the United States, however, we train and employ about 32 per cent primary care physicians and about 68 per cent specialists and subspecialists. Health indicators show that comparison countries do as well as or better than the U.S. at providing care at much lower cost, whether cost is measured as the amount spent per capita per year or as a percentage of the gross national product."

They write that there appear to be four general options for fixing the system:

1. Immediately and greatly increase the number of medical school graduates who actually enter generalist fields. While focusing on medical school graduates is important and necessary, this strategy implemented alone will take 20 to 30 years to correct the disparity.
2. Immediately and sharply curtail the number of resident physicians in specialties and subspecialties and increase the number in primary care fields. Reducing the overall number of residency positions and redistribution of slots can and should be done, but attaining the desired, needed balance will still take about 20 years.
3. Do not directly address the oversupply of specialists and subspecialist physicians. Simply allow primary care to be provided by those physicians currently in the fields and those who result from options 1 and 2. Let the remainder of care be given by nurse practitioners, physician's assistants, homeopaths, naprapaths, chiropractors, and other non-allopathic physician providers.
4. Recognize that the only way we can remedy the imbalance in the short run is to create a system of incentives and disincentives that encourages a huge shift of practicing specialists and subspecialists into primary care. Such a system would require a massive program of continuing medical education and retraining for a displaced work force of physicians, most of whom would probably be very unhappy students.

Lundberg and Lamm call on the leaders of medicine to study existing competencies, review the Pew Commission's suggested competencies for the physician of the future (many of which are particularly relevant for the practice of primary care), and establish standard primary care competencies for each field.

"With such massive reforms in mind, it is not an overstatement to call this educational challenge a 'revolution,'" they conclude.