



The investigation of major salivary gland agenesis: A case report

T.A. Hodgson FDS, RCS, MRCP(UK) R. Shah FDS, RCS S.R. Porter MD, PhD, FDS, RCS, FDS, RCSE

Dr. Hodgson is a specialist registrar and professor, and Dr. Porter is a consultant and head of department, Department of Oral Medicine; Dr. Shah is senior house officer, Department of Pediatric Dentistry, Eastman Dental Institute for Oral Health Care Sciences, University College London. Correspond with Dr. Hodgson at T.Hodgson@eastman.ucl.ac.uk

Abstract

Salivary gland agenesis is an extremely uncommon congenital anomaly, which may cause a profound xerostomia in children. The oral sequelae includes dental caries, candidosis, and ascending sialadenitis.

The present report details a child with rampant dental caries secondary to xerostomia. Despite having oral disease for many years, the congenital absence of all the salivary glands failed to be established until early adulthood.

The appropriate investigation and management of the xerostomic child allows a definitive diagnosis to be made and attention focused on the prevention and treatment of resultant oral disease. (Pediatr Dent 23:131-134, 2001)

Agenesis of one or more of the major salivary glands is an extremely uncommon but significant cause of xerostomia in children and young adults.¹ The number of absent salivary glands, and therefore the degree of associated xerostomia, dysarthria and/or dysphagia, varies between individuals.²⁻²⁴ The lack of saliva predisposes to dental caries, periodontal disease, candidosis and acute infective sialadenitis.^{24,25} Rampant dental caries may be the only initial sign of underlying salivary gland disease.^{1,8,14,22,26}

The precise incidence of major salivary gland agenesis is difficult to establish due to the asymptomatic nature of many cases. A recent review of 44 affected patients highlighted a male to female ratio of 2:1.² Familial clustering of salivary gland agenesis has been occasionally reported.³⁻⁷ Salivary gland aplasia may occur in isolation or may be associated with other ectodermal defects, particularly lacrimal apparatus abnormalities.^{5,8-12,15} Associations with hypohidrotic ectodermal dysplasia,^{10,16,18} lacrimo-auriculo-dento-digital and ectodactylo-ectodermal dysplasia-clefting syndromes¹³ have been reported. Therefore, a detailed family history, including direct questions regarding oral, dermatological, ocular and adnexal abnormalities, is mandatory.

The development of non-invasive imaging techniques has facilitated the diagnosis of salivary gland disease. Ultrasonic scanning, computed tomography (CT), and Magnetic Resonance Imaging (MRI) demonstrate the anatomical structure of the major salivary glands and may differentiate agenesis as a cause of xerostomia from other primary causes such as Sjögren's syndrome.^{13,21} Technetium scintigraphy can provide an accurate assessment of gland function and to a lesser extent structure.²²

The present report details a child with rampant dental caries secondary to xerostomia. Despite having oral disease for many years, the congenital absence of all the salivary glands failed to be established until late adolescence, and, therefore, appropriate replacement therapy was not instituted, until this time, to prevent further oral disease.

Case report

In 1988, a 4^{1/2}-year-old Caucasian female was referred to the Department of Pediatric Dentistry of the Eastman Dental Institute for Oral Health Care Sciences for the extraction of several grossly carious deciduous teeth under general anesthesia. A review of her past medical history revealed a congenital obstruction of the right nasolacrimal duct, which had been surgically corrected at the age of 10 months. She was below the 50th percentile for height and weight. The reason for this failure to thrive failed to be established. There was no family history of ectodermal defects.

At the initial consultation her lips were dry, however there was no specific detail recording a subjective xerostomia. Her rampant caries was attributed to poor oral hygiene and a highly cariogenic diet. All the primary teeth were extracted under general anesthesia.

Despite repeated attempts to decrease her intake of refined carbohydrate, caries developed in the first permanent molars and the lower incisors shortly following their eruption. Restorations in these teeth failed due to recurrent caries and they were subsequently extracted. Histopathological examination of the teeth failed to demonstrate the presence of any intrinsic enamel or dentine defect. Despite dietary improvement and the prescription of a fluoride mouthwash, the upper central incisors and upper left lateral incisor developed acute pulpitis. They were extracted and replaced with a partial acrylic denture. The partial denture improved the patient's facial appearance and confidence. Throughout this period she failed to be evaluated for salivary gland disease and replacement therapy was not instituted.

In June 1999, the patient was referred to the Department of Oral Medicine of the Eastman Dental Institute as she complained of a persistently dry mouth. There was no history of ocular or dermatological disease. She was developmentally normal. No positive findings were elicited from an extensive review of the family history. Extra-oral clinical examination at

Received September 14, 2000 Revision Accepted January 13, 2001

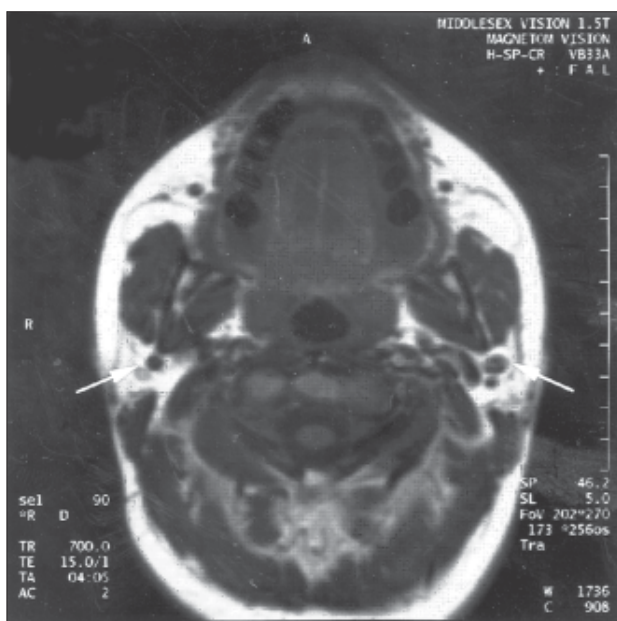


Fig 1. Transverse MRI scan at the level of the ramus of the mandible. The arrows indicate the sites of the absent parotid glands.

this time revealed no hair, nail or epidermal abnormalities. However, there was mild facial acne vulgaris and dry lips. The conjunctivae were well-lubricated and were not inflamed. There were no external salivary gland swellings or cervical lymphadenopathy. The oral mucosa was dry with erythematous candidosis of the palate. The parotid papillae were absent. The absence of salivary tissue in the floor of the mouth could not be confirmed by palpation. She had a generalized hyperplastic gingivitis.

Sialometry revealed no unstimulated salivary flow. Bilateral Schirmer's tests, to evaluate lacrimal function, were normal. There were no abnormalities of red or white blood cells or platelets. Renal and hepatic biochemistry was normal. Autoimmune profile, including antibodies to the extractable nuclear antigens Ro and La, was negative. Ultrasonography revealed the absence of all major salivary glands, this being confirmed by MRI scan (Figs 1 and 2). The lack of functioning tissue was confirmed radiologically by scintiscanning with technetium pertechnetate (Fig 3).

The definitive diagnosis of agenesis of all the major salivary glands, with resultant oral candidosis and rampant dental caries. The patient's symptoms of xerostomia significantly improved following the introduction of a salivary substitute with fluoride (Saliva Orthana®, Nycomed). Definitive restorative treatment was undertaken when an excellent standard of oral hygiene, a non-cariogenic diet, the regular use of a daily fluoride mouthwash, and, as required, saliva substitute resulted in the arrest of carious process.

Discussion

Agenesis of one or more of the salivary glands is an unusual but real cause of rampant caries in children. The individual's complaints depend on the number of absent major salivary glands. Xerostomia is a subjective sensation, which, although common in the elderly and not uncommon in the young, is often of low priority on a list of patient complaints.²⁰ This may

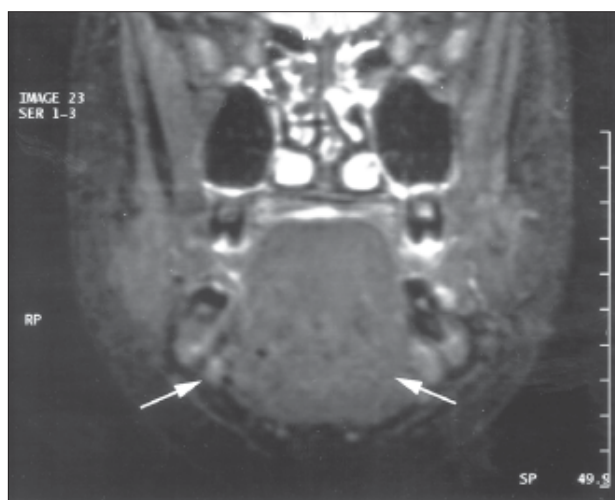


Fig 2. Coronal MRI scan in the region of the first molars. The arrows indicate the sites of the absent submandibular glands.

explain a child's failure to report a dry mouth. Alternatively, she may not have perceived she had xerostomia. In children who never experience a normal salivary flow, there is no reference point for how moist the oral cavity should be. Therefore, even in response to direct questioning, perceptions need to be interpreted with the help of the parents and in the light of a clinical examination.

There are many causes of dry mouth (Table 1). Iatrogenic causes, especially drug related xerostomia, are the most common. It is therefore important to detail the patient's medical and drug history. A review of any familial disease in this group of patients may reveal an underlying genetic cause of the absent major salivary glands.³⁻⁵ Major salivary gland agenesis may be associated with other ectodermal defects, including abnormalities of the lacrimal apparatus, as in this patient.^{9,11,12,14} It has been suggested these defects may arise during the sixth week

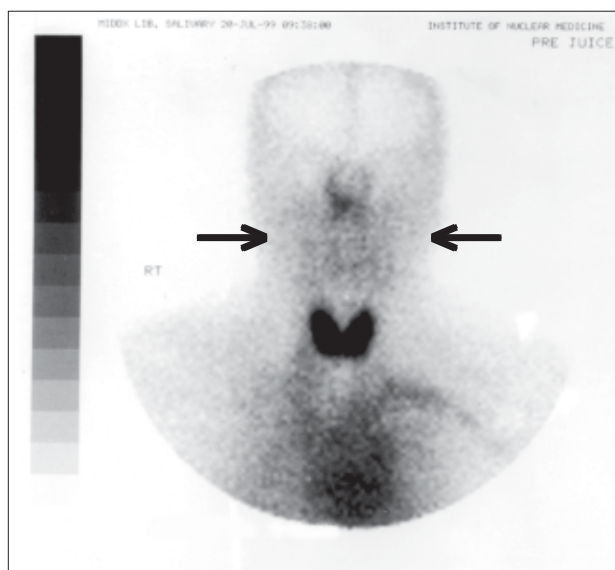


Fig 3. Coronal technetium scan of the head, neck and shoulders showing homogenous uptake in the head and upper neck regions. This indicates the lack of functional salivary tissue in the region of the parotids or submandibular glands. The anatomical position of the submandibular glands is marked with arrows.

Table 1. The Common Causes of Xerostomia

Salivary gland disease	Salivary aplasia*	
	Sjögren's syndrome*	
	Sarcoidosis	
	HIV salivary gland disease*	
	HCV salivary gland disease	
	Chronic sialadenitis	
Iatrogenic	Drug therapy	Anticholinergic drugs Sympathomimetic drugs Cytotoxic drugs Retinoids Protease inhibitors Other
	Irradiation	
	Chronic graft versus host disease	
	Gland excision	
Dehydration		
Psychogenic		

* The most commonly encountered pediatric.

of fetal life whilst these structures are forming.⁵ There were no features of the medical and family histories or clinical examination to suggest other lacrimal apparatus, epidermal, or adnexal disorders suggesting further medical evaluation or genetic analysis.

Agensis of one or more of the salivary glands was initially reported following cadaveric studies. Prior to the development of imaging techniques, the diagnosis of xerostomia associated with salivary gland abnormalities could only be based on clinical examination. This included inspection of the duct orifices, palpation of the sites of the major glands, and salivary flow measurement.^{1,3,14,22,27} The estimation of salivary flow rate (sialometry) is a non-specific but sensitive indicator of salivary gland dysfunction and should be undertaken in any patient complaining of dry mouth. Undertaken over a period of 15 minutes, a normal flow rate (1.5ml/15 minutes) excludes agensis of the major glands or advanced pathology. However, in children, compliance with this test is often poor, making interpretation difficult.

As salivary gland imaging has developed, ultrasonography, sialography, scintigraphy, CT, and MRI have all been used to demonstrate salivary gland disease. Both MRI and CT can generate a reproducible anatomical representation of the salivary glands. However, CT scanning requires the use of ionising radiation and MRI, especially for a young child, may be a claustrophobic, noisy and distressing investigation. Both of these procedures require a compliant patient or the use of intravenous sedation and are therefore not suitable first line imaging.

Radionuclide scanning demonstrates sites of functional salivary gland tissue and may include areas beyond the resolution of MRI and CT. The results of scintiscanning correlate with both salivary flow rate and labial gland histopathological findings in patients with Sjögren's syndrome. However, it requires patient compliance and the injection of a radionuclide. This may once again be overcome by sedating the child

Ultrasound is the initial investigation of choice in the radiological assessment of salivary gland disease. It is non-invasive, rapid, requires minimal patient compliance, and in skilled hands is easy to interpret. In a child with suspected salivary gland agensis, ultrasound provides a safe and rapid diagnostic test. It is non-threatening and is achievable without the requirement for sedation.

In a child with reduced salivary flow of unknown cause and a normal salivary gland ultrasound, further investigation should include autoantibody profile to extractable nuclear antigens Ro and La, the immunological markers of Sjögren's syndrome. Serological investigation for hepatitis C and Human Immunodeficiency Virus infection should be suggested by the history and clinical examination, (but were inappropriate in this adolescent). Labial gland biopsy rarely

may be necessary to exclude a diagnosis of Sjögren's syndrome, enlargement due to Hepatitis C virus infection or Human Immunodeficiency Virus associated salivary gland disease.^{30,31}

Summary

Saliva is integral to the health of the oral tissues.^{14,28} A significant decrease in the caries rate in this case only occurred once the definitive diagnosis was presented to the family and a fluoride containing artificial saliva was introduced.

In children with the congenital absence of only one or two major salivary glands, flow may be stimulated with sugar-free chewing gum. However, the management of children with an absence of all glands remains unsatisfactory. Saliva substitutes require frequent administration and fail to mimic the physiological variation in salivary flow. Compliance is therefore often problematical. As in all patients with xerostomia regular clinical review is essential for this patient's long-term oral health care.

References

1. Gelbier MJ, Winter GB. Absence of salivary glands in children with rampant dental caries: report of seven cases. *Int J Paediatr Dent* 5:253-257, 1995.
2. Matsuda C, Matsui Y, Ohno K, Michi K. Salivary gland aplasia with cleft lip and palate: a case report and review of the literature. *Oral Surg Oral Med Oral Pathol Oral Radiol Endod* 87:594-599, 1999.
3. Wiedemann HR. Salivary gland disorders and heredity. *Am J Med Genet* 60:222-224, 1997.
4. Hughes RD, Syrop HW. A familial study of the agensis of the parotid gland duct. In: Proceedings of the Tenth International Congress of Genetics. Montreal: University of Toronto Press;1959:128.
5. Smith NJD, Smith PB. Congenital absence of major salivary glands. *Br Dent J* 142:259-260, 1977.
6. Wiesenfield D, Iverson ES, Ferguson MM, Hardman FG, McMillan NC, Sagar JA. Familial parotid gland aplasia. *J Oral Med* 40:84-85, 1985.

7. Wiesenfield D, Ferguson MM, Allan CJ, McMillan NC, Scully CM. Bilateral parotid gland aplasia. *Br J Oral Surg* 21:175-178, 1983.
8. Myers MA, Youngberg RA, Bauman JM. Congenital absence of the major salivary glands and impaired lacrimal secretion in a child: case report. *JADA* 125:210-212, 1994.
9. Higashino H, Tsuguo H, Yoshiaki O et al. Congenital absence of lacrimal puncta and of all major salivary glands: case report and literature review. *Clin Pediatr* 26:366-368, 1987.
10. McDonald FG, Mantas J, McEwen CG, Ferguson MM. Salivary gland aplasia: an ectodermal disorder? *J Oral Pathol* 15:115-117, 1986.
11. Sucupira MS, Weinreb JW, Camargo EE, Wagner HN. Salivary gland imaging and radionuclide dacryocystography in agenesis of salivary glands. *Arch Otolaryngol* 109:197-198, 1983.
12. Ferreira AP, Gomez RS, Castro WH, Calixto NS, Silva RA, Aguiar MJ. Congenital absence of lacrimal puncta and salivary glands: a report of a Brazilian family and review. *Am J Med Genet* 94:32-34, 2000.
13. Ostuni PA, Modolo M, Revelli P et al. Lacrimo-auriculo-dento-digital syndrome mimicking primary juvenile Sjögren's Syndrome. *Scand J Rheumatol* 24:55-57, 1995.
14. Gomez Reassurance, Aguiar MJ, Ferreira AP, Castro WH. Congenital absence of the parotid glands and lacrimal puncta. *J Clin Pediatr Dent* 22:247-248, 1998.
15. Wiedemann HR, Drescher J. LADD syndrome: report of new cases and review of the clinical spectrum. *Eur J Pediatr* 144:579-582, 1986.
16. Norgarden H, Johannessen S, Storhaug K, Jensen JL. Salivary gland involvement in hypohidrotic ectodermal dysplasia. *Oral Dis* 4:152-154, 1998.
17. Everett FG, Jump EB, Sutherland WF, Savara BS, Suher T. Anhidrotic ectodermal dysplasia with anodontia: a study of two families. *JADA* 44:173-186, 1952.
18. Garcia-Consuegra L, Gutierrez LJ, Castro JM, Granado JF. Congenital unilateral absence of the submandibular gland. *J Oral Maxillofac Surg* 57:344-346, 1999.
19. Whyte AM, Hayward MWJ. Agenesis of the salivary glands: a report of two cases. *Br J Radiol* 62:1023-1026, 1989.
20. Sreebny LM, Valdin A. Xerostomia. Part 1: Relationship to other oral symptoms and salivary gland hypofunction. *Oral Surg* 66:451-458, 1988.
21. Yoshiura K, Yamada M, Yamada N. Demonstration of congenital absence of the major salivary glands by computed tomography. *Dentomaxillofac Radiol* 2:77-78, 1990.
22. Abdel-Dayem HM. Congenital absence of submaxillary gland detected on 99mTc-pertechnetate thyroid imaging. *Clin Nucl Med* 3:442, 1978.
23. O'Malley AM, Macleod RI, Welbury RR. Congenital aplasia of major salivary glands in a 4-year-old child. *Int J Paed Dent* 3:141-144, 1993.
24. FDI Working Group 10, CORE. Saliva: it's role in health and disease. *Int Dent Journal* 42:291-304, 1992.
25. Weisberger D, Truman Nelson C, Boyle PE. The development of caries in the teeth of albino rats following extirpation of the salivary glands. *Am J Orthod* 26:88, 1940.
26. Austin T, Steggerda FR. Congenital dysfunction of the salivary glands with observations on the physiology of thirst. *Illinois Med J* 69:124-127, 1936.
27. Zaus E, Teuscher GW. Report on three cases of congenital dysfunction of the major salivary glands. *J Dent Res* 19:326, 1940.
28. Poyton HG. The effects of radiation on teeth. *Oral Surg Oral Med Oral Pathol* 26:639-646, 1968.
29. Steggerda FR. Observations on the water intake in an adult man with dysfunctioning salivary glands. *Am J Physiol* 132:517-521, 1940.
30. Schiodt M. Less common oral lesions associated with HIV infection: prevalence and classification. *Oral Dis* 3 Suppl 1:S208-213, 1997.
31. Haddad J, Deny P, Munz-Gotheil C et al. Lymphocytic sialadenitis of Sjögren's syndrome associated with chronic hepatitis C virus liver disease. *Lancet* 339:321-323, 1992.