

Pre-eruptive coronal resorption of permanent teeth: report of three cases and their treatments

Gideon Holan, DMD Eliezer Eidelman, Dr. Odont, MSD Eliyhu Mass, DMD

Introduction

Intracoronary radiolucencies in unerupted permanent teeth had been described previously as caries,¹ caries-like lesions,²⁻⁵ and developmental in origin.^{4,6} More recent reports describe these lesions as resorption of the crown of unerupted permanent teeth⁷⁻⁹ found as an incidental radiographic finding, rarely in more than one tooth in the same patient.^{3,6,9} These often go unnoticed until eruption and then are frequently approached as an aggressive carious lesion. The coronal dentin usually is resorbed. This lesion is reported mainly in first and second permanent molars.^{2,3,5-11} Only one canine,⁷ three first premolars^{4,5,12} and three second premolars have had pre-eruptive coronal resorption reported.^{5,13} Recommended treatment^{3,9,10} has included surgical exposure and restoration of the teeth to avoid progression of the resorptive process, which may weaken the tooth irreversibly. Close observation until tooth eruption is another alternative. This report describes three cases of pre-eruptive coronal resorption and treatment approaches.

Case 1

A 12-year-old boy had a brown discoloration defect at the tip of the erupting mandibular right permanent canine. The primary canine exfoliated a few days earlier.

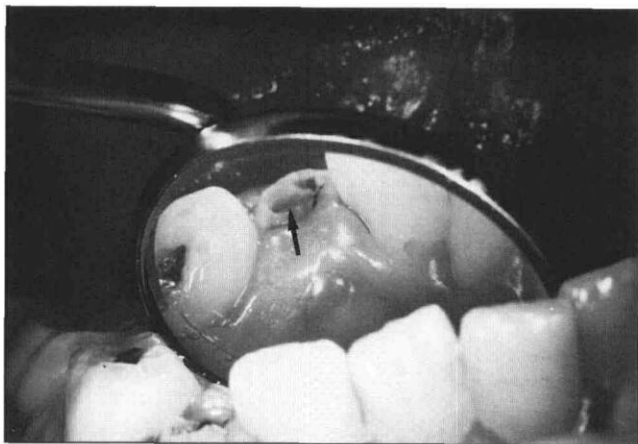


Fig 1. Mirror view demonstrating a large defect on the tip of the cusp (arrow) of the erupting right permanent canine.

Clinical examination revealed a mixed dentition with the homologous left primary mandibular canine very mobile. The affected canine had a large, 1.5-mm-diameter opening at the tip of the cusp (Fig 1). Tactile probing was painful and revealed soft material at the bottom of the lesion. A radiolucent defect involving nearly half the anatomical crown was noted on a panoramic radiograph (Fig 2). The homologous primary canine was close to exfoliation. The remaining dentition was normal.

Following local anesthesia and rubber dam isolation, the opening was enlarged with a bur, and the yellowish-brown soft material that filled the cavity was completely removed. The cavity was cleaned without pulpal exposure, and a calcium hydroxide liner (Dycal®, LD Caulk Co, Milford, DE) was placed at the cavity base. Following acid etching and bonding, the cavity was restored with a posterior composite (P-30™, 3M Company, St Paul, MN). After 6 months a small subgingival marginal defect on the lingual surface at the composite-enamel interface was filled with amalgam. A periapical radiograph of the erupted tooth showed continued root development with no signs of pulp pathology (Fig 3).

Case 2

A radiolucent area was detected in an unerupted second mandibular permanent molar in a panoramic radiographic examination of a 13-year-old, healthy boy. The lesion was located in the coronal dentin under the mesial cusps (Fig 4). The tooth was covered completely by gingival tissue without access from the oral cavity to the embedded crown. The homologous tooth was at the same stage of eruption but was healthy. The crown of the affected molar was surgically exposed under local anesthesia and an attempt was made to find an opening in the enamel. The enamel was carefully perforated through the mesial pit of the occlusal surface using a bur. The exposed cavity contained a yellow-white, mushy substance that was rinsed away with water spray, revealing walls and floor of the cavity covered by soft dentin. Despite the depth of the cavity, no communication with the pulp was found following soft dentin removal. A calcium hydroxide base (Dycal) and quick-setting zinc oxide-eugenol (IRM) were used

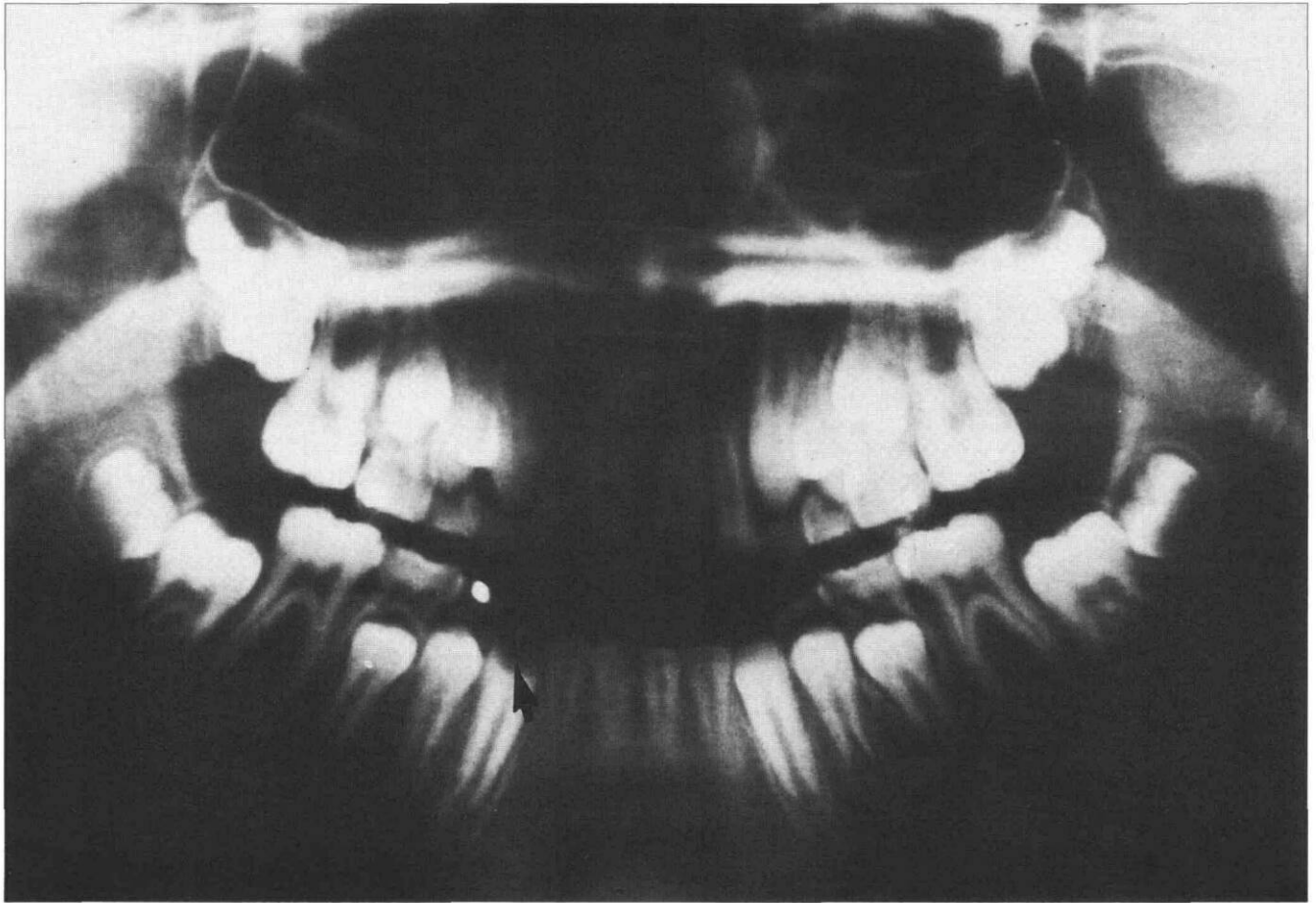

Fig 2. Panoramic radiograph showing a big radiolucent defect (arrow) in the mandibular right permanent canine.

to fill the cavity (Fig 5). Six months after initial treatment the tooth had erupted and was restored without complications. No inconvenience or pain was reported by the patient during the 3 years 9 months' postoperative period. Clinical examination revealed an asymptomatic tooth with healthy surrounding soft tissue. The radiograph showed fully developed roots with closed apices and normal periodontal ligament and adjacent bone (Fig 6).

Case 3

Clinical examination of an 11-year-old girl revealed a recently erupted right mandibular second premolar with a cavity on the distal occlusal surface. The cavity opening was 1 mm wide and 2 mm long and the cavity itself was wider than its opening with a depth of about 2 mm. A probing examination revealed hard cavity walls and floor and yellowish dentin. The patient complained of discomfort from probing.

Bite-wing radiographs exposed 3 months earlier (Fig 7), showed the lower left second primary molar with totally resorbed roots over an erupting premolar. A radiolucent area was observed on the distal part of the succedaneous premolar crown with the pulp horn recessed under the radiolucent area.

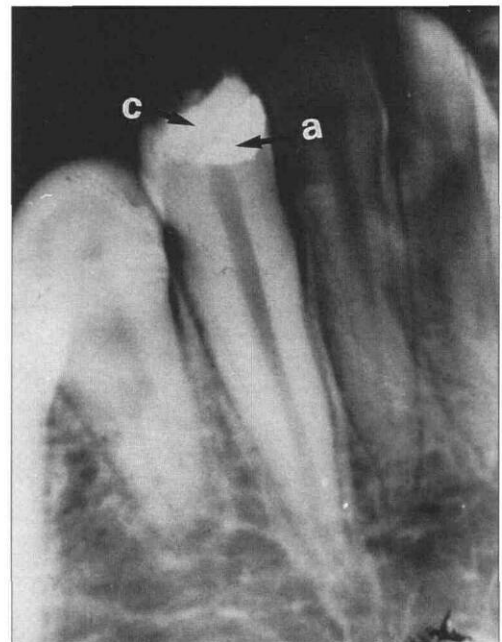


Fig 3. Periapical radiograph showing a combined composite (c) and amalgam (a) restoration of the mandibular right permanent canine. Note continuous root development.

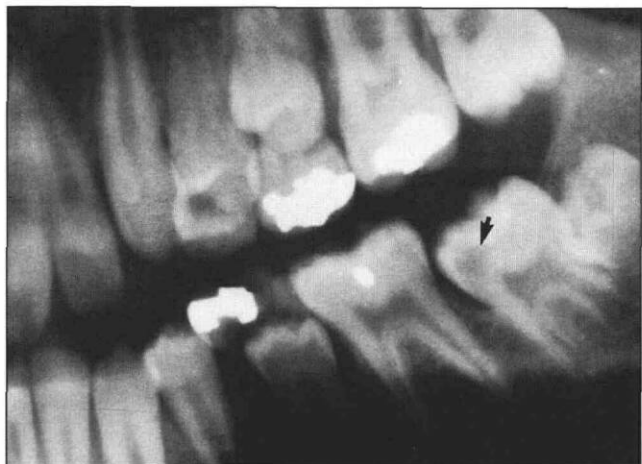


Fig 4. Radiograph showing an unerupted second mandibular permanent molar with a radiolucent area (arrow) located in the coronal dentin, under the mesial cusps.

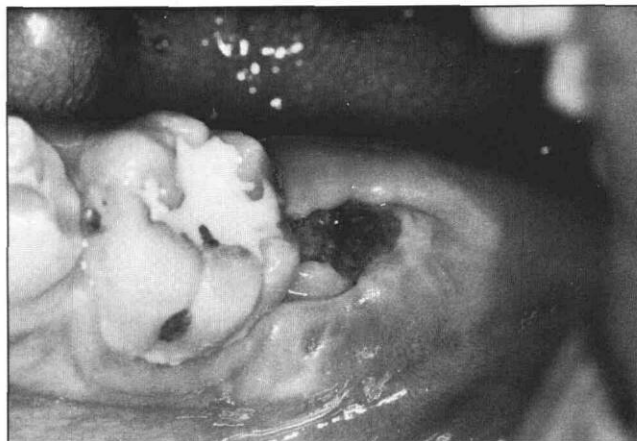


Fig 5. Clinical view of the second permanent molar after surgical exposure and treatment. The dark color of the IRM is due to blood contamination.

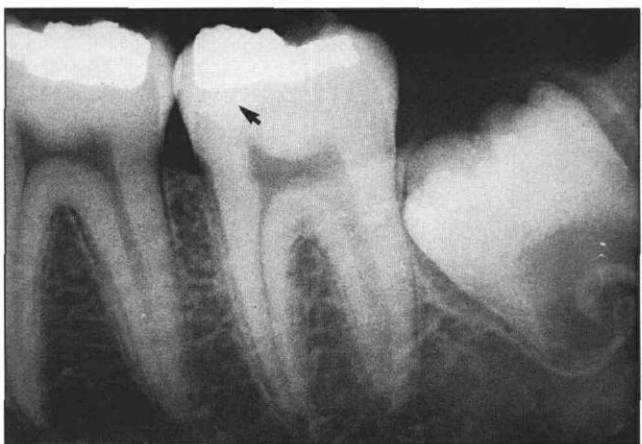

Fig 6. Periapical radiograph of the second mandibular permanent molar 3 years 9 months postoperative. The radiopaque area under the amalgam restoration (arrow) represents the IRM base, filling the coronal defect.

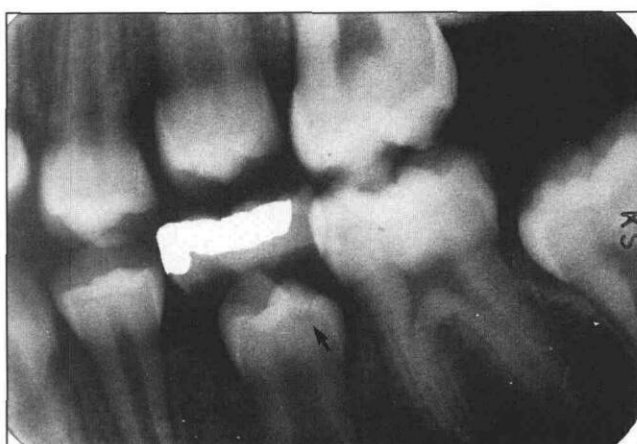


Fig 7. Bite-wing radiograph showing the lower left second premolar shortly before eruption. Notice the radiolucent area (arrow), and the recession of the pulp chamber close to the radiolucency.

The cavity was washed and dried and a replica of the occlusal surface and the cavity was made using Epo-Kwic® (Buehler, Lake Bluff, IL) poured into an elastomeric impression of the tooth [made with Provile® (Bayer, AG Leverkusen, W Germany)]. The impression and the replica were gold coated and examined under a scanning electron microscope (SEM, Model 505, Phillips, Eindhoven, Netherlands) at an accelerating voltage of 300 kV. The occlusal surface presented a deep central groove and a wide distal pit (Fig 8). The pit's margins were relatively smooth, preserving the general outline of the buccal and lingual cusps and the marginal ridge. In a higher magnification, the floor and walls of the cavity presented lacunae-like irregularities.

Following clinical examination, the tooth was isolated with rubber dam and a calcium hydroxide liner (Dycal) was placed. The tooth was restored with P-30

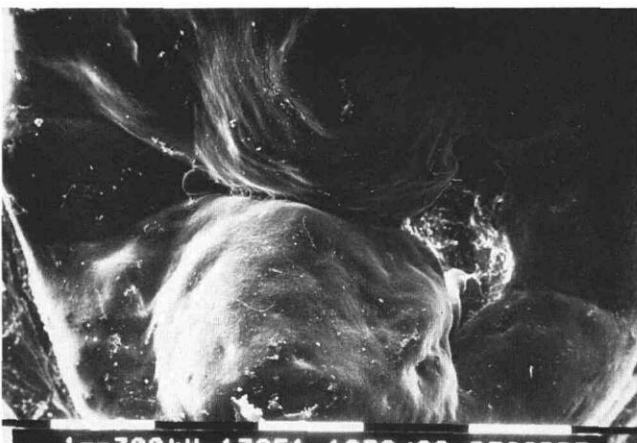


Fig 8. SEM view of the occlusal surface of the right second permanent premolar. Notice the deep central groove and a wide distal pit.

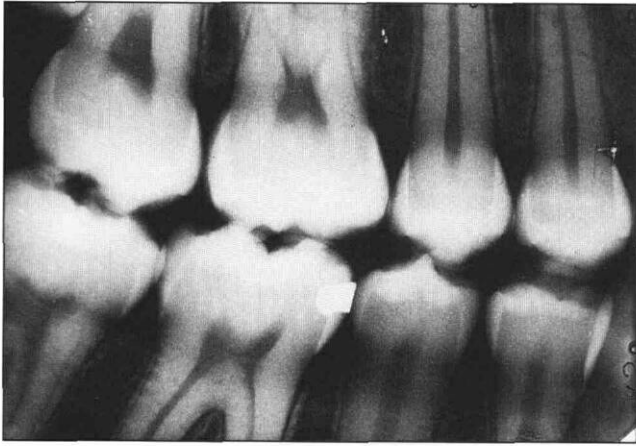


Fig 9. Bite-wing of the right side exposed at the 6 years follow-up examination, showing the right mandibular second premolar without any radiographic pathology.

and the occlusal surface, including the composite restoration, was covered with a pit and fissure sealer (Delton[®], Johnson & Johnson Dental Products Co, East Windsor, NJ). A postoperative radiograph ensured that the cavity was completely filled and that no gap remained between the restoration and the cavity walls and floor. Fig 9 shows a right-side bite-wing radiograph exposed 6 years later. The tooth was found to be clinically asymptomatic without radiographic pathology associated with the affected tooth.

Discussion

These three cases of pre-eruptive coronal resorption occurred in a canine, a premolar, and a second molar. In contrast to a previous report,⁵ the canine case illustrates that this type of resorption does not begin solely in occlusal pits and fissures. Some authors maintain that the reduced enamel epithelium of the unerupted tooth has to be damaged before resorption starts,^{2, 8, 14} and have demonstrated histologically that resorption of enamel and dentin with subsequent invasion of the crown by vascular connective tissue may take place primarily through a defect in the enamel organ. The yellowish, soft material found in the coronal defect of two cases is probably necrotic connective tissue. The eruption to the oral cavity resulted in loss of vascular supply to the resorbing tissue, which caused the necrosis. The small cavity in the premolar (case 3) may be considered a deep and wide pit or invagination. However, the radiograph did not present a radiopaque enamel lining, and the floor and walls of the cavity were yellowish and sensitive to probing. Galil and Gwinnet¹⁵ described the SEM three-dimensional appearance of occlusal pits of 80 unerupted molars, but none resembled the present case.

Previous reports have linked crown resorption with impacted teeth.^{16, 17} Case 1 describes a lesion in a canine with delayed eruption. Our hypothesis is that a pro-

longed pre-eruptive period increases the probability of crown resorption. A review of 38 published cases²⁻¹³ revealed nine instances of probable delayed eruption: eight first permanent molars and one mandibular canine. As demonstrated in Case 1, lesions may be well advanced when teeth erupt and first noticed by the patient or the parents. Canines rarely are observed on routine bite-wing radiographs, but the rare occurrence of pre-eruptive crown resorption does not justify routine periapical radiographs of the canine area. Since pre-eruptive coronal resorption is a progressive lesion, early intervention is essential to prevent crown destruction and pulpal involvement. When treatment is delayed until after eruption, caries may rapidly develop to involve the pulp. These steps should be followed in order to diagnose the lesion as soon as possible and treat the pre-eruptive coronal resorption:

1. Use the largest film size the patient can tolerate for bite-wing radiographs to obtain the widest possible view of unerupted teeth.
2. Check the radiographs for coronal radiolucencies in all unerupted teeth. In cases of uncertainty or insufficient view of the lesion, take an extra periapical radiograph of a suspected tooth. Coronal resorption will appear closer to the occlusal surface of the tooth more frequently than in the middle or cervical part of the crown.
3. Panoramic radiographs should not be used to diagnose coronal resorption lesions, since overlap of other tissues on the teeth may lead to false positive diagnosis. Burnout radiolucencies observed on bite-wings or periapical radiographs may resemble coronal resorption and should not be misdiagnosed as a pathologic lesion.
4. Special attention should be paid to impacted teeth or teeth with delayed eruption.
5. A small lesion far from the pulp observed in a tooth soon before eruption can be followed and treated as soon as the tooth erupts.
6. A tooth with a wide lesion that endangers the pulp, should be surgically exposed and treated soon after diagnosis.
7. The resorbing tissue should be removed, and the cavity walls examined to detect possible pulp exposure.
8. An exposed pulp is not suspected of being infected, thus, a conservative approach can be considered — depending on the size of the exposure.
9. Exposed dentin should be covered with a calcium hydroxide-containing base, to arrest any remaining resorptive activity and encourage apposition of reparative dentin in the pulp. A temporary filling material can be used until tooth eruption allows coronal reconstruction.
10. A posterior-composite can be used to fill small occlusal lesions. A sealant covering the compos-

ite restoration and adjacent, unaffected fissures will result in more esthetic appearance than with amalgam.

11. In cases of large resorption lesions leaving undermined enamel walls, crowning of the teeth should be considered.
12. Successful treatment of coronal resorption lesions do not seem to require any special follow-up examination beyond regular periodic recalls.

Dr. Holan is lecturer, Dr. Eidelman is professor and chairman, department of pediatric dentistry, The Hebrew University — Hadassah Faculty of Dental Medicine Founded by the Alpha-Omega Fraternity, Jerusalem, Israel. Dr. Mass is lecturer, section of pediatric dentistry, The Maurice and Gabriela Goldschleger School of Dental Medicine, Tel Aviv University.

1. Muhler JC: The effect of apical inflammation of the primary teeth on dental caries in the permanent teeth. *ASDC J Dent Child* 24:209-10, 1957.
2. Blackwood HJJ: Resorption of enamel and dentine in the unerupted tooth. *Oral Surg Oral Med Oral Pathol* 11:79-85, 1958.
3. Mueller BH, Litchy GC, Tallerico ME, Bugg JL Jr: "Caries-like" resorption of unerupted permanent teeth. *J Pedod* 4:166-72, 1980.
4. Guinta JL, Kaplan MA: "Caries-like" dentin radiolucency of unerupted permanent tooth from developmental defects: case report. *J Pedod* 5:249-55, 1981.
5. Wood PF, Crozier DS: Radiolucent lesions resembling caries in

the dentin of permanent teeth: a report of sixteen cases. *Austr Dent J* 30:169-73, 1985.

6. Walton JL: Dentin radiolucencies in unerupted teeth. Report of two cases. *ASDC J Dent Child* 47:183-86, 1980.
7. Rankow H, Croll TP, Miller AS: Preeruptive idiopathic coronal resorption of permanent teeth in children. *J Endod* 12:36-39, 1986.
8. Taylor NG, Gravelly JF, Hume WJ: Resorption of the crown of an unerupted molar. *Int J Paediatr Dent* 2:89-92, 1991.
9. Mass E: Radiolucent lesion in the coronal dentin of pre-erupted second permanent molars. *Refu Hashinayim* 8:9-12, 1990.
10. Skaff DM, Dilzel WW: Lesions resembling caries in unerupted teeth. *Oral Surg Oral Med Oral Pathol* 45:643-46, 1978.
11. Grundy GE, Pyle RJ, Adkins KF: Intra-coronal resorption of unerupted molars. *Austr Dent J* 29:175-79, 1984.
12. Wooden EE, Kuftinec MM: Decay of unerupted premolars. *Oral Surg Oral Med Oral Pathol* 38:491-92, 1974.
13. Brooks JK: Detection of intracoronal resorption in an unerupted developing premolar: report of case. *J Am Dent Assoc* 116:857-59, 1988.
14. Ardens J: Enamel. In *Reaction Patterns in Human Teeth*, Mjor IA Ed. Boca Raton, Florida: CRC Press, Inc. 1983, pp 47-62.
15. Galil KA, Gwinnett AJ: Three-dimensional replicas of pit and fissures in human teeth: Scanning Electron Microscopy Study. *Arch Oral Biol* 20:493-95, 1975.
16. Ahlqwist M, Grondahl HG: Prevalence of impacted teeth and associated pathology in middle-aged and older Swedish women. *Community Dent Oral Epidemiol* 19:116-19, 1991.
17. Azaz B, Shteyer A: Resorption of the crown in impacted maxillary canine. A clinical, radiographic and histologic study. *Int J Oral Surg* 7:167-71, 1978.

Common childhood operation frequently inappropriate

About one-quarter of operations to treat ear infection inappropriate

More than one-quarter of surgeries to insert tympanostomy tubes into the ears of children — the most common operation for children — may be inappropriate, according to a study in a recent *Journal of the American Medical Association*.

Tympanostomy tubes are inserted to try to reduce the frequency of recurrent acute otitis media, an inflammation of the middle ear, which is quite common in children and in severe cases can result in hearing loss. About 670,000 tube insertions were performed in the US in 1988.

The study analyzed data on the appropriateness of proposed tympanostomy tube placement collected prospectively by a national utilization review (UR) firm. The sample included 6,611 children aged 22 days to 15.9 years, from 49 states and the District of Columbia, who were insured by three clients of the UR firm. Data were collected from January 1, 1990, through July 31, 1991.

The UR firm convened an expert panel of five pediatricians and four otolaryngologists to develop appropriateness criteria for tympanostomy tube placement. A literature search identified 80 scenarios for tube placement. The panel developed a nine-point scale (1-3 inappropriate, 4-6 equivocal, 7-9 appropriate) and the scenarios were rated using a two-step process.

The authors report on 6,429 cases, those proposed for recurrent acute otitis media, otitis media with effusion (continual production of sticky fluid), or both.

"Making generous clinical assumptions, 41 percent of the proposals for these reasons had appropriate indications, 32 percent had equivocal indications, and 27 percent had inappropriate ones," writes Lawrence C. Kleinman, MD, MPH, from the Division of General Pediatrics, Children's Hospital, Boston, with colleagues.

"If these findings are generalizable, each year several hundred thousand children in the United States may be receiving tympanostomy tubes that offer them no demonstrated advantage over less-invasive therapies and may place them at increased risk for undesirable outcomes.