



# A clinical and research protocol for characterizing patients with hypophosphatasia

Ching-Chun Hu, BDS, PhD David L. King, DDS, PhD

Huw F. Thomas, BDS, LDS, MS, PhD James P. Simmer, DDS, PhD

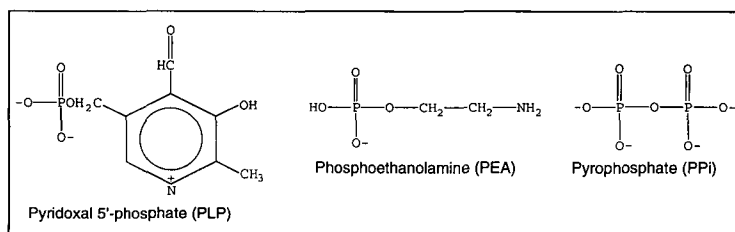
**H**ypophosphatasia is a rare inherited disorder characterized by a wide spectrum of defects in mineralized tissues. The disease is usually inherited as an autosomal recessive trait with a prevalence of approximately 1/100,000 live births.<sup>1</sup> The clinical manifestations are highly variable, ranging from an almost total lack of skeletal formation to the premature loss of the permanent anterior teeth. The scarcity of hypophosphatasia patients and the diversity of their symptoms create special challenges for the clinician, who is unlikely to benefit from broad experience with the disease. These difficulties are compounded by basic science researchers who require standardized and thorough clinical descriptions of affected individuals. It is now possible to characterize the precise mutation(s) at the root of this disorder. To successfully relate the underlying biochemical deficit to its clinical sequelae, it is necessary to document the complete range of physical signs and symptoms of the hypophosphatasia patient. We anticipate that the next 5 to 10 years will see tremendous progress in identifying mutations underlying childhood hypophosphatasia. As scientists go on to clone and characterize these mutations, the pediatric dentist must assume an expanded role in diagnosis, clinical description, tissue collection, and referral to appropriate genetics or research institutions. Our objectives in this report are threefold:

1. To review the basic and clinical science of hypophosphatasia
2. To heighten awareness among pediatric dentists of opportunities to contribute to scientific investigations directed toward characterizing the physiological outcomes of specific mutations underlying hypophosphatasia
3. To propose a strategy for conducting a thorough clinical examination on hypophosphatasia patients whose mutation(s) may subsequently be characterized.

## The underlying genetic defect and its role in hypophosphatasia and laboratory diagnosis

Hypophosphatasia is caused by a defect in the gene-encoding, tissue nonspecific alkaline phosphatase (TNSALP), which is also known as liver/bone/kidney alkaline phosphatase (L/B/K ALP).<sup>2</sup> This enzyme is present in most tissues and in blood serum,<sup>3</sup> with osteoblasts showing the highest level of activity.<sup>4, 5</sup> TNSALP is encoded by a single gene located near the tip of the short arm of chromosome 1.<sup>6, 7</sup> The gene comprises more than 50,000 base pairs of DNA.<sup>8</sup> Its RNA message is 2339 nucleotides in length.<sup>9, 10</sup> The protein, following removal of a 17 amino acid signal peptide, contains 507 amino acids. Hypophosphatasia occurs when a single nucleotide in the coding region for the protein is mutated, causing one of the 507 amino acids to change.

TNSALP functions principally as a phosphomonoesterase.<sup>11, 12</sup> In humans the enzyme cleaves phosphate from three known substrates: pyridoxal-5'-phosphate (PLP), pyrophosphate (PPi), and phosphoethanolamine (PEA). The chemical structures of these substrates are provided in Fig 1. Tissue nonspecific alkaline phosphatase is anchored at its carboxyl-terminus to the plasma membrane by a phosphatidylinositol-glycan moiety.<sup>13</sup> Its tetrameric structure is oriented so that the active sites face the extracellular environment. This protein also is present in serum as a functional dimer



**Fig 1. TNSALP substrates: pyridoxal-5'-phosphate, phosphoethanolamine, and pyrophosphate.**

following cleavage of its membrane attachment by a specific phospholipase.<sup>14</sup> A reduction in serum alkaline phosphatase activity along with elevated serum and urine levels of TNSALP substrates forms the basis for laboratory tests to diagnose hypophosphatasia as well as unaffected carriers of the disease.

Pyridoxal-5'-phosphate (PLP) is a derivative of B<sub>6</sub> that functions as a coenzyme with enzymes that degrade glycogen. It also participates in a wide range of transformations on amino acids including transaminations, decarboxylations, deaminations, racemizations, and aldol cleavages.<sup>15</sup> PLP is unable to traverse the plasma membrane while phosphorylated. TNSALP may act as an ectoenzyme to dephosphorylate PLP, facilitating its entry into cells.<sup>16</sup>

Pyrophosphate (PPi) is a potent inhibitor of biomineralization.<sup>17</sup> TNSALP removes this inhibitor and generates phosphate, a component of calcium hydroxyapatite. Pyrophosphate is a byproduct of many biosynthetic reactions. Cleavage of PPi can drive such a reaction forward by removing a reaction product.<sup>18</sup> An increased concentration of PPi can be detected in the urine<sup>19</sup> and serum<sup>20, 21</sup> of individuals with reduced ALP activity.

Phosphoethanolamine (PEA) is incorporated into membranes as phosphatidylethanolamine (plasmalogen) or phosphatidylethanolamine (cephalin) whose structures are provided in Fig 2.<sup>22</sup> Plasmalogens constitute as much as 10% of the phospholipids of brain and muscle cells. An increased concentration of PEA can be detected in the urine<sup>23-25</sup> and serum<sup>16</sup> of individuals with reduced ALP activity.

The three substrates accumulate in patients with a defective allele of TNSALP, even if they do not present with clinical hypophosphatasia. Elevated levels can be detected in either the serum or urine and provide a method to identify unaffected carriers (heterozygotes), or to confirm a diagnosis of hypophosphatasia when clinical manifestations are present.<sup>26</sup>

PLP, PPi, and PEA are intermediates in diverse, and apparently unrelated, biochemical pathways. The simultaneous loss of capacity to metabolize all three substrates could perturb widespread molecular processes. Sorting out the chain of events that begins with a specific TNSALP catalytic deficit and ends with a clinical outcome such as premature tooth loss, rickets, or cranioostenosis is daunting, but is precisely what must be accomplished to characterize hypophosphatasia at the molecular level. In special circumstances, it may be possible to isolate the downstream effects of a loss of TNSALP function with respect to a single substrate.

An isolated case of pseudohypophosphatasia has been reported.<sup>27</sup> The patient presented with hypophosphatasia-like symptoms in the absence of reduced TNSALP activity. Subsequent investigations determined that the TNSALP of this patient had lost activity for pyridoxal-5'-phosphate only while the activity with other substrates was normal.<sup>28, 29</sup> Therefore hypophosphatasia was the correct diagnosis. The altered amino acid residue may participate in PLP binding but has not been characterized.

Ten-point mutations that lead to perinatal or infantile hypophosphatasia have been reported and are listed in the Table. The most severe forms of hypophosphatasia are recessive and usually are lethal at or

TABLE. MUTATIONS UNDERLYING PERINATAL AND INFANTILE HYPOPHOSPHATASIA

| Onset     | Survival   | TNSALP Mutation           | Substitutions                    | Reference |
|-----------|--|---------------------------|----------------------------------|-----------|
| Perinatal | Died at birth  | G 1177 to A               | Gly 317 to Asp                   | 47        |
| Perinatal | Died at birth  | G 388 to C<br>A 796 to C  | Arg 54 to Pro<br>Gln 190 to Pro  | 38        |
| Infantile | Died at 3 months   | G 711 to A                | Ala 162 to Thr                   | 51        |
| Infantile | Died at 6 months   | C 387 to T<br>A 1057 to C | Arg 54 to Cys<br>Asp 277 to Ala  | 38        |
| Infantile | Died at 8 months   | G 747 to A<br>A 1309 to T | Glu 174 to Lys<br>Asp 361 to Val | 38        |
| Infantile | Pneumonia & rickets at 6 months but near normal at 9 years old | C 274 to T<br>T 1482 to C | Ala 16 to Val<br>Tyr 419 to His  | 38        |

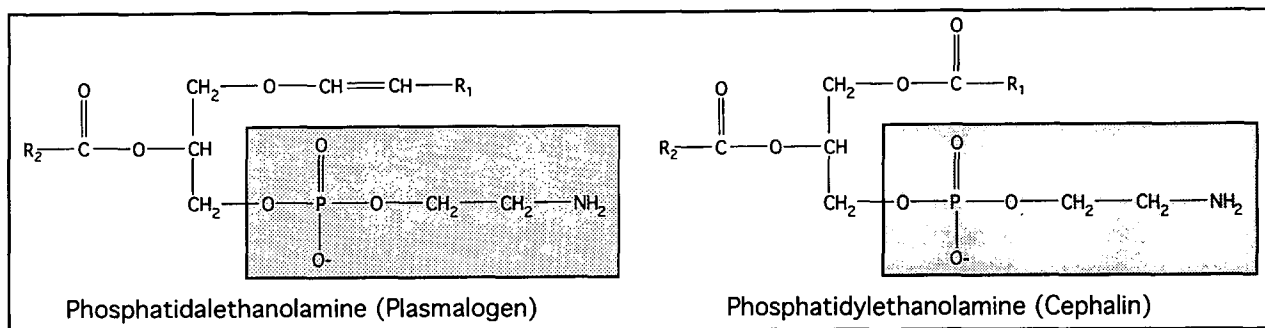


Fig 2. Membrane phospholipids containing phosphoethanolamine. The phosphoethanolamine side chains are boxed.

near birth.<sup>30</sup> While the specific mutations underlying childhood and adult hypophosphatasia are yet to be characterized, they are known to involve the TNSALP gene. The procedures for identifying these mutations are the same as those that have achieved so much progress in characterizing the lethal forms.<sup>51</sup> To achieve similar advances in our understanding of childhood and adult hypophosphatasia, it is necessary for clinicians to bring their patients to the attention of the research community by making a detailed case study of their clinical presentation. In the following sections the signs and symptoms likely to be encountered in a hypophosphatasia patient are discussed along with suggestions for how they can be discerned in a clinical examination.

### The clinical manifestations of TNSALP mutations

Hypophosphatasia is classified according to the age when symptoms first appear (for reviews see<sup>1,31</sup>). Why clinical manifestations segregate according to age of onset is unknown. As a general rule the earlier the appearance of disease the greater the severity. Apparently, diverse point mutations result in heterogeneous amino acid substitutions in the alkaline phosphatase protein. The altered proteins display a spectrum of functional changes that range from complete activity to complete loss of activity. Mutants displaying no activity should affect all alkaline phosphatase-dependent development and result in extreme symptoms that are observed earlier. A minor loss of TNSALP function may affect only processes that are the most alkaline phosphatase dependent, which happen to occur later in development. The four clinical varieties of hypophosphatasia are perinatal, infantile, childhood, and adult onset.<sup>1,31</sup>

Perinatal hypophosphatasia occurs *in utero* with the infant being stillborn or expiring a few days after birth. These individuals exhibit dramatic skeletal deformities.<sup>32-34</sup> Diagnosis is based upon radiographic findings.

Infantile hypophosphatasia has similar skeletal deformities as the lethal form, only far less severe. Symptoms are usually noticed within the first 6 months postnatal. The infant feeds poorly and fails to gain weight,<sup>35</sup> and may present with a flail chest and pneumonia. Eye signs include blue sclerae, harlequin orbits, and pathologic lid retraction.<sup>37</sup> Wide fontanelles and cranial sutures may be observed, or alternatively the fontanelles may be obliterated with subsequent craniostenosis.<sup>37</sup> The disorder is fatal in about half of the cases.<sup>1</sup> Childhood survivors can range from few symptoms<sup>38</sup> to premature fusion of all cranial sutures with prominent scalloping of the inner table of the skull, premature tooth loss, and generalized osteopenia and ossification defects with bowing deformities of the long bones.<sup>39</sup>

Childhood hypophosphatasia is often diagnosed first by the dentist.<sup>40</sup> The child may have rickets, a small stature, and a waddling gate. The periodontal ligament

does not form properly possibly due to a partial or complete lack of cementum formation.<sup>41</sup> Both parents of hypophosphatasia children, although clinically unaffected, are likely to exhibit a raised urinary concentration of pyrophosphate and reduced serum alkaline phosphatase activity.<sup>42</sup> Lundgren et al. published an excellent retrospective study that provides a differential diagnosis for hypophosphatasia, assesses various parameters for their reliability in making a diagnosis, and suggests a diagnostic strategy. Clinical and radiologic deformities of the legs were the most consistent finding, followed by non-leg bony deformities and the premature loss of anterior primary teeth. The exfoliated teeth were fully rooted and displayed cementum aplasia. A histological examination of prematurely mobile primary teeth was recommended as a diagnostic tool.

Adult hypophosphatasia is principally associated with premature loss of the anterior maxillary and mandibular teeth with a history of early primary tooth loss.<sup>43</sup> Enamel hypoplasia often is observed with premature tooth loss due to caries.<sup>44</sup> Premature fusion of cranial sutures may result in proptosis with elevated intracranial pressure and brain damage.<sup>45</sup> The precipitation of calcium pyrophosphate in the joints can lead to chondrocalcinosis or calcium pyrophosphate deposition disease (or pseudogout).<sup>36,46</sup>

### Relating specific TNSALP mutations to their clinical outcomes

#### The role of the research scientist

The research scientist submits a human research protocol, which includes proposed consent forms and a research plan, to an institutional review board. A grant application may be sent to appropriate funding agencies such as the March of Dimes or the National Institute of Health. Upon approval of the protocol, peripheral fibroblasts are grown in culture from a skin biopsy obtained from the hypophosphatasia patient. Total RNA is isolated from these cells and converted to cDNA (or copy DNA) by a process known as reverse transcription (RT). The cDNA complementary to the TNSALP mRNA is then amplified by polymerase chain reaction (PCR), cloned, and characterized by DNA sequencing. This DNA sequence is entered into a computer and compared with the published sequence for human TNSALP. This procedure identifies the precise mutation(s) affecting a proband. The mutation(s) then are linked to the disease state by allele-specific-oligonucleotide (ASO) hybridization analysis of PCR-amplified genomic DNA.<sup>47</sup> In this procedure, the presence or absence of the mutant allele is determined for each member of the pedigree and a statistical analysis is performed to measure the correlation of the mutation with the disease. The genomic DNA for this experiment is obtained from blood samples.

The amino acid sequence of the mutated protein is deduced from the DNA sequence and compared with the unmutated or wild-type sequence. The location of

the amino acid substitution is compared with protein sequences of a wide range of alkaline phosphatase homologues and to the three-dimensional structure of *E. coli* alkaline phosphatase. The level of conservation of the substituted amino acid is discerned as well as its likely effect on protein folding and function. Cultured cells may be induced by recombinant DNA techniques to express the mutant protein to directly assay for changes in enzyme function.

While these investigations provide useful data concerning the biochemical deficit underlying hypophosphatasia, investigating the physiology and pathology of the disorder requires that this information be related back to the clinical symptoms to associate specific mutations with their downstream physical effects. This necessitates a thorough clinical investigation usually conducted by a pediatric dentist and/or a pediatrician.

### **The role of the pediatric dentist**

The clinician is most likely the first member of the research team to meet the patient and make a diagnosis based upon clinical, radiographic, serum and urine analyses. A routine description of the physical defects is made. The quality of this description depends on a prior knowledge of potential symptoms and what tests are needed to identify them. Even if a research effort is not being considered at this point, the examination should be conducted as thoroughly as possible. It may be at a subsequent recall that the decision is made to pursue a research strategy, and prior documentation of findings would enhance the analysis. As medical technology advances, it is plausible that DNA sequence characterization of inborn errors of metabolism will become a routine laboratory procedure.

The patient should be informed that it is technologically feasible to pinpoint the exact mutation at the root of the disease. This requires locating an interested research group. Blood and urine samples are needed from each member of the pedigree, and a punch biopsy is needed from the proband. No promises or allusions should be made to possible personal benefits to patients or their families. The results of an investigation would contribute to a large body of data that may eventually lead to improved diagnosis and treatment.

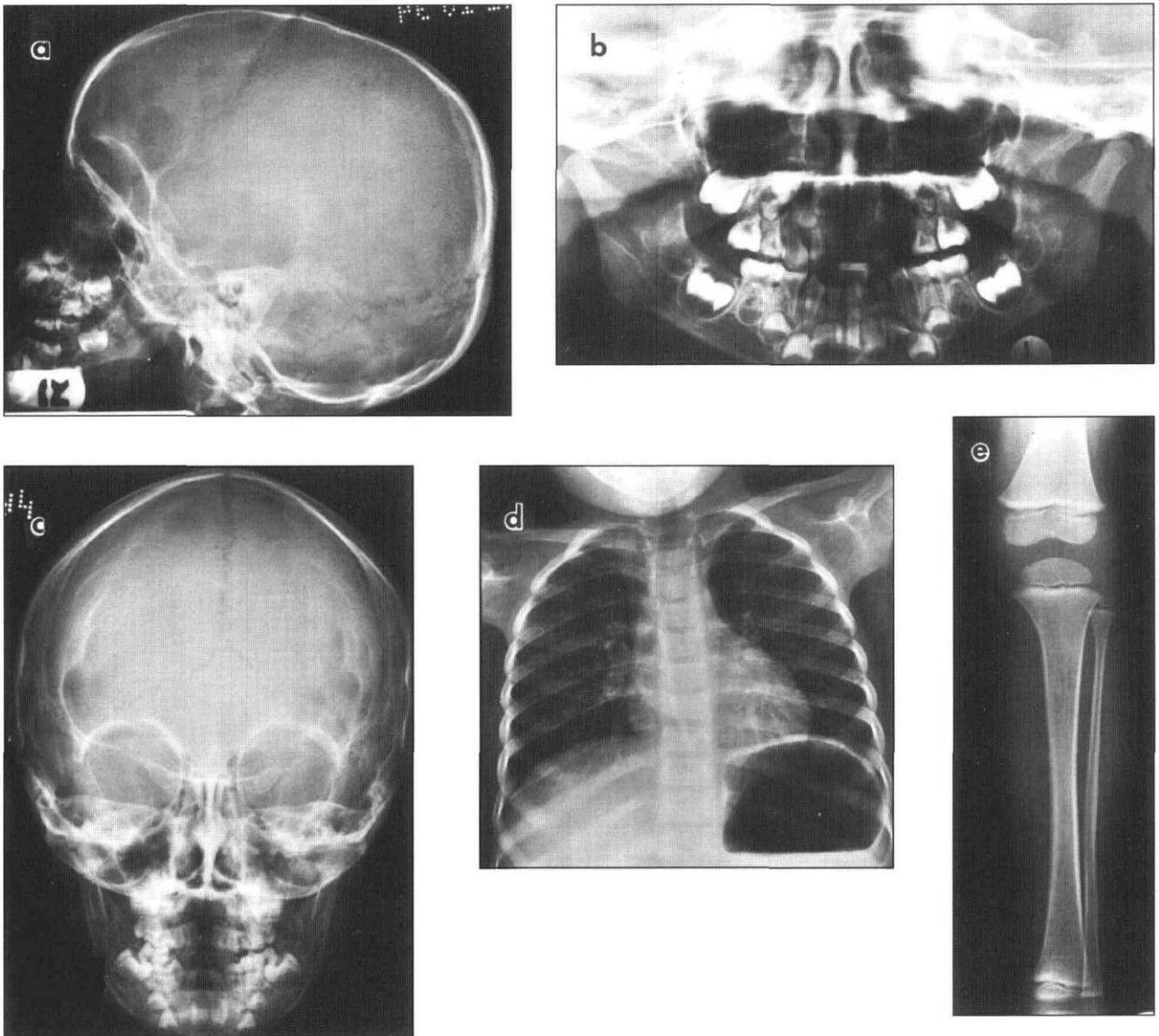
### **A proposed clinical approach to diagnose and characterize hypophosphatasia**

Hypophosphatasia is caused by point mutations in the tissue nonspecific alkaline phosphatase gene. Different amino acid substitutions can variably affect enzyme function, particularly in the case of a multifunctional protein such as TNSALP. Depending upon the impact of the amino acid substitution on enzyme function, the clinical manifestations are of variable severity, which is reflected in the age when symptoms first appear. Physiological processes that depend on TNSALP activity, such as cementum formation in the primary and secondary dentitions, occur at specific times, causing the ages when

symptoms first appear to cluster. This nodal distribution is the basis for the clinical classification. This system can cause confusion however, as patients survive their early symptoms and later present with childhood or adult hypophosphatasia. A simple diagnosis of hypophosphatasia is straightforward and may be adequate under certain circumstances. The most reliable diagnostic findings are clinical and radiologic abnormalities of the legs, phosphoethanolamine in the urine, and reduced serum alkaline phosphatase activity.<sup>40</sup>

For the advancement of science and for future improvements in our understanding and treatment of hypophosphatasia, we propose the following clinical approach be implemented when trying to characterize the genetic lesion underlying hypophosphatasia. This approach is most applicable for childhood hypophosphatasia and can be conducted by a pediatric dentist. A pediatrician may be consulted if the dentist prefers assistance in accomplishing any of the following procedures.

1. Patient and family history. A pedigree is established. Family members with clinical hypophosphatasia are noted along their ages of onset, and the extent of their symptoms. Dental records are obtained to document premature loss of teeth. Blood and urine analyses from each member of the pedigree are used to establish the carrier status of unaffected members.<sup>42</sup> Identifying carriers helps to determine if one or both alleles are likely to be mutated in the patients with hypophosphatasia. This information reveals whether the pattern of inheritance is dominant or recessive, which is used in genetic counseling.
2. Physical examination. The patient's height and weight are recorded. Subsequent measurements establish a chronology that is used for monitoring growth potential. A thorough dental examination with panorex (or periapical radiographs) should look for premature loss of primary teeth, widened pulp chambers, and enamel hypoplasia. The gait and shape of legs are examined. Radiographs of the legs are taken when abnormalities, such as bowing are suspected. The shape of the head is noted with lateral and anterior-posterior cephalograms used to evaluate the size of the fontanelles and ossification of the sutures. Chest x-rays can help document a deviated sternum and malformed vertebra. Examples of these diagnostic radiographs are shown in Fig 3.
3. Tissue collection. Hypermobile, fully rooted teeth are extracted, placed in formalin, and sent for histological examination of the cementum. Under local lidocaine anesthesia, a 4-mm punch biopsy is taken from the upper arm, one-third of the distance from the shoulder to the elbow, on the lateral aspect.<sup>48</sup> The biopsy is placed in ice cold Hank's balanced salt solution (GIBCO/BRL,



**Fig 3. Diagnostic radiographs. Lateral (a), and frontal (c) views of the head, a dental panorex, chest (d) and long bone (e) radiographs are used to detect skeletal deformities associated with hypophosphatasia.**

Gaithersburg, MD), and immediately shipped to the genetics laboratory for cloning of the TNSALP mRNA. (The Hank's solution is a standard laboratory item and can be obtained from the research team.)

4. Blood (10 cc) and urine samples. The clinician orders blood and urine collected from all of the available members of the pedigree. These samples are obtained in the morning prior to the first meal.<sup>49</sup> Serum calcium and alkaline phosphatase activity are determined. Fasting samples are used to avoid measuring the transient intestinal alkaline phosphatase activity that appears after eating. PEA and PLP levels are measured in both urine and serum. The Mayo Clinic (Rochester, MN) can perform these tests. PPi analyses are not offered by commercial laboratories. These results establish the diagnosis and determine if uti-

lization of all three substrates is affected. Blood cells are frozen and stored for the subsequent isolation of genomic DNA.

5. Recall. The patients are recalled annually to document progression of the disease.

### Conclusion

Hypophosphatasia is both rare and heterogeneous. This presents the clinician and scientist with special challenges and opportunities. By relating specific TNSALP defects to thorough clinical descriptions, the physiology of alkaline phosphatase activity will be better understood. Childhood- and adult-onset hypophosphatasia often present a dominant pattern of inheritance while more severe forms are recessive. Simple laboratory tests of unaffected parents can determine carrier status and improve our understanding

of the mode of inheritance of hypophosphatasia. Although the severity of hypophosphatasia in patients from a given pedigree usually is similar, in some instances the phenotype varies.<sup>50</sup> This variability appears to increase in individuals displaying a later onset of symptoms.<sup>36</sup> As the specific mutations in assorted individuals are characterized, the extent of environmental influences can be better assessed. Knowledge of these effects may form the basis for dietary and therapeutic interventions that minimize the clinical course of hypophosphatasia.

Dr. Hu is assistant professor, Dr. King is professor, Dr. Thomas is professor and chairman, and Dr. Simmer is assistant professor, all at the University of Texas School of Dentistry, Health Science Center at San Antonio, Department of Pediatric Dentistry.


1. Fraser D: Hypophosphatasia. *Amer J Med* 22:730-46, 1957.
2. Rasmussen H, Bartter FC: The metabolic basis of inherited disease. New York: McGraw-Hill, 1978, pp 1340-50.
3. Goldstein DJ, Rogers CE, Harris H: Expression of alkaline phosphatase loci in mammalian tissues. *Proc Natl Acad Sci USA* 77:2857-60, 1980.
4. Doty SB, Schofield BH: Enzyme histochemistry of bone and cartilage cells. *Prog Histochem Cytochem* 8:1-38, 1976.
5. Rodan GA, Rodan SB: Expression of the osteoblastic phenotype. Amsterdam: Elsevier Science Publishers, 1983, pp 244-85.
6. Smith M, Weiss MJ, Griffin CA, Murray JC, Buetow KH, Emanuel BS, Henthorn PS, Harris H: Regional assignment of the gene for human liver/bone/kidney alkaline phosphatase to chromosome 1p36.1-p34. *Genomics* 2:139-43, 1988.
7. Greenberg CR, Evans JA, McKendry-Smith S, Redekopp S, Haworth JC, Mulivor R, Chodirker BN: Infantile hypophosphatasia: localization within chromosome region 1p36.1-34 and prenatal diagnosis using linked DNA markers. *Am J Hum Genet* 46:286-92, 1990.
8. Weiss MJ, Ray K, Henthorn PS, Lamb B, Kadesch T, Harris H: Structure of the human liver/bone/kidney alkaline phosphatase gene. *J Biol Chem* 263:12002-10, 1988.
9. Weiss MJ, Henthorn PS, Lafferty MA, Slaughter C, Raducha M, Harris H: Isolation and characterization of a cDNA encoding a human liver/bone/kidney-type alkaline phosphatase. *Proc Natl Acad Sci USA* 83:7182-86, 1986.
10. Kishi F, Matsuura S, Kajii T: Nucleotide sequence of the human liver-type alkaline phosphatase cDNA. *Nucleic Acids Res.* 17:2129, 1989.
11. Coleman JE: Structure and mechanism of alkaline phosphatase. *Annu Rev Biophys Biomol Struct* 21:441-83, 1992.
12. Kim EE, Wyckoff HW: Reaction mechanism of alkaline phosphatase based on crystal structures. *J Mol Biol* 218:449-64, 1991.
13. Jemmerson R, Low MG: Phosphatidylinositol anchor of HeLa cell alkaline phosphatase. *Biochemistry* 26:5703-9, 1987.
14. Hawrylak K, Stinson RA: The solubilisation of tetrameric alkaline phosphatase from human liver and its conversion into various forms by phosphatidylinositol phospholipase C or proteolysis. *J Biol Chem* 263:14368-373, 1988.
15. Stryer L: *Biochemistry*, 3rd Ed. New York: WH Freeman and Co, 1988, pp 452, 496-99.
16. Whyte MP, Mahuren JD, Vrabel LA, Coburn SP: Markedly increased circulating pyridoxal-5'-phosphate levels in hypophosphatasia. Alkaline phosphatase acts in vitamin B6 metabolism. *J Clin Invest* 76:752-56, 1985.
17. Fleish H, Neuman WF: Mechanism of calcification. Role of collagen, polyphosphates and phosphatase. *Am J Physiol* 200:1296-1300, 1961.
18. Stryer L: *Biochemistry*, 3rd Ed. New York: WH Freeman and Co, 1988, pp 456.
19. Russell RG: Excretion of inorganic pyrophosphate in hypophosphatasia. *Lancet* 2:461-64, 1965.
20. Russell RG, Bisaz S, Donath A, Morgan DB, Fleish H: Inorganic pyrophosphate in plasma in normal persons and in patients with hypophosphatasia, osteogenesis imperfecta, and other disorders of bone. *J Clin Invest* 50:961-69, 1971.
21. Macfarlane JD, Harinck HI, Bijvoet OL: Hyperphosphataemia in hypophosphatasia. *Neth J Med* 28:541-42, 1985.
22. Martin Jr DW, Mayes PA, Rodwell VW, Granner DK: *Harper's Review of Biochemistry*. Los Altos, CA: Lange Medical Publications, 1985, pp 198-99.
23. McCance RA, Morrison AB, Dent CE: The excretion of phosphoethanolamine and hypophosphatasia: preliminary communication. *Lancet* 268:131, 1955.
24. Fraser D, Yendt ER, Christie FHE: Metabolic abnormalities in hypophosphatasia. *Lancet* 286, 1955.
25. Rasmussen K: Phosphorylethanolamine and hypophosphatasia. *Danish Med Bull* 15:1-112, 1968. (Suppl 2)
26. Sorensen SA, Flodgaard H, Sorensen E: Serum alkaline phosphatase, serum pyrophosphatase, phosphorylethanolamine and inorganic pyrophosphate in plasma and urine. A genetic and clinical study of hypophosphatasia. *Monogr Hum Genet* 10:66-69, 1978.
27. Sriver CR, Cameron D: Pseudohypophosphatasia. *N Engl J Med* 281:604-6, 1969.
28. Cole DEC, Coburn SP, Salisbury SR, Whyte MP: Pseudohypophosphatasia revisited: Further biochemical characterisation sixteen years later. *Am J Hum Genet* 37:016;12.1, 1985.
29. Cole DE, Salisbury SR, Stinson RA, Coburn SP, Ryan LM, Whyte MP: Increased serum pyridoxal-5'-phosphate in pseudohypophosphatasia [letter]. *N Engl J Med* 314:992-93, 1986.
30. Caswell AM, Whyte MP, Russell RG: Hypophosphatasia and the extracellular metabolism of inorganic pyrophosphate: clinical and laboratory aspects. *Crit Rev Clin Lab Sci* 28:175-232, 1991.
31. Chapple IL: Hypophosphatasia: dental aspects and mode of inheritance. *J Clin Periodontol* 20:615-22, 1993.
32. Koslowski K, Sutcliffe J, Barylak A, Harrington G, Kemperdick H, Nolye K, Rheinwein H, Thomas PS, Uniecka W: Hypophosphatasia: review of 24 cases. *Pediatric Radiology* 5:103-17, 1976.
33. Ornoy A, Adomian GE, Rimoin DL: Histologic and ultrastructural studies on the mineralization process in hypophosphatasia. *Am J Med Genet* 22:743-58, 1985.
34. Shohat M, Rimoin DL, Gruber HE, Lachman RS: Perinatal lethal hypophosphatasia; clinical, radiologic and morphologic findings. *Pediatr Radiol* 21:421-27, 1991.
35. Whyte MP, Valdes R Jr, Ryan LM, McAlister WH: Infantile hypophosphatasia: enzyme replacement therapy by intravenous infusion of alkaline phosphatase-rich plasma from patients with Paget bone disease. *J Pediatr* 101:379-86, 1982.
36. Whyte MP, Murphy WA, Fallon MD: Adult hypophosphatasia with chondrocalcinosis and arthropathy. Variable penetrance of hypophosphatasemia in a large Oklahoma kindred. *Am J Med* 72:631-41, 1982.
37. Brenner RL, Smith JL, Cleveland WW, Bejar RL, Lockhart W Jr: Eye signs of hypophosphatasia. *Arch Ophthalmol* 81:614-27, 1969.
38. Henthorn PS, Raducha M, Fedde KN, Lafferty MA, Whyte MP: Different missense mutations at the tissue-nonspecific alkaline phosphatase gene locus in autosomal recessively inherited forms of mild and severe hypophosphatasia. *Proc Natl Acad Sci USA* 89:9924-28, 1992.
39. Moore CA, Ward JC, Rivas ML, Magill HL, Whyte MP: Infantile hypophosphatasia: autosomal recessive transmission

- to two related sibships. *Am J Med Genet* 36:15–22, 1990.
40. Lundgren T, Westphal O, Bolme P, Modeer T, Noren JG: Retrospective study of children with hypophosphatasia with reference to dental changes. *Scand J Dent Res* 99:357–64, 1991.
  41. Macfarlane JD, Swart JG: Dental aspects of hypophosphatasia: a case report, family study, and literature review. *Oral Surg Oral Med Oral Pathol* 67:521–26, 1989.
  42. Macfarlane JD, Poorthuis BJ, Mulivor RA, Caswell AM: Raised urinary excretion of inorganic pyrophosphate in asymptomatic members of a hypophosphatasia kindred. *Clin Chim Acta* 202:141–48, 1991.
  43. Wendling D, Cassou M, Guidet M: Hypophosphatasia in adults. Apropos of 2 cases. *Rev Rhum Mal Osteoartic* 52:43–50, 1985. [French with English abstract]
  44. Sorensen E, Flodgaard H: Adult hypophosphatasia. *Acta Medica Scandinavia* 197:357–60, 1975.
  45. Terec TM, Klein L: Hypophosphatasia: Clinical and metabolic studies. *J Pediat* 72:41–50, 1968.
  46. Jones AC, Chuck AJ, Arie EA, Green DJ, Doherty M: Diseases associated with calcium pyrophosphate deposition disease. *Semin Arthritis Rheum* 22:188–202, 1992.
  47. Greenberg CR, Taylor CL, Haworth JC, Seargeant LE, Philipps S, Triggs-Raine B, Chodirker BN: A homoallelic Gly317→Asp mutation in ALPL causes the perinatal (lethal form of hypophosphatasia in Canadian Mennonites. *Genomics* 17:215–17, 1993.
  48. Sly WS, Grubb J: Isolation of fibroblasts from patients. *Methods Enzymol* 58:444–50, 1979.
  49. Macfarlane JD, Poorthuis BJ, van de Kamp JJ, Russell RG, Caswell AM: Hypophosphatasia: biochemical screening of a Dutch kindred and evidence that urinary excretion of inorganic pyrophosphate is a marker for the disease. *Clin Chem* 34:1937–41, 1988.
  50. Macfarlane JD, Kroon HM, van der Harten JJ: Phenotypically dissimilar hypophosphatasia in two sibships. *Am J Med Genet* 42:117–21, 1992.
  51. Weiss MJ, Cole DE, Ray K, Whyte MP, Lafferty MA, Mulivor RA, Harris H: A missense mutation in the human liver/bone/kidney alkaline phosphatase gene causing a lethal form of hypophosphatasia. *Proc Natl Acad Sci USA* 85:7666–69, 1988.

## Future Annual Sessions of the American Academy of Pediatric Dentistry

### 49th Annual Session

May 24–28, 1996

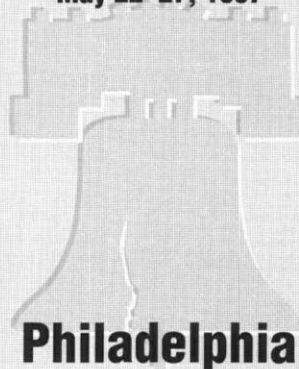


## Chicago

Chicago Marriott Hotel

### 50th Annual Session

May 22–27, 1997




## Philadelphia

Philadelphia Marriott Hotel

### 51st Annual Session

May 21–26, 1998




## San Diego

San Diego Marriott Hotel & Marina

### 52nd Annual Session

May 27–June 1, 1999



## Toronto

Sheraton Centre of Toronto Hotel & Towers