



Clinical aid in placing brass wires to treat ectopically erupting permanent first molars

Wen-Jeng Huang, DDS Noel K. Childers, DDS, MS, PhD

Ectopic eruption of the permanent first molar is a local eruption disturbance in the developing permanent dentition. This abnormal eruption pattern is most commonly seen in the maxillary arch.¹ The abnormal mesioangular eruption path of the maxillary first molar causes resorption of the distal root of the adjacent primary second molar. Progression of ectopic eruption may cause impacted permanent first molars, possible pulpal infection, and / or premature loss of the primary second molar.² Early loss of the primary second molar may result in space loss and impaction of the second premolar as well as mesial tipping of the permanent first molar.

Ectopically erupting permanent maxillary first molars occur in about 3% of the population.³ A higher prevalence of this anomaly has been reported in siblings (19.8%)⁴ and in children with cleft lip and palate (25%).⁵ Sixty-six percent of these cases are reported to be reversible by age 7 (jump type).^{3, 6} The remaining cases are irreversible (hold type) and require treatment.^{3, 6}

Various treatment techniques have been reported to correct ectopically erupting permanent first molars. In cases with minimal impaction, the first molars can be deimpacted with interproximal wedging methods (e.g., brass wire technique,⁷ spring-type deimpactor,^{8, 9} or elastic separators¹⁰). When the impaction is severe, distal tipping techniques are required. These methods include removable appliance with finger spring,¹¹ Humphrey appliance,¹² unilateral or bilateral reverse band and loop with a distal spur,^{13, 14} sectional wire with open coil spring,¹⁵ and Cetlin appliance/headgear.¹⁶

Before elastic separators were introduced, brass wire had frequently been used to separate posterior teeth, allowing molar band seating. It is also a convenient and economic method for correcting minimally impacted ectopically erupting permanent first molars. However, its use is limited because the softness of brass wire makes it difficult to pass between the primary second molars and impacted permanent first molars. When the permanent first molars are more subgingival, brass wire may become distorted and locked by the irregular surface of the resorbing distal root of the pri-

mary molars during placement. Repeated trials to insert the distorted brass wire can cause soft tissue damage. Crossman proposed making a soft tissue incision to allow brass wire to pass apically to the contact.¹⁷ This article introduces a clinical aid in placing brass wires in cases of ectopically erupting maxillary permanent first molars.

TABLE. MATERIALS OF THE NEW BRASS WIRE TECHNIQUE

1. Brass wire (0.020, 0.025 gauge, Rocky Mountain Co)
2. Angiocatheter (0.020 to 0.022 gauge, Angiocath™)
3. Arch-forming plier
4. Ligature wire cutter
5. Mosquito hemostat

Treatment techniques

The materials needed for the technique are listed in the Table. An angiocatheter (Angiocath™, Becton Dickinson Vascular Access, Sandy, UT) is smoothly precurved into a half circle (diameter equal to buccal-lingual width of primary second molar) with arch forming pliers (or by hand) (Fig 1). A 0.020-gauge brass wire prepared with a 45° cut on one end prevents distortion of the brass wire

while passing it through the needle or angiocatheter. The sharp point must be rounded to allow the brass wire to pass through the needle. The prepared brass wire is checked for free passage through the precurved needle prior to clinical use. When checking the angiocatheter, the inner catheter (needle) must be removed before inserting brass wire through the outer catheter (Fig 2).

The involved tissues can be prepared with antiseptic solution (e.g., povidone-iodine or chlorhexidine) to prevent postoperative bacteremia and infection, although the risk is low in healthy patients.¹⁸ The area is

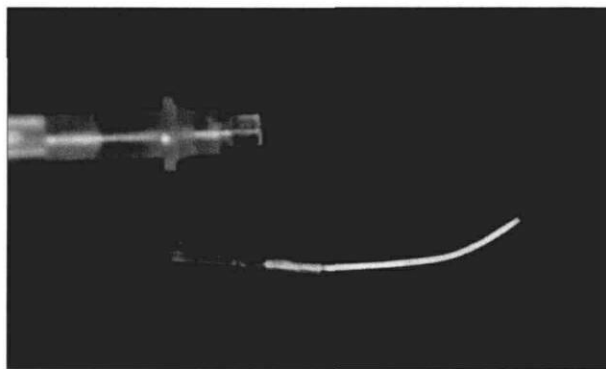


Fig 1. Precurved angiocatheter (0.022 gauge).




Fig 2. Previsit trial; insert the brass wire through the outer catheter after the inner catheter is removed.

then anesthetized. The precurved needle (or angiocatheter) is inserted carefully from the buccal side of contact between the permanent and primary molars to the lingual side (Fig 3). When using an angiocatheter, the outer catheter must be held from the lingual side before the inner catheter is withdrawn. The prepared brass wire is slid through the needle or outer catheter. The brass wire must be held from the lingual side while the needle or outer catheter is removed. The brass wire is then tightened around the contact area with a hemostat. The wire should be tightened at 7-day intervals until the permanent molars are deimpacted. For bilateral cases the needle or angiocatheter can be reused with the same patient at the same visit.

Discussion

The technique presented has several advantages. 1) the direct approach eliminates the need for more involved and costly impression and laboratory procedures; 2) using an angiocatheter as a clinical aid helps to diminish the difficulty in inserting brass wires; 3) the brass wires and angiocatheter can be prepared without difficulty.

Two important aids for this technique are: 1) a 45° end cut on brass wire will ease passage through the needle or plastic outer catheter and 2) precurving the needle allows passage through to the lingual surface of the embrasure without penetrating the palatal interdental papilla. An angiocatheter is relatively inexpensive (less than \$1). The size and ease of adjustment of the angiocatheter (0.022 gauge) make it best suited however, a large-sized needle (0.018 gauge) also may be used in this technique.

Dr. Huang is a resident and Dr. Childers is associate professor, pediatric dentistry, UAB School of Dentistry, University Station, Birmingham, Alabama.

1. Duncan WK, Ashrafi MH: Ectopic eruption of the mandibular first permanent molar. *J Am Dent Assoc* 102:651-54, 1981.

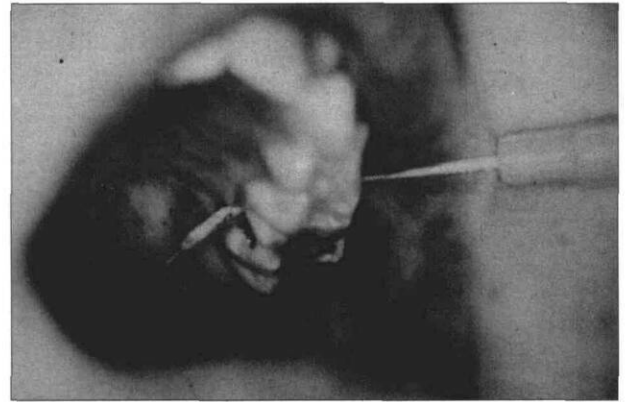


Fig 3. Patient with precurved angiocatheter passed through the contact between primary and permanent molars; a brass wire was inserted through the catheter.

2. Starkey P: The etiology and prevalence of ectopic eruption of the maxillary first permanent molar. *ASDC J Dent Child* 28:327-30, 1961.
3. Young DH: Ectopic eruption of first permanent molar. *ASDC J Dent Child* 24:153-62, 1957.
4. Kuroi J, Bjerklin K: Ectopic eruption of maxillary first permanent molars: familial tendencies. *ASDC J Dent Child* 49:35-38, 1982.
5. Carr GE, Mink JR: Ectopic eruption of the first permanent maxillary molar in cleft lip and cleft palate children. *ASDC J Dent Child* 32:179-88, 1965.
6. Kimmel NA, Gellin ME, Bohannon NM, Kaplan AL: Ectopic eruption of maxillary first permanent molars in different areas of the United States. *ASDC J Dent Child* 49:294-99, 1982.
7. Levitas TC: A simple technique for correcting an ectopically erupting first permanent molar. *ASDC J Dent Child* 31:16-18, 1962.
8. Venn RJ: Ectopic eruption of permanent first molars: a clinical technique. *J Pedod* 10:81-88, 1985.
9. McDonald RE, Avery DR: *Dentistry for the Child and Adolescent*. 6th ed. St Louis: CV Mosby Co, 1994, pp 755-62.
10. Glenn RW: Ectopic eruption of permanent first molars: a simple interceptive method of treatment. *J Nebr Dent Assoc* 55:11-14, 1978.
11. Grimm SE III: Treatment of ectopically erupting molars. *J Clin Orthod* 22:512-13, 1988.
12. Humphrey WP: Simple technique for correcting an ectopically erupting first permanent molar. *ASDC J Dent Child* 29:176-78, 1962.
13. Croll TP: Correction of first permanent molars: ectopic eruption. *Quintessence Int* 15:1239-46, 1984.
14. Weinberger SJ: Correction of bilateral ectopic eruption of first permanent molars using a fixed appliance. *Pediatr Dent* 14:382-83, 1992.
15. Rust RD, Carr GE: Management of ectopically erupting first permanent molars. *ASDC J Dent Child* 52:55-56, 1985.
16. Cetlin NM, Ten Hoeve A: Nonextraction treatment. *J Clin Orthod* 17:396-413, 1983.
17. Crossman MH: Ectopic eruption: first molar impaction in the mixed dentition. *Dental Digest* 76:349-53, 1970.
18. Rahn R: Review presentation on povidone-iodine antiseptics in the oral cavity. *Postgrad Med J* 69(suppl 3):S4-S9, 1993.