

## Facial nerve paralysis: report of two cases of Bell's palsy

Martha Ann Keels, DDS Linwood M. Long, Jr., DDS, MS  
William F. Vann, Jr., DMD, MS, PhD

### Abstract

*The cases of an 11-year-old white male and an 8-year-old black male with facial paralysis are presented. Included are descriptions of diagnosis, clinical course, treatment, prognosis, and recommendations for future cases.*

**F**acial nerve paralysis is an important cause of morbidity in children. Its presentation can be frightening for both the child and parents. The most common cause of facial nerve paralysis in children is Bell's palsy.<sup>1</sup> Bell's palsy is the accepted term to describe unilateral, peripheral facial nerve paralysis which is idiopathic with acute onset.<sup>2</sup>

Sometimes facial nerve paralysis is a sign of an underlying disease process. Because the facial nerve courses through intracranial, intratemporal, and extracranial regions, determination of the etiology of facial nerve paralysis is complicated (Olsen 1984). May et al. (1981) evaluated 170 children over a 17-year-period (1963-80) and found that Bell's palsy accounted for 42% of the facial nerve paralyses. The remaining causes in children were trauma (21%), otitis media (13%), syndromes (13%), congenital (8%), and tumors (2%) (May et al. 1981). Depending on the cause, the prognosis of facial nerve paralysis may be spontaneous regression or rapid morbidity and fatality. It should not be assumed that a child presenting with facial nerve paralysis has Bell's palsy because more serious disorders can cause similar signs and symptoms (May et al. 1981).

The purpose of this case report is to present 2 children with facial nerve paralysis. The diagnosis and course of each were very different and these cases underscore the important role of the pediatric dentist in recognition and referral of such cases.

<sup>1</sup> Adour 1982; May et al. 1981; Olsen 1984.

<sup>2</sup> Olsen 1984; Blattner 1969; McGovern and Estevez 1983; Peitersen 1982.

### Review of Facial Nerve Anatomy

The facial (7th cranial) nerve has parasympathetic, motor, and sensory nuclei in the pons, a part of the brain stem located in the posterior cranial fossa. The fibers from the motor nucleus pass below the floor of the 4th ventricle and continue around the nucleus of the abducens (6th cranial) nerve to combine with parasympathetic and sensory fibers to form a common nerve trunk. The nerve trunk exits the brain and continues its lateral course through the facial canal. Where the canal makes an acute bend toward the middle ear cavity, the geniculate ganglion is located. At the level of the geniculate ganglion, the greater superficial petrosal nerve arises and supplies parasympathetic fibers to the lacrimal gland and mucous membrane of the nose and mouth (Fig 1).<sup>3</sup>

Distal to the geniculate ganglion, the facial nerve gives rise to 2 branches. The first contains the motor nerve to the stapedius muscle, which serves to dampen the oscillations of the ear ossicles. The second is the chorda tympani nerve, which contains sensory fibers for taste from the anterior 2/3 of the tongue. The chorda tympani nerve also joins with the lingual nerve and provides parasympathetic innervation to the submandibular and sublingual glands.

The facial nerve exits the temporal bone through the stylomastoid foramen and subdivides into its terminal branches, which supply the motor innervation to the muscles of facial expression.

### Central Versus Peripheral Lesions of the Facial Nerve

The facial nerve primarily innervates the muscles of facial expression. There are 2 types of paralysis affecting the motor function of the facial nerve and

<sup>3</sup> Olsen 1984; Alford et al. 1973; Carpenter 1978; Montgomery 1981.

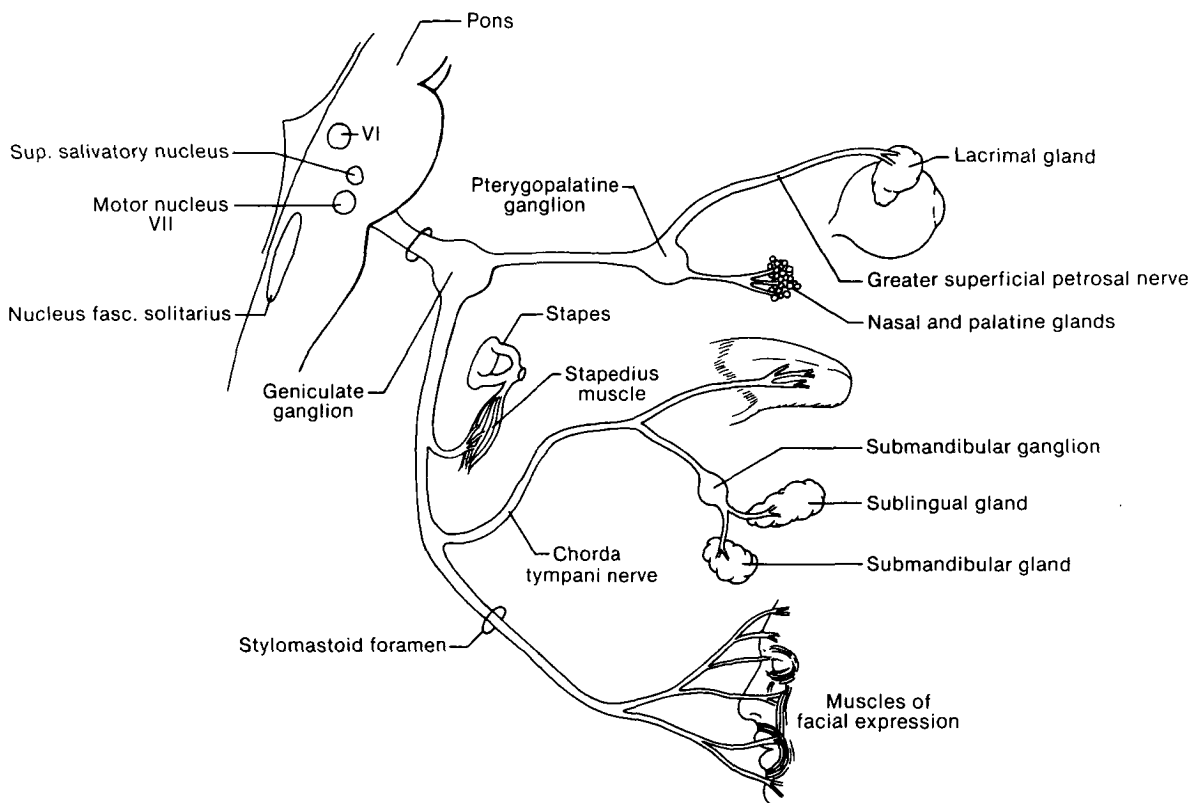


FIG 1. Anatomy of the facial nerve (Olsen 1984; Alford et al. 1973; Carpenter 1978; Montgomery 1981).

they may be classified as a central type or a peripheral type (Fig 2—Carpenter 1978; Montgomery 1981).

The central type involves the corticobulbar fibers which convey impulses from the cerebral cortex to the cells of the motor nucleus of the facial nerve. A central lesion interrupting the corticobulbar pathways results in paralysis only of the lower facial muscles on the *opposite* side of the lesion. This is explained

by the fact that the corticobulbar fibers to the forehead and the upper half of the face are distributed bilaterally; however, the fibers to the lower half of the face are predominantly crossed.

The peripheral type lesion of the facial nerve occurs at the level of the pons or anywhere along the distal course of the nerve. This lesion produces total facial paralysis on the *same* side as the lesion.

A central lesion produces a less severe type of facial paralysis compared to the peripheral lesion, but its origin may represent a serious problem in the brain. A simple neurological test to differentiate a central from a peripheral lesion in a patient with facial nerve paralysis is to ask the patient to wrinkle the forehead; if the patient can wrinkle the entire forehead, the lesion is centrally located. If the patient can wrinkle only half the forehead, the lesion is peripherally located.

### Bell's Palsy

Sir Charles Bell originally described this condition in 1821. The term Bell's palsy is used to describe an acute-onset, idiopathic facial paralysis resulting from a dysfunction anywhere along the peripheral part of the facial nerve from the level of the pons distally.<sup>4</sup>

<sup>4</sup> Olsen 1984; Blattner 1969; McGovern and Estevez 1983; Peitersen 1982.

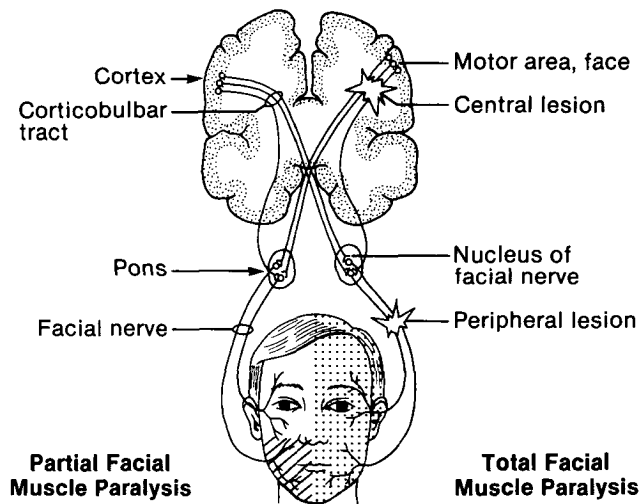


FIG 2. Muscle paralysis difference between a central lesion and a peripheral lesion of the facial nerve (Carpenter 1978; Montgomery 1981).

There are many theories about the cause of Bell's palsy but the etiology is unknown (Shafer et al. 1983). The most popular hypothesis is that it is caused by a virus similar to Herpes simplex or zoster.<sup>5</sup> Other proposed etiologies include physiologic compression of the nerve due to arteriospasm, venous congestion or ischemia, and narrowing of the bony canal (Olsen 1984; Shafer et al. 1983). Several case reports support a familial tendency suggesting the inheritance of an aberrant facial canal.<sup>6</sup>

Bell's palsy is rare in children under the age of 2 years (Blattner 1969). Its occurrence is slightly greater in females at a 1.5 to 1 ratio (Olsen 1984; Shafer et al. 1983). There is no race predilection for Bell's palsy (Olsen 1984). The incidence is 1 in 5000 persons per year (Olsen 1984).

The signs of Bell's palsy include widening of the palpebral fissure, flattening of the nasolabial fold, and drooping of one corner of the mouth when smiling (Shafer et al. 1983; Abbas and Prabhu 1981). These signs occur on the same side of the face as the lesion. There may be an inability to wrinkle half of the forehead, to close one eye completely, and to purse the lips (Shafer et al. 1983; Abbas and Prabhu 1981). Bell's phenomenon is a classic condition wherein the eye cannot close without a simultaneous movement of the eyeball upward and outward (Abbas and Prabhu 1981).

The symptoms of Bell's palsy include pain and numbness on the affected side of the face, especially in the temple, mastoid area, and along the angle of the mandible (Shafer et al. 1983). The mouth may be dry due to decreased salivary secretion and there may be loss of taste on the anterior  $\frac{2}{3}$  of the tongue as well as hyperacusis on the affected side (Abbas and Prabhu 1981).

The most important treatment measure is supportive care for the eye (Adour 1982; Hughes 1983). Daytime artificial tears and a nighttime eye patch are recommended to prevent corneal abrasion (Olsen 1984). For persons with persistent paralysis of the facial nerve, treatment modalities such as steroid therapy and surgical nerve decompression have been prescribed.<sup>7</sup>

Most authors agree that 75% of Bell's palsy cases regress spontaneously with complete recovery. Approximately 15% of the cases have satisfactory recovery with a slightly detectable neurological deficit and 10% of the cases have permanent paralysis (Olsen 1984). A favorable prognosis is associated with Bell's palsy which occurs in a single episode, is painless, involves only a partial paralysis of the peripheral part

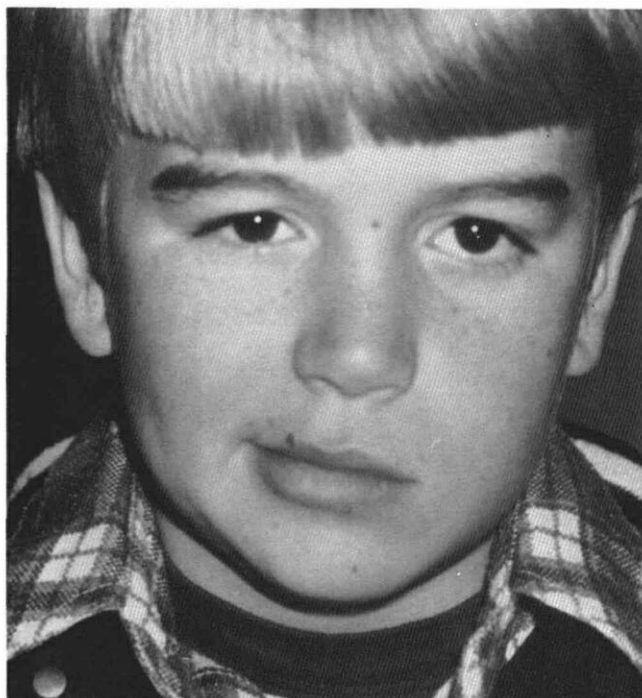


FIG 3. Case 1: Left-side facial nerve paralysis secondary to Bell's palsy.

of the facial nerve, and has early signs of recovery (Olsen 1984). A good prognosis is associated with Bell's palsy seen in children (Olsen 1984; Peitersen 1982).

### Case One

An 11-year, 5-month-old white male presented to the pediatric dentist with the chief complaint of "not being able to close his left eye or smile." The father first noted the signs the previous morning, including swelling along the left border of the mandible and jumping of the left upper eyelid.

An extraoral exam revealed left-sided facial nerve paralysis. The left muscles of facial expression did not participate when the child smiled. No swelling was apparent. The left eye would close only partially (Fig 3).

Prior to the onset of paralysis, the child had been a regular dental patient for 2 years and received routine treatment. An intraoral examination revealed no etiology to explain the facial paralysis.

### Past Medical History

The patient was an 8 pound, 14.5 ounce product of a full-term, spontaneous delivery. Gestation was normal and there were no complications at birth. The patient had experienced no previous serious illnesses or injuries. There were no known drug allergies nor were medications being taken. Upon recognition of the left-sided facial paralysis, the child's pediatrician

<sup>5</sup> Adour 1982; Olsen 1984; McGovern and Estevez 1983.

<sup>6</sup> Shafer et al. 1983; Burzynski and Weisskopf 1973; Samuel 1984.

<sup>7</sup> Adour 1982; Olsen 1984; Hughes 1983.

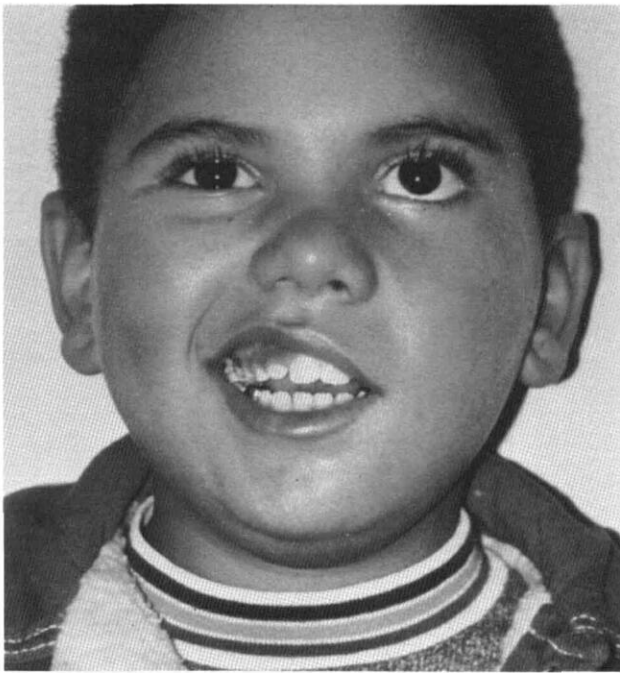


FIG 4. Case 2: Left-side facial nerve paralysis secondary to brain stem tumor.

was consulted. The pediatrician recommended that the patient be seen by an ophthalmologist.

#### Ophthalmologist's Consultation

The ophthalmologist saw the child immediately and documented a negative history for headaches, nausea, vomiting, weakness, or paresthesia. The child had experienced no change in taste, but had noticed an increase in noise through the left ear. The father denied any history of eye infection or trauma. The family history was negative for any ocular diseases. The ophthalmic examination revealed an eyelid lag with flattening of the nasal labial fold on the left side. The child was able to abduct both eyes. The remaining examination was within normal limits.

The clinical impression was Bell's palsy involving the left side, but the ophthalmologist recommended the patient be evaluated by a neurologist to rule out any further neurological problems.

#### Neurologist's Consultation

The neurologist saw the patient on the same day and confirmed the diagnosis of Bell's palsy. Symptomatic treatment was recommended for the eye, including daytime artificial tears and a night eye patch to prevent corneal abrasions.

One month after onset of the facial paralysis, the child was seen in the pediatric dentist's office again and the symptoms of Bell's palsy were hardly noticeable. At a recall visit 3 months later, the child had complete resolution of Bell's palsy.

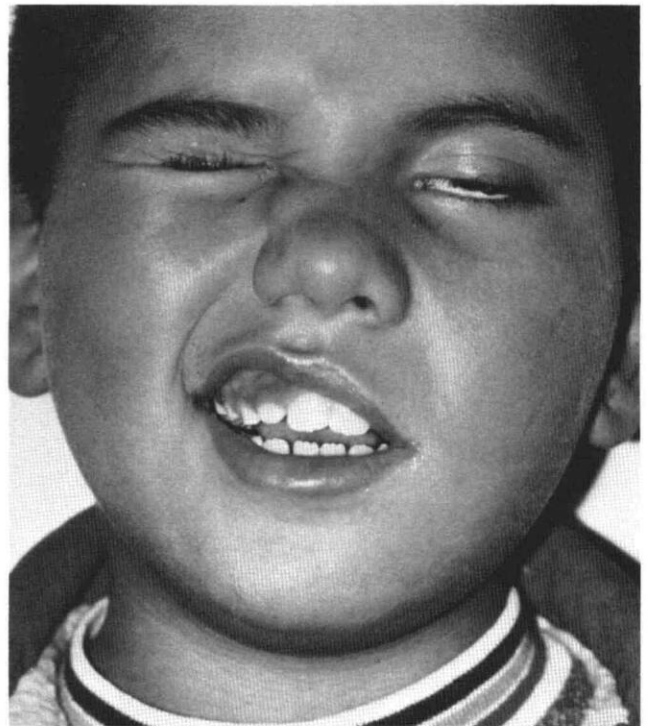


FIG 5. Case 2: Bell's phenomenon or inability to close the left eye completely.

#### Case Two

This case involved an 8-year, 2-month-old black male. On 12 January 1982, the mother called the pediatric dentist to report that her son's jaw "looked swollen and twisted when he smiled." Examination revealed that when the child smiled, the mouth deviated to the right side and the right eye closed (Fig 4). The patient could not close his left eye completely (Fig 5).

The patient had been seen regularly by the pediatric dentist for 3 months for preventive and restorative care and space maintenance. The intraoral examination revealed no etiology for facial nerve paralysis.

#### Past Medical History

The child was a 6 pound, 12.5 ounce product of a full-term breach cesarean section, followed by an uneventful neonatal period. Developmental milestones had been reached within normal limits.

#### Further Medical Work-Up

At the time of clinical observation of the facial distortion, the pediatric dentist suspected Bell's palsy and referred the patient to a pediatrician. The pediatrician supported the diagnosis of Bell's palsy and recommended no treatment.

## Sequelae and Hospital Course

Two weeks after the child presented originally to the dentist, he experienced a choking episode while eating. The mother performed the Heimlich maneuver several times and the child vomited and became unconscious. Cardiopulmonary resuscitation was initiated by the mother and the rescue squad was called and arrived within 20 min. Food was suctioned from the nasopharynx, an airway placed, and oxygen administered. The child became arousable during transport to the local county hospital. He was transferred immediately to a tertiary care medical center.

Upon arrival at the medical center, the child was lethargic but verbally arousable. The mother reported that he had been experiencing left facial weakness and nonspecific headaches for more than 2 weeks. The mother expressed also that his school performance had deteriorated over the last month.

Physical exam in the emergency room revealed bilateral upgaze nystagmus and inability to abduct either eye. There was a decreased gag response bilaterally. The palate rose symmetrically in the midline. There was no evidence of deviation of the tongue from the midline. The sensory examination was intact to all modalities. Deep tendon reflexes were greater in the lower extremities than the upper. A chest radiograph revealed bilateral aspiration pneumonia and a pneumomediastinum.

The child was admitted to the intensive care unit and placed on Dexamethasone® to control intracranial pressure. He was treated for aspiration pneumonia.

The neurological assessment revealed a left facial nerve palsy, a left lateral rectus muscle palsy, a mild right hemiparesis with the upper extremities more affected than the lower, and positive bilateral Babinski signs. These signs were suggestive of a lesion in the pons at the level of the 7th cranial nerve. The differential diagnosis included pontine glioma, medulloblastoma, hemangioblastoma, and an arteriovenous malformation.

A brain CT scan localized a low density, non-enhancing mass in the region of the pons with posterior displacement of the 4th ventricle. A presumptive diagnosis of a pontine glioma was made.

The neurosurgeons recommended radiation therapy in view of the morbidity associated with a tumor biopsy. A second opinion obtained from another medical center corroborated the radiation therapy treatment protocol. At the completion of radiation therapy, the left facial nerve palsy was less conspicuous and the right hemiparesis was not detectable. There was no significant change in the brain CT scans during radiation therapy.

Eight months from the original admission, the patient presented to the emergency room with a

3-week history of intermittent frontal headaches, abdominal pain, nausea, and vomiting. The physical examination revealed a slurred, monotone speech. A new brain CT scan displayed significant changes including compression of the lateral ventricles which created obstructive hydrocephalus. Shunt placement and tumor biopsy were recommended but the mother elected noninvasive treatment due to morbidity associated with surgery. Periodic clinic examinations were recommended and 1 month later the brain CT scan revealed a significant increase in the size of the tumor and progressive metastasis into the lateral ventricles. Surgery was refused again.

Twelve months from the original diagnosis the child died of a cardiopulmonary arrest believed to be secondary to the pontine tumor.

## Discussion and Conclusion

Though a small percentage of children presenting with facial nerve paralysis have a brain stem tumor, a thorough medical evaluation is necessary to verify the absence of other neurological signs and symptoms which may reflect intracranial pathology (May et al. 1981; Jackson et al. 1980). Bell's palsy should be a diagnosis of exclusion.

As was the case with both of these young patients, the dentist may be the first to see such patients because of the orofacial involvement with paralysis of the facial nerve. Proper assessment of a child with facial nerve paralysis is needed to make an accurate diagnosis and give the correct prognosis. In summary, the most important thing the dentist can do is make a prompt and appropriate referral because early detection of intracranial pathology may improve the child's prognosis.

Dr. Keels is a fellow, Dr. Long is a clinical assistant professor, and Dr. Vann is an associate professor and chairman, pediatric dentistry, The University of North Carolina at Chapel Hill. Dr. Long also is in private practice, pediatric dentistry and orthodontics in Burlington, North Carolina. Reprint requests should be sent to: Dr. Martha Ann Keels, Dept. of Pediatric Dentistry, The University of North Carolina at Chapel Hill, School of Dentistry 209H, Chapel Hill, NC 27514.

Abbas KED, Prabhu SR: Bell's palsy among Sudanese children—report of 7 cases and review of literature. *J Oral Med* 36:111-13, 1981.

Adour KK: Current concepts in neurology—diagnosis and management of facial paralysis. *N Engl J Med* 307:348-51, 1982.

Alford BR, Jerger JF, Coats AC, Peterson CR, Weber SC: Neurophysiology of facial nerve testing. *Arch Otolaryngol* 97:214-19, 1973.

Blattner RJ: Bell's palsy in children. *J Pediatr* 74:835-37, 1969.

Burzynski NJ, Weisskopf B: Familial occurrence of Bell's palsy. *Oral Surg* 36:504-6, 1973.

Carpenter MB: *Core Text of Neuroanatomy*, 2nd ed. Baltimore; Williams and Wilkins Co, 1978 pp 126-28.

- Hughes GB: Current concepts in Bell's palsy. *Ear Nose Throat J* 62: 6-13, 1983.
- Jackson CG, Glasscock ME, Hughes G, Sismanis A: Facial paralysis of neoplastic origin: diagnosis and management. *Laryngoscope* 90:1581-95, 1980.
- May M, Fria TJ, Blumenthal F, Curtin H: Facial paralysis in children: differential diagnosis. *Otolaryngol Head Neck Surg* 89: 841-48, 1981.
- McGovern FH, Estevez J: Current concepts in the etiology and pathology of Bell's palsy. *Va Med* 110:544-46, 1983.
- Montgomery RL: Head and Neck Anatomy with Clinical Correlation. New York; McGraw-Hill Book Co, 1981 pp 194-96, 309-13.
- Olsen KD: Facial nerve paralysis 1. General evaluation, Bell's palsy. *Postgrad Med* 75:219-25, 1984.
- Peitersen E: The natural history of Bell's palsy. *Am J Otol* 4:107-11, 1982.
- Samuel J: Familial Bell's palsy. *J Laryngol Otol* 98:977-79, 1984.
- Shafer WG, Hine MK, Levy BM: A Textbook of Oral Pathology, 4th ed. Philadelphia; WB Saunders Co, 1983 pp 859-60.

## Pediatric Dentistry: Reviewers

On behalf of the American Academy of Pediatric Dentistry, the editorial staff wishes to thank those individuals who have spent valuable time reviewing manuscripts for the *Journal*. Their professional expertise has contributed greatly to the quality of this publication. Those listed were sent manuscripts from January 1 through December 31, 1986.

### A

Alexander, Stanley A.

### B

Barenie, James T.  
Bernick, Sheldon M.  
Binns, William H., Jr.  
Bixler, David  
Bugg, James L., Jr.  
Burzynski, Norbert J.

### C

Catalanotto, Frank A.  
Cisneros, George J.  
Cooley, Robert  
Corcoran, John W.  
Creedon, Robert L.  
Croll, Theodore P.  
Currier, G. Fräns

### D

Davis, Martin J.  
Dummett, Clifton O., Jr.

### F

Ferguson, Fred S.  
Fields, Henry W., Jr.  
Fippinger, Terrance  
Full, Clemens A.

### G

Goldblatt, Lawrence I.  
Golnick, Arnold L.  
Good, David L.  
Goodson, Max

### H

Henderson, Hala Z.  
Hennon, David K.  
Houpt, Milton I.

### J

Johnsen, David C.  
Jones, James E.  
Jorgenson, Ron

### K

Kennedy, David B.  
Koerber, Leonard G.  
Kopel, Hugh  
Kracke, Roy R.  
Krutchkoff, David

### L

Lewis, Thompson M.  
Loos, Paul J.  
Luke, Larry S.

### M

Miller, Chris  
Miller, Jerome B.  
Mink, John R.  
Moore, Paul  
Musselman, Robert J.  
McDonald, John S.

### N

Nelson, Linda P.

### P

Porter, Donald R.

### R

Ripa, Louis W.  
Roberts, J. Keith  
Rovelstad, Gordon H.

### S

Saunders, William A.  
Schneider, Paul E.  
Setcos, James  
Shey, Zia  
Shusterman, Stephen  
Silverstone, Leon M.  
Spedding, Robert H.  
Starkey, Paul E.  
Straffon, Lloyd H.  
Strange, Evelyn M.  
Sullivan, Robert E.

### T

Thomas, Joe P.  
Tinanoff, Norman  
Troutman, Kenneth C.

### V

Vann, William F., Jr.

### W

Weber, John D.  
White, Stephen T.  
Wright, Gerald Z.