



# The treatment and long-term management of severe multiple avulsions of primary teeth in a 19-month-old child

Ari Kupietzky, DMD, MSc

*Dr. Kupietzky is in private practice, Jerusalem, Israel. Correspond with Dr. Kupietzky at drkup@netvision.net.il*

## Abstract

*Traumatic injury to the primary dentition is a common occurrence in young preschoolers. The maxillary incisors and, more specifically, the central incisors, are the most commonly injured teeth. The purpose of this article is to present the immediate and long-term treatment and management of a severe case of multiple avulsions involving all maxillary incisors and canines and the right first primary molar in a 19-month-old child, due to trauma. Esthetic, functional and orthodontic considerations are discussed. (Pediatr Dent 23:517-521, 2001)*

**T**raumatic injury to the primary dentition is a common occurrence in young preschoolers. The maxillary incisors and, more specifically, the central incisors, are the most commonly injured teeth.<sup>1</sup> The treatment and management of such injuries have been discussed extensively in the dental literature and are well known to pediatric dentists. However, injuries involving the primary molars are much less common. Only 0.5% of injuries occurring in preschool children involve the primary molars.<sup>2</sup> The most common types of injuries involving molars are crown fractures.

The purpose of this article is to present the immediate and long-term treatment and management of a severe case of multiple avulsions involving all maxillary incisors and canines and the right first primary molar in a 19-month-old child due to trauma. Esthetic, functional and orthodontic considerations are discussed.

## Incidence

The incidence of traumatic injury to the primary dentition ranges between 4%-30% depending on the location and type of study.<sup>3</sup> There is an increase from 1 year of age with a peak of just under 10% by 3 years of age.<sup>1,4</sup> Most children start to walk at about 1 year of age; by 2 years of age children can run and by 3 years of age ride a tricycle. This rapid increase in physical activity and daringness is associated with an increase in orodental trauma.<sup>4</sup>

Over 70% of the dental injuries involve the maxillary central incisors.<sup>1</sup> Boys sustain slightly more traumatic injuries than girls do; the ratio being 1.2-1.8 boys to 1 girl affected.<sup>1</sup>

## Etiology

Orodental injuries result from a blow to the soft tissues and/or teeth. The blow is often severe, although even apparently trivial blows can have untoward effects.<sup>4</sup> Few injuries occur during the first year of life. However, as children learn to walk they tend to fall. Falls account for the majority of injuries to

**Table 1. Avulsion in the Primary Dentition: A Summary**

**Etiology** - Falls and hitting teeth against hard objects are the most common causes.

**Incidence and prevalence** - Seven to 13 % of all trauma to the primary dentition involves avulsion (resiliency of alveolar bone, short root length). Boy-to-girl ratio of 1.8 to 1. Incidence increases from one year of age and peaks by age three to 10%.

**Location** - Over 70% involve the maxillary central incisors.

**Sequelae to successors** - Fifty percent of all avulsions will lead to varying degrees of developmental defects of the permanent successor. The effect on a successor tooth, if any, is usually a mild white or yellow/brown discoloration—hypoplasia or hypomineralization. Seldom are more serious defects present such as dilaceration.

**Treatment and parent counseling** - As a rule, do not replant avulsed primary teeth (which can result in ankylosis, infection, subsequent iatrogenic damage during replantation and poor patient cooperation). Space maintenance is usually not necessary if incisors are avulsed. Loss of canines and/or molars may result in future space loss. Parents should be advised that a delay in eruption of one year generally occurs if the loss has occurred at an early stage of development.

the primary teeth.<sup>1</sup> As soon as the child learns to move about and gains independence coupled with limited coordination, the incidence of injury increases. As the child develops greater awareness of danger and learns defensive reflexes, the incidence decreases.

## Types of injuries

Due to the resiliency of the alveolar bone surrounding the primary teeth, the majority of injuries to the preschooler are tooth luxations.<sup>1</sup> Other contributing factors include incomplete root formation and relatively short roots. However, various studies have shown that exarticulation—complete avulsion of primary teeth due to trauma—is relatively infrequent.<sup>1</sup> Only 7%-13% of all traumas to the primary teeth involves avulsion. Most frequently, avulsion involves a single tooth, usually an incisor, but multiple avulsions are occasionally encountered.<sup>1</sup>

## Complications to succedaneous teeth

Due to the proximity of the root of the primary tooth to the crown of its permanent successor during early childhood, there is a significant potential for damage to the permanent tooth

Received May 1, 2001 Revision Accepted October 5, 2001

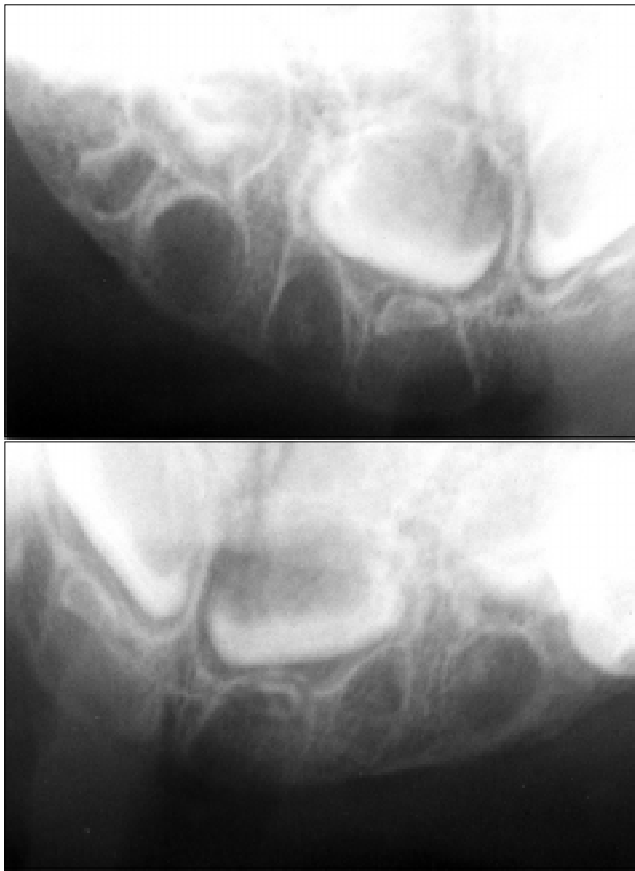

Fig 1. Right (above) and left (below) occlusal radiographs demonstrating empty avulsion sockets of all incisors, canines and right first primary molar. Note residual root apex of right central incisor. Also, it appears that both permanent lateral incisor tooth follicles are missing. Radiographs were exposed adjacent to the traumatic incident.

when a primary tooth is injured. The effect may be either direct or indirect: Directly, for example, at the time of avulsion the apex of the primary tooth may damage the tooth follicle of the developing permanent tooth. Indirectly, for example, when a primary tooth becomes non-vital, periapical infection may damage the immature labial enamel of the underlying permanent tooth.<sup>4</sup>

The relevant factors in determining the potential to succedaneous tooth damage are the type of injury and age of its occurrence.<sup>4,5</sup> Intrusive luxations (69%) followed by avulsions (54%) are the most associated with resultant damage to the permanent successors.<sup>5</sup> The age of the child also determines whether damage to succedaneous teeth will result or not. The highest incidence of damage to the permanent tooth is between 0-2 years of age. The probability of a young child under 4 years of age having damage to permanent teeth after sustaining a traumatic injury is 60%.<sup>4</sup>

The effect on the succedaneous tooth may be a mild white or yellow/brown discoloration—hypoplasia or hypomineralization. In the majority of the cases, the damage will be amenable to cosmetic treatment once the tooth has fully re-erupted. More serious sequelae include: dilaceration of the crown or root of the permanent tooth which is dependent on the degree of displacement of the primary root apex; the degree of alveolar damage; and the stage of formation of the permanent tooth.<sup>5</sup>

## Case description

A 19-month-old Caucasian male was referred by a general dentist for evaluation and suture removal following multiple avulsions due to trauma. Earlier in the week, the child had fallen down a flight of stairs while sitting in his baby stroller. Immediately at the time of the injury, the child was brought to a next-door neighbor who was a dentist. The dentist diagnosed complete avulsion of all maxillary incisors, canines and right first primary molar.

Emergency dental first-aid care was given. While both parents restrained the child, four sutures were placed in the area of injury above the avulsion sockets. The patient tolerated the procedure well and was immediately referred to a major medical hospital center for comprehensive medical examination and monitoring. The child was discharged on the same day by the emergency medicine department after all potential injuries, including neurologic and orthopedic injuries, were ruled out. The parents were told to return to the hospital in five days for a follow-up exam and suture removal. The parents opted to have sutures removed and receive future follow up exams at a private pediatric dentist and not at the medical center.

The clinical examination revealed a frightened child. No lacerations were present and extra-oral swelling was minimum. In the maxilla only one tooth was present—the left first primary molar. Avulsion sockets appeared to be healing with white/yellowish granulation tissue covering the injury sites. The mandible presented with first molars and incisors fully erupted and canines partially erupted. All remaining primary teeth appeared to have not sustained any injuries and were non-mobile and asymptomatic. The parents presented two radiographs exposed at the hospital on the day of the injury (Fig 1).

Based on the radiographs, avulsion of all teeth appeared to be complete and no residual roots were detected save for a small root apex of the right central incisor. Also noted, was the absence of both lateral incisor tooth buds. Parental consent was obtained and the child was placed in a Papoose Board™ (Olympic Medical, Seattle, WA) and a mouth prop was inserted to facilitate suture removal. Minimal bleeding was controlled with the application of gauze pad pressure. Parents were informed that multiple avulsions, including molars, are a rare occurrence, that replantation was not indicated at the time of injury nor at the present time and that a space maintainer would be necessary in the future to address future esthetic, functional and

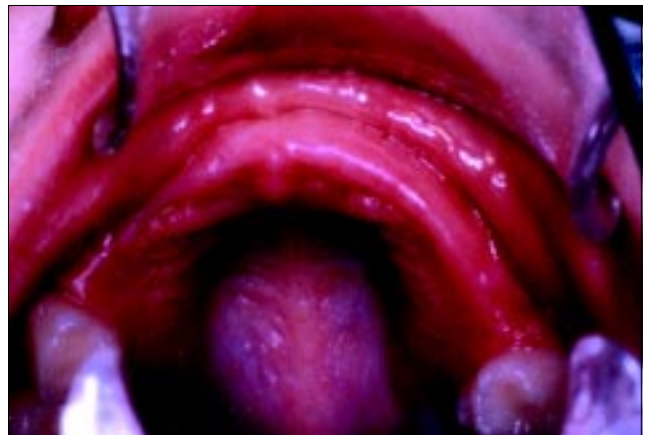

Fig 2. Occlusal view of the 34-month-old patient approximately one year following the avulsion trauma

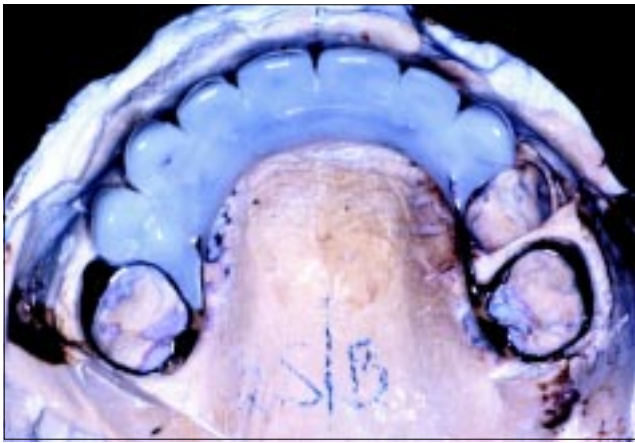


Fig 3. Occlusal view of the fixed anterior appliance. Due to the child's young, pre-cooperative age, a fixed appliance was recommended to be replaced by a removable one at a later stage.

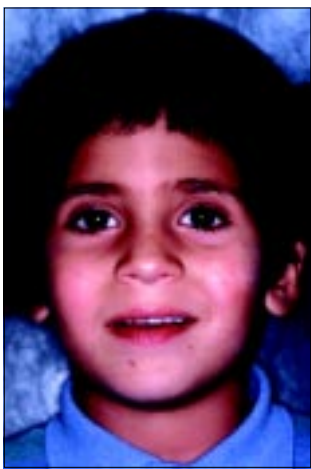

Fig 5. Facial view of the appliance demonstrating the positive adaptation of the child to the appliance

orthodontic needs. The prognosis of the residual root and its probable resorption or exfoliation was also explained. One week later, all soft tissues were healing without any complication and the patient was placed on a six-month recall.

Six months later, the child returned as requested and examination revealed second primary molars erupting. The exam was performed "knee to knee" and was well tolerated by the patient. Patient was placed on six-month recall. At the next recall examination the patient was 34-months old (Fig

2). The option of the placement of a fixed pedo-partial appliance (modified Nance holding arch) was discussed and consent was obtained for treatment. Prefabricated stainless steel bands (3M Unitek™ pedodontic molar bands, 3M Unitek™ Dental Products, Monrovia, CA) were fitted on the right maxillary second molar and the left maxillary first molar (first molars are preferred as abutments over second molars due to a shorter wire span and less potential interference with erupting six-year molars). An alginate impression with the bands in place was taken. Although the child was less than cooperative, an effort was made to take a mandibular alginate impression and wax bite registration.

Two weeks later, the child returned for appliance cementation. The appliance was similar to a Nance holding arch, but had plastic teeth processed onto the wire instead of a palatal acrylic button in the rugae area (Fig 3). The round wire was thick and rigid (0.040 inch in diameter) and was attached to the first and second primary molars with prefabricated stainless steel bands. Each individual tooth was welded and soldered onto the archwire. Although the arch wire had a relatively long span, it was particularly stable due to its unique fabrication and rigid attachment to the bands. The palatal acrylic button of the traditionally designed modified Nance holding arch was

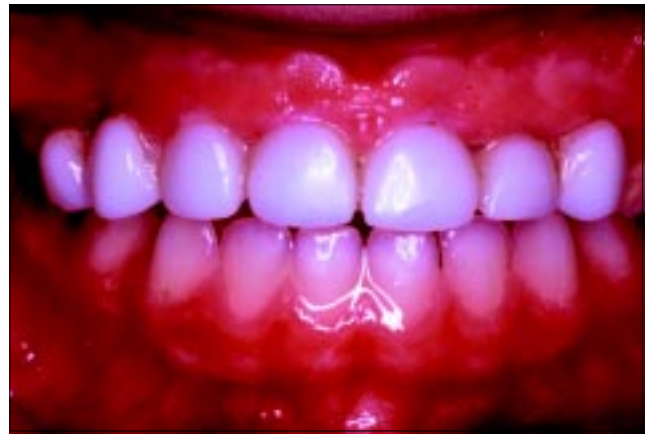

Fig 4. Intraoral view demonstrating the appliance after two years of use

eliminated. Generally, this button is a potential source of palatal irritation and inflammation and, particularly in this case involving a very young child, due to the prolonged period of time it would have to be worn until the eruption of permanent teeth. The appliance was cemented. Any glass ionomer cement or light-cured band adhesive may be used.

Six months later the patient returned with red hypertrophic gingival inflammation. The appliance was removed and strict oral hygiene instructions were given. Five days later, the gingiva had improved and the appliance was recemented. The patient continued to return for recall examinations at 4- to 6-month intervals (Figures 4, 5). At age four-and-a-half it was determined that the child was mature enough to adapt and care for a removable appliance and a decision was made to replace the fixed appliance with a removable one (Figures 6, 7). Composite build-ups were placed on the buccal aspects of the molar abutment teeth to aid in retention of the appliance. The

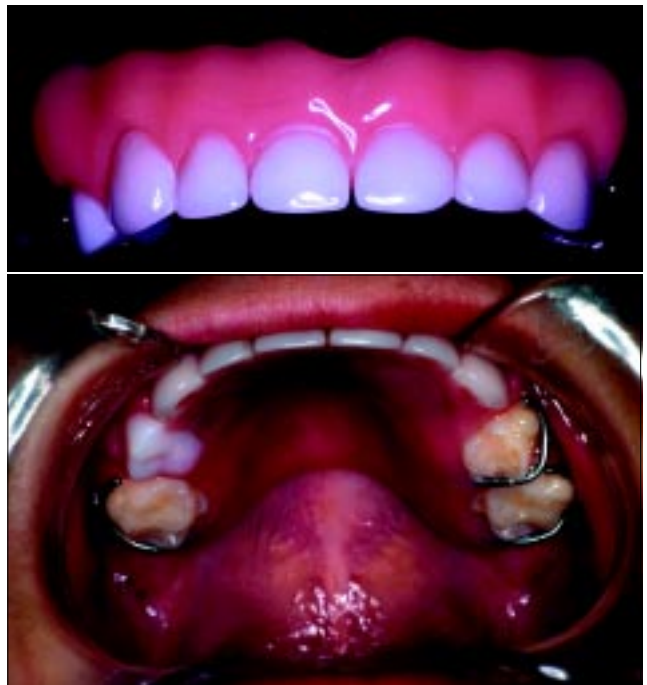

Fig 6. At age four-and-a-half, it was determined that the child was mature enough to adapt and care for a removable appliance. Anterior (above) and intraoral occlusal (below) views of the removable appliance.

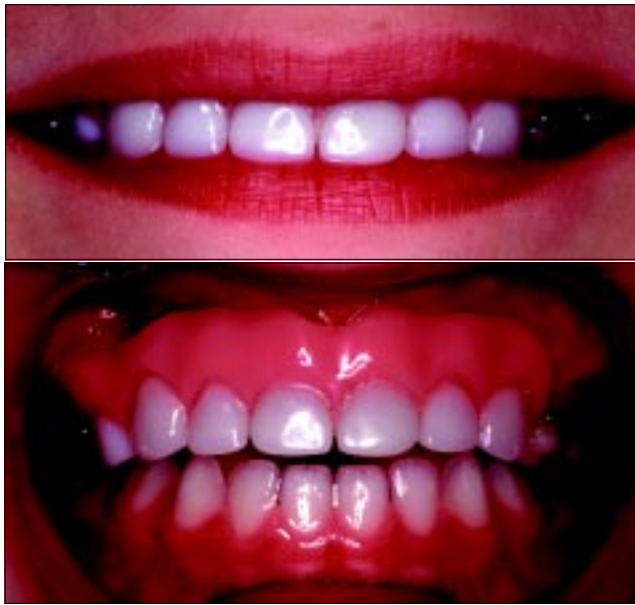

Fig 7. Anterior extraoral (above) and intraoral (below) views of the appliance in situ

appliance's retention consisted of a labial flange extending into the labial vestibulum and orthodontic clasps held into place with the composite buttons on the molars. The child adapted well to the appliance and was placed on six-month recalls.

Six years following the initial accident, the child returned for his biannual check up with the right and left central incisors erupting (Fig 8). The pedo-partial was removed and a removable retainer was fabricated without any anterior esthetic component; its purpose was to allow the eruption of the incisors without any interference and to prevent any posterior space loss from occurring (Fig 9).

## Discussion

In a recent paper, an emphasis was made on the elective nature of placing an esthetic fixed anterior appliance to replace missing incisors.<sup>7</sup> The position of the authors was that the most decisive factor for placing an anterior esthetic appliance is parental desire. It was discussed that, while space maintenance, masticatory function, speech development and tongue habits may be of some consideration, there is no strong evidence that early loss of maxillary incisors will have any significant, long-lasting effect on the growth and development of the child. However, in the case presented in this paper, placement of an appliance was mandatory due to the following reasons:

1. Although space maintenance following loss of all incisors in the anterior region is usually not necessary since this region appears to be stable with no net loss of space from canine to canine, this case is different. The loss of a canine and a first molar prior to the eruption of second molars can result in significant space loss and the placement of a suitable space maintainer is necessary.
2. Yet another consideration is the child's speech development following loss of all four incisors. Although this issue remains somewhat controversial, a consensus exists regarding development of future speech defects if the teeth are lost prior to age three. Many sounds are made with the tongue touching the lingual side of the maxillary incisors and inappropriate speech compensations can develop if the teeth are missing. One study demonstrated that children who

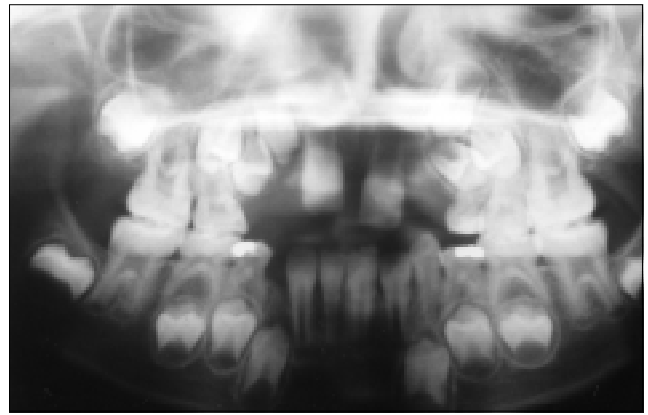


Fig 8. Six years following the trauma, a panoramic radiograph was taken. Note the lack of both lateral incisor tooth buds. Signs of sequelae due to avulsion may be seen in the developmental enamel defects of both upper central incisors (mesial and distal aspects) and in the ectopic position of the left upper first premolar.

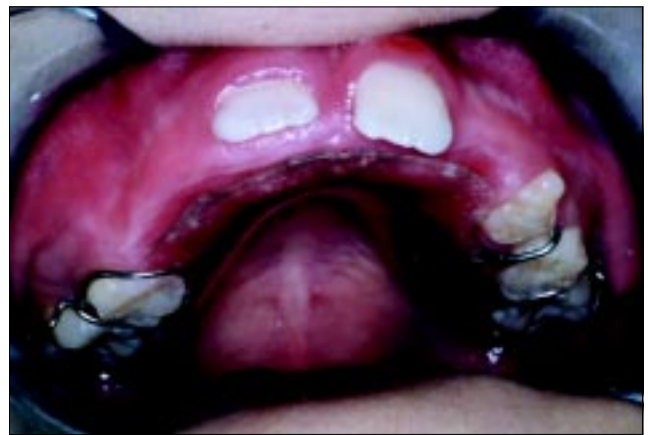

Fig 9. Anterior/occlusal view of the patient at six-year follow-up. An acrylic removable appliance is functioning as an interim space maintainer.

had worn dentures from early childhood exhibited no articulation errors, while those who did not exhibited articulation errors directly related to dentition. This study concluded that patients who receive prosthetic dental appliances (two years is optimal as related to speech) develop better articulation skills.<sup>8</sup> Another study<sup>9</sup> found that loss of all maxillary primary incisors before age 3 years resulted in some speech problems in some children. While the data is incomplete, appliances for children under 3 years of age that have not yet developed their speech skills (children over 4 years will usually compensate for the tooth loss and not exhibit any long-term speech disorders) should be highly considered.

3. One of the most important and valid reasons for replacing missing incisors is to restore a natural and pleasing appearance and thus provide an opportunity for normal psychological development. Although body image alterations bear little significance to the very young,<sup>10</sup> the loss of seven teeth at such a young age most likely would have had a negative effect on this patient's self esteem and image. Indeed, the patient became so attached to the appliance that he was reluctant to allow its removal for a short period of time to allow resolution of gingival inflammation induced by poor oral hygiene.

## References

1. Wilson, CFG. Management of trauma to primary and developing teeth. *Dental Clinics of North America* 39:133-167, 1995.
2. Mentz DD, Rollefson JH. Avulsion of a maxillary primary first molar in a 19-month-old child. *Pediatr Dent* 15:47-48, 1993.
3. Fried I, Erickson P. Anterior tooth trauma in the primary dentition: Incidence, classification, treatment methods, and sequelae: A review of the literature. *J Dent Child* 62:256-261, 1995.
4. Longhurst P, Roberts G, eds. Injuries affecting the deciduous dentition. In: *Oral and Dental Trauma in Children and Adolescents*. Oxford: Oxford University Press; 1996:27-35.
5. Andreasen JO, Andreasen FM, Bakland LK, Flores MT. Injuries to the primary dentition. In: *Traumatic Dental Injuries – A Manual*. Copenhagen: Munksgaard Publishers; 1999:44-47.
6. Cameron A, Widmer R. Trauma management. In: *Handbook of Pediatric Dentistry*. Mosby-Wolfe: London; 1997:95-141.
7. Waggoner WF, Kupietzky A. Anterior esthetic fixed appliances for the preschooler: considerations and a technique for placement. *Pediatr Dent* 23:147-150, 2001.
8. Coston GN, Salinas CF. Speech characteristics in patients with hypohidrotic ectodermal dysplasia in Birth defects: Original article series. 24:229-234, 1988.
9. Riekman GA, El Badrawy HE. Effect of premature loss of primary maxillary incisors on speech. *Pediatr Dent* 7:119-22, 1985.
10. Lynch M. Special children, special needs: the ectodermal dysplasias. *Pediatric Nursing* 18: 212-216, 1992.

American Board



## The American Board of Pediatric Dentistry is pleased to announce New Diplomates

May 28, 2000 to May 11, 2001

Roger A. Achong – Concord, NH  
Jeffrey J. Ahlert – Bartlesville, OK  
Ali A. Al-Eheideb – Riyadh, Saudi Arabia  
Aziza J. Al-Johar – Riyadh, Saudi Arabia  
Corine Barone-Cognata – Marblehead, MA  
Melanie J. Blanton – Easley, SC  
Ludivina R. Casas – Houston, TX  
Mark K. Choi – Fairfield, CA  
Supaporn Auychai Chongvisal – Tucson, AZ  
John P. Conry – Duluth, MN  
Dina S. Debaybo – Dubai, United Arab Emirates  
Michael B. Demeter – Lincoln Park, MI  
Michael Etesami – Columbia, MD  
Robyn Fung – Torrance, CA  
Shelby Gebbs-Posner – Madisonville, LA  
David L. Goldstein – Orlando, FL  
Margery E. Hernandez – Towson, MD  
Brian D. Hodgson – Milwaukee, WI  
Jeffrey J. Johnson – Rockford, IL  
Kavita Kohli – New York, NY  
Patricia A. Lewis – Bronx, NY

Douglas Lin – Columbus, OH  
John R. Liu – Issaquah, WA  
Robyn R. Loewen – Rochester, MN  
Barry K. Marcum – Peachtree City, GA  
Amr M. Moursi – Columbus, OH  
Leyla Z. Nakisbendi – White Plains, NY  
Amy E. Nedley – Beverly Hills, MI  
Ronald L. Poulos – Cincinnati, OH  
Nancy L. Rajchel – Mechanicsburg, PA  
Mario E. Ramos – Midland Park, NJ  
William D. Rawlings – Solana Beach, CA  
Shobreh Sharifahmadian – Fairfax, VA  
Thomas C. Silver – Pinellas Park, FL  
Daniel W. Sims – Henderson, NV  
Erwin T. Su – North Canton, OH  
Colleen P. Taylor – Bountiful, UT  
Wen-Shiun Tchaou – Taipei, Taiwan  
Terri E. Train – Richardson, TX  
Michael D. Webb – Dallas, TX  
Karen Yee – Lakewood, WA  
Cari M. Zupko – Berkley, MI