

Maxillary protraction for early orthopedic correction of skeletal Class III malocclusion

Paul W. Major DDS, MSc, MRCD(C) H.E. ElBadrawy, MS, HDD, DDS

Abstract

The clinical use of combined maxillary expansion and protraction headgear is reviewed. The diagnostic considerations necessary for appropriate case selection are discussed. A description of appliance technique is provided in sufficient detail to familiarize the pediatric dentist with the associated clinical procedures. (Pediatr Dent 15: 203–07, 1993)

Introduction

Treating the developing Class III skeletal malocclusion is one of the more challenging problems facing clinical orthodontists. The incidence of this type of malocclusion in a major Canadian city was found to be approximately 1% of the population with no apparent gender difference.¹ Some racial groups, in particular Asians, have a much higher frequency. It has been estimated that in Japan 3–13% of the population have a Class III skeletal malocclusion.²

Many practitioners avoid early treatment of the Class III skeletal malocclusion because they believe the condition is caused by mandibular overgrowth and therefore mandibular surgery is inevitable. Attempts to restrict mandibular growth using chin cup retraction devices largely have been abandoned. Recent studies suggest that malocclusions corrected in this way have limited stability³ and latent mandibular growth and a return to the pretreatment condition are common.^{4,5}

There is also concern about the long term-effects of chin cup therapy on temporomandibular joint health. Posterior condylar displacement has been implicated in developing TMJ internal derangement,⁶ and it is reasonable to postulate that forces of sufficient magnitude to inhibit condylar growth may cause the capsular ligaments to stretch, increasing the risk of TMJ dysfunction.

Several recent studies have shown that the majority of Class III malocclusions exhibit maxillary retrusion. Ellis and McNamara⁷ found that 65% of their sample exhibited a retrusive maxilla. Although this was associated with mandibular protrusion in 30% of the cases, it was also associated with normal mandibular skeletal position in 25% of the cases. Similarly Guyer et al.⁸ reported that of their total Class III sample, 25% had simple maxillary retrusion and 34% had combined maxillary retrusion and mandibular protrusion. In view of the high frequency of maxillary retrusion, managing many Class III malocclusions should include maxillary advancement as a major objective. Early intervention with orthopedic maxillary protraction provides a nonsurgical alternative.

Differential diagnosis

In treatment planning, correction of a Class III malocclusion several diagnostic features should be considered.

Functional assessment

An accurate diagnosis of the relationship of maxilla to mandible in centric relation is very important. Anterior positioning of the mandible generally results from abnormal tooth contacts that force the mandible forward. Patients presenting with a Class I skeletal pattern, normal facial profile, and Class I molar relation in centric relation, but a Class III skeletal and dental pattern in centric occlusion very often have abnormal incisor positioning. Treatment of this pseudo Class III problem should be undertaken as early as possible by advancing the maxillary incisors and/or retracting the mandibular incisors. Even a true Class III malocclusion can appear much more serious if there is an anterior path of mandibular closure.

Cephalometric assessment

Cephalometric analysis is commonly used to differentiate between maxillary retrusion and mandibular protrusion. The ANB angle in Class III samples is generally negative with a smaller than normal SNA angle (Fig 1 a,b). Unfortunately cephalometric analysis may be potentially misleading. Sue et al.⁹ reported that when SNA and SNB were used, the mandible was implicated as the major contributor, but when A point to Facial Plane and Nasion perpendicular to A point were used, the majority of cases were classified as maxillary retrusion. Individual variations in cranial base flexure and anterior/posterior displacement of Nasion (N) alter the ANB angle.¹⁰ Alternative cephalometric values to assess maxillary anterior/posterior relationship to the mandible and cranial base include Wits appraisal,¹¹ effective midface length,¹² Frankfort horizontal to NA,¹⁰ A point to Nasion perpendicular,¹² and A point to Facial Plane.¹³ All cephalometric measurements must take into account the amount of anterior functional shift from centric relation to centric occlusion. If the lateral cephalogram is taken with the patient in centric relation, any increased vertical dimension must be taken into account.

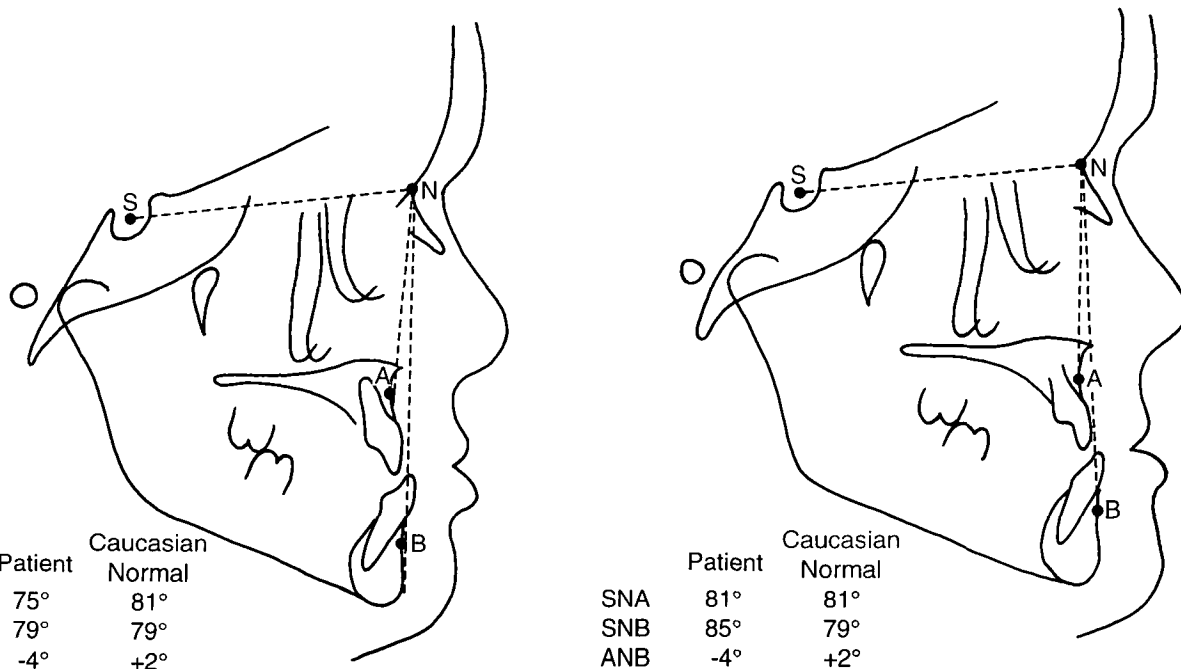


Fig 1. A. (left) Class III skeletal pattern due to maxillary retrusion. (Note the smaller than normal SNA angle and associated negative ANB angle.) B. (right) Class III skeletal pattern due to mandibular protrusion. (Note the larger than normal SNB angle and associated negative ANB angle.)

Clinical assessment

Because the treatment objective is to optimize facial esthetics, treatment decisions should be based more on the patient's facial features than cephalometric values. A facial evaluation involves an analysis of facial proportions, chin position, and midface position.¹⁴ Maxillary deficiency is evidenced by flattening of the infraorbital rim and the area adjacent to the nose. Very often patients will appear to have droopy lower eyelids and show excessive sclera. Looking at the patient in profile, block out the lower lip and chin with your hand to accentuate the midface. In a well-balanced face there is a convexity extending from the inferior border of the orbit through the alar base of the nose down to the corner of the mouth. A straight or

concave tissue contour indicates a midface deficiency. Similarly, chin position can be evaluated by using two fingers to block out the upper and lower lips. The chin should not be positioned anterior to a vertical line extending down from soft tissue Nasion. The lip posture is assessed for evidence of overclosure, amount of incisor display at rest and whether the lip looks adequately supported by the maxilla. It is important to realize that facial convexity normally decreases as the patient matures. A degree of chin prominence that would be normal in an adult may suggest a Class III skeletal pattern in a young child.

Vertical facial proportions and skeletal relationships also should be assessed. Clinically, vertical proportions

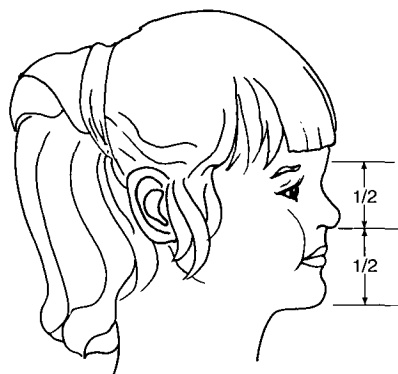


Fig 2. Normal facial proportions.

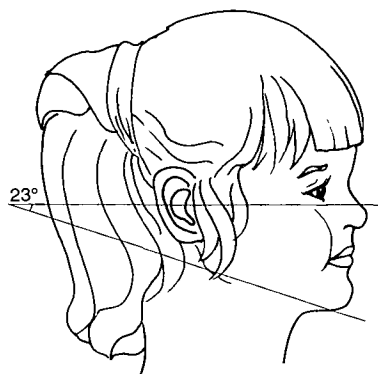
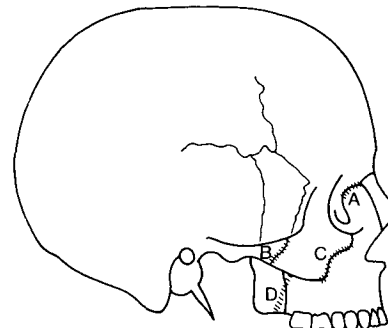


Fig 3. The Frankfort mandibular plane angle.



- A - Frontomaxillary
- B - Zygomaticotemporal
- C - Zygomaticomaxillary
- D - Pterygopalatine

Fig 4. Orientation of the circum-maxillary sutures.

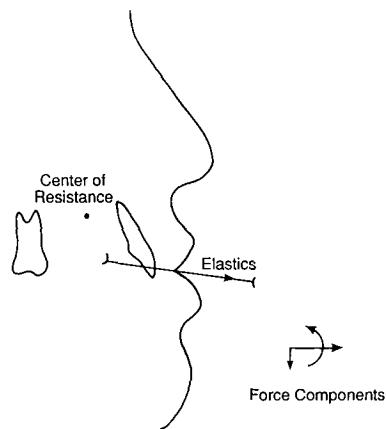


Fig 5. Force components associated with protraction headgear.

can be assessed by comparing the midface height to the lower face height. The distance from soft tissue Nasion to Subnasal (where the nose joins the upper lip) should equal the distance from Subnasal to soft tissue Menton¹⁴ (Fig 2). Nanda¹⁵ reported that the patterns of anterior facial proportions are estab-

lished at an early age and are maintained during growth. Growth direction is difficult to accurately predict, but growth trends may be clinically or cephalometrically assessed by measuring the Frankfort plane angle.¹⁶ Patients exhibiting excess vertical growth generally will have a larger than normal mandibular plane angle (Fig 3). Other cephalometric assessments of growth direction include FH to Y axis, facial axis,¹³ and posterior / anterior face height ratio.¹⁷ Clinical procedures that open the bite and result in increased vertical dimension should be avoided in cases already displaying excessive lower face height.

Skeletal effects of protraction headgear

The most important growth sites in the development of the nasomaxillary complex are the circummaxillary sutures.^{18, 19} These include the frontomaxillary, zygomaticotemporal, zygomaticomaxillary, and the pterygopalatine sutures. These sutures are situated parallel to each other and are oriented so they project downward. Growth at these sutures has the effect of shifting the maxillary complex downward and forward (Fig 4).

Animal and skull studies^{20, 21} using maxillary protraction devices show significant anterior displacement of the maxillary complex and significant changes in the circummaxillary sutures and maxillary tuberosity. Tension produced within the sutures causes an increase in vascularity and a concomitant differentiation of the cellular tissue resulting in increased osteoblastic activity. While recognizing the limitations of skull studies, it is reasonable to conclude that maxillary protraction appliances have their primary skeletal effect at the midfacial sutural growth sites.

During the use of conventional maxillary protraction appliances, clinicians have observed extrusion and anterior rotation of anchor teeth, downward movement of the maxilla, anterior movement of the maxilla, anterior (counterclockwise) rotation of the maxilla, and a constriction of the anterior region of the maxilla.²⁰⁻²⁴ Anterior maxillary

rotation is the result of downward movement of the posterior nasal spine. The center of resistance of the maxillary complex has been estimated to be positioned between the maxillary first and second premolar sagittally, and between the lower margin of the orbit and the distal apex of the maxillary permanent first molar vertically.²⁴

Conventional protraction headgear devices use elastics stretched between some point of attachment on the maxillary teeth and the headgear. For patient comfort the elastics must come out of the mouth without distorting the lips, which limits the clinicians' control of the direction of force application. Because the elastics' protraction force is applied at a distance below the center of resistance, the maxillary complex is subjected to a forward and downward force as well as a counterclockwise rotational force. (Fig 5) Other changes that have been observed with conventional protraction headgear include a posterior (clockwise) rotation of the mandible, increased anterior face height and increased facial convexity.²⁷ Most of the mandibular changes can be attributed to increased downward growth of the maxilla. The protraction headgear does, however, transfer part of the reciprocal force to the mandible, and it has been shown that stress trajectories do concentrate along the ramus and condylar neck of the mandible.²⁸ Other less widely used protraction headgear have been designed to overcome this problem by using a complex facebow attachment mechanism.^{25, 26}

Clinical studies indicate that the maxilla can be advanced 2-4 mm over a 12- to 15-month period of treatment with a protraction headgear worn 14 hr per day.^{22-24, 27} The amount of anterior maxillary movement is larger in younger patients (under 9 years of age).²⁴ Although long-term follow-up studies are not available, it is reasonable to assume the maxillary changes are relatively stable. The long-term stability of midpalatal suture expansion is well documented and the histologic effect on the circummaxillary sutures with protraction headgear is very similar. When relapse is observed it is likely due to an increase in mandibular protrusion.²⁷

Clinical applications and treatment considerations

Case selection

Patients selected for protraction headgear treatment should have a retrusive maxilla with a normal or mildly protrusive mandible and inadequate or normal maxillary vertical development. Cases presenting with excessive incisor display, anterior open bite, or excessive lower face height should not be treated with protraction headgear.

Palatal expansion

Very often patients presenting with Class III skeletal malocclusions have bilateral posterior crossbites due to deficient transverse maxillary growth combined with the abnormal sagittal relationship of the maxilla and mandible. Maxillary expansion prior to protraction, as well as addressing the transverse discrepancy, has the added benefit of initiating downward²⁹ and perhaps forward move-

ment of the maxilla.³⁰ Palatal expansion affects not only the intermaxillary suture system, but the entire circum-maxillary suture system.³¹ Palatal expansion initiates cellular response in the sutures, allowing a more positive reaction to protraction force.

Palatal expansion should be started with a fixed rapid palatal expansion appliance (hyrax) at least 7–10 days prior to initiating protraction force. The hyrax expansion appliance should be activated by turning the jack screw 1/4 turn daily, resulting in 1-mm palatal width increase every four days.³⁰ The length of preprotraction expansion will depend on the severity of the posterior transverse discrepancy.

A .045" wire is soldered to the buccal aspect of the hyrax expansion appliance. The wires should extend forward into the cuspid region and be bent into a hook to attach the extraoral elastics to the protraction headgear (Fig 6).

Headgear adjustment

The headgear pads should be adjusted to comfortably contact the forehead and chin, and the elastics should be directed with a slightly downward force (Fig 7). The direction of the elastic force can be modified slightly depending on the degree of anterior maxillary rotation versus bite opening that is desired. More horizontally directed force will reduce the amount of bite opening but increase the rotational effect (Fig 5). Excessive pressure from the superior edge of the chin cup may cause labial gingival recession.

Application of force should begin with light elastics (100–150 gm per side) until the patient has adapted to the appliance, then the force should be increased to 300–500 gm per side. The elastics should be replaced daily.

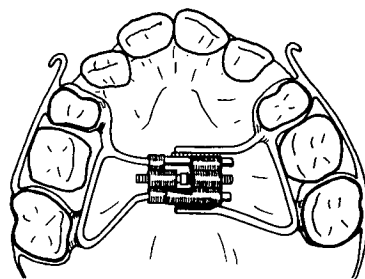
Treatment timing

Protraction headgear has been shown to be most effective in the full primary or early transitional dentition, with considerably less skeletal change after 9 years of age.²⁴ It is also important to initiate treatment early enough so that adequate root structure is still present on the primary first molars to anchor the expansion appliance.

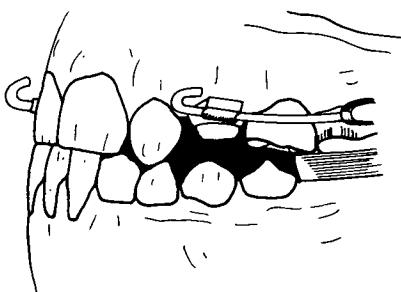
Depending on the severity of the problem and the age of the patient, wearing the appliance 24 hr/day will usually correct the problem within 4 to 8 months. The same result can be achieved with 14-hr/day wear over a period of 12 to 16 months.

Patient recall

The patient should be seen approximately one week after appliance insertion to evaluate patient compliance and to ensure that the appliance is properly adjusted. The patient can be evaluated at regular 4- to 6-week intervals



(a)



(b)

Fig 6. Modified hyrax expansion appliance.

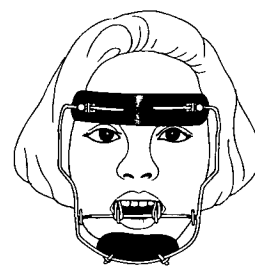


Fig 7. Protraction headgear.

to monitor progress. The overjet should be overcorrected and the protraction headgear continued at nights for 4 to 6 months depending on the patient's tendency to relapse. Full banded orthodontic therapy will be required following Phase I orthopedic correction. The protraction headgear may be necessary during Phase II to help control disproportionate growth between the maxilla and mandible during the prepubertal growth spurt.

ing the prepubertal growth spurt.

Patient motivation

Patient compliance is critical to successful treatment. Positive reinforcement using a series of short- and long-term goals is vital. Praise and rewards are most effective when developed together with the patient, and awarded upon the attainment of each goal. Contacting the child's teacher to explain the nature of the problem and the objectives of the protraction headgear appliance is helpful.³² The teacher can then explain the situation to the child's class, helping to eliminate negative peer pressure at school.

Conclusion

Protraction headgear is a very useful and effective means of treating young patients presenting with a Class III skeletal pattern. Patients should exhibit a retrusive maxilla and should not exhibit excessive vertical development or anterior open bite. Assuming these diagnostic criteria are carefully observed, this treatment technique will produce consistent results. The appliance mechanics are relatively simple and can be managed effectively by pediatric dentists experienced in orthodontic diagnostic procedures. This treatment approach should be considered and, when appropriate, offered to the patient and parents.

Dr. Major is an associate professor and chairman of the Division of Orthodontics, Faculty of Dentistry, University of Alberta. Dr. ElBadrawy is a professor and chairman of the Division of Pediatric Dentistry, Faculty of Dentistry, University of Alberta.

1. Harle GD: The prevalence of malocclusion in grade eight children in Edmonton. MSc Thesis, 1976.
2. Ishii H, Morita S, Takeuchi Y, Nakamura S: Treatment effect of combined maxillary protraction and chin cap appliance in severe skeletal Class III cases. *Am J Orthod Dentofacial Orthop* 92:304-12, 1987.
3. Mitani H, Fukazawa H: Effects of chin cap force on the timing and amount of mandibular growth associated with anterior reversed occlusion (Class III malocclusion) during puberty. *Am J Orthod Dentofacial Orthop* 90:454-63, 1986.
4. Ritucci R, Nanda R: The effect of chin cup therapy on the growth and development of the cranial base and midface. *Am J Orthod Dentofacial Orthop* 90:475-83, 1986.
5. Sugawara J, Asano T, Endo N, Mitani H: Long-term effects of chin cap therapy on skeletal profile in mandibular prognathism. *Am J Orthod Dentofacial Orthop* 98:127-33, 1990.
6. Wyatt WE: Preventing adverse effects on the temporomandibular joint through orthodontic treatment. *Am J Orthod Dentofacial Orthop* 91:493-99, 1987.
7. Ellis E III, McNamara JA Jr: Components of adult Class III malocclusion. *J Oral Maxillofac Surg* 42:295-305, 1984.
8. Guyer EC, Ellis E III, McNamara JA Jr, Behrents RG: Components of Class III malocclusion in juveniles and adolescents. *Angle Orthod* 56:7-30, 1986.
9. Sue GI, Chaconas SJ, Turley PK, Itoh JK: Indicators of skeletal Class III growth. *J Dent Res* 66:348, (Abstr 1932) 1987.
10. Binder RE: The geometry of cephalometrics. *J Clin Orthod* 13:258-63, 1979.
11. Jacobson A: The "Wits" appraisal of jaw disharmony. *Am J Orthod* 67:125-38, 1975.
12. McNamara JA Jr: A method of cephalometric evaluation. *Am J Orthod* 86:449-69, 1984.
13. Ricketts RM: Perspectives in the clinical application of cephalometrics: the first fifty years. *Angle Orthod* 51:115-50, 1981.
14. Powell N, Humphreys B: Proportions of the Aesthetic Face. New York: Thieme-Stratton Inc, 1984.
15. Nanda SK: Patterns of vertical growth in the face. *Am J Orthod Dentofacial Orthop* 93:103-16, 1988.
16. Solow B, Houston WJB: Mandibular rotations: concepts and terminology. *Eur J Orthod* 10:177-79, 1988.
17. Siriwat PP, Jarabak JR: Malocclusion and facial morphology. Is there a relationship? An epidemiologic study. *Angle Orthod* 55:127-38, 1985.
18. Ranly DM: A synopsis of Craniofacial Growth: 2nd ED, Norwalk, CT: Appleton & Lange, 1988.
19. Enlow DH: Handbook of Facial Growth. 2nd ED. Philadelphia: WB Saunders Co, 1982.
20. Hata S, Itoh T, Nakagawa M, Kamogashira K, Ichikawa K, Matsumoto M, Chaconas S: Biomechanical effects of maxillary protraction on the craniofacial complex. *Am J Orthod Dentofacial Orthop* 91:305-11, 1987.
21. Tanne K, Sakuda M: Biomechanical and clinical changes of the craniofacial complex from orthopedic maxillary protraction. *Angle Orthod* 61:145-52, 1991.
22. Mermigos J, Full CA, Andreasen G: Protraction of the maxillofacial complex. *Am J Orthod Dentofacial Orthop* 98:47-55, 1990.
23. Cozzani G: Extraoral traction and Class III treatment. *Am J Orthod* 80:638-50, 1981.
24. Sakamoto T: Effective timing for the application of orthopedic force in the skeletal Class III malocclusion. *Am J Orthod* 80:411-16, 1981.
25. Nanda R: Biomechanical and clinical considerations of a modified protraction headgear. *Am J Orthod* 78: 125-39, 1980.
26. Stagers JA, Germane N, Legan HL: Clinical considerations in the use of protraction headgear. *J Clin Orthod* 26:87-91, 1992.
27. Wisth PJ, Tritrapunt A, Rygh P, Bøe OE, Norderval K: The effect of maxillary protraction on front occlusion and facial morphology. *Acta Odontol Scand* 45:227-37.
28. de Alba y Levy JA, Caputo AA, Chaconas SJ: Effects of orthodontic intermaxillary Class III mechanics on craniofacial structures Part I — Photoelastic analysis. *Angle Orthod* 49:21-8, 1979.
29. Haas AJ: Palatal expansion: Just the beginning of dentofacial orthopedics. *Am J Orthod* 57:219-55, 1970.
30. Bell RA: A review of maxillary expansion in relation to rate of expansion and patient's age. *Am J Orthod* 81:32-7, 1982.
31. Silva OG, Boas MCV, Capelozza L: Rapid maxillary expansion in the primary and mixed dentitions: A cephalometric evaluation. *J Am Orthod Dentofacial Orthop* 100:171-81, 1991.
32. Turley PK: Orthopedic correction of Class III malocclusion with palatal expansion and custom protraction headgear. *J Clin Orthod* 22:314-25, 1988.