



## White sponge nevus: case report

Mauricio Marcushamer, DDS David L. King, DDS, PhD Stan McGuff, DDS

**W**hite sponge nevus (WSN) is a rare oral mucosal lesion first described by Cannon in 1935,<sup>1</sup> characterized as benign leukokeratotic lesion of early onset with periods of remission and exacerbation. It is usually asymptomatic, although pruritus, burning, and pain have been reported following irritating stimuli.<sup>5,7</sup>

WSN is inherited as an autosomal dominant trait with wide variability of expression and high penetrance.<sup>2</sup> Instances of *de novo* mutations also have been reported.<sup>2,4,5</sup>

WSN resembles a gray-white spongy plaque, which in full expression may be thick and deeply folded. It most frequently affects the oral mucosa, although the vagina and rectum also may be involved.<sup>3</sup> Histologically, the lesion is confined to the epithelial layer, which appears parakeratotic and acanthotic with pyknotic cell nuclei. Cellular vacuolization may affect all layers of the epithelium or be distributed irregularly.<sup>3,4</sup> The basement membrane remains intact, although a mild inflammatory reaction may be present in the submucosa. This finding aids in differentiating this lesion from leukoplakia or lichen planus.<sup>8</sup>

Differential diagnosis should include pachyonychia congenita, dyskeratosis congenita, hereditary benign intraepithelial dyskeratosis, keratosis follicularis,

ichthyosiform dermatoses, hypertrophic lichen planus, leukoplakia, and traumatic keratoses.

### Case report

Five female siblings accompanied by their mother came to the pediatric dental clinic at The University of Texas Health Science Center at San Antonio to obtain dental treatment.

On examination, three of the five sisters were noted to have a gray-white plaque affecting their buccal mucosae. The condition was most pronounced on the oldest child (10 years old) who related cyclical periods of remission and exacerbation and severe periods when the lesion would "burn and itch" (Fig 1). The other affected sisters, ages 5 and 3 years, had more moderate and asymptomatic involvement. In all three, lesions affected the oral mucosa bilaterally and had been present since birth. The mother reported that the affected siblings were prone to vaginal yeast infections. Two sisters, ages 8 and 1 were unaffected.

The mother's oral cavity was negative for WSN, but she revealed that the children's father had been examined 18 years ago and a biopsy obtained by the oral pathology division confirmed a diagnosis of WSN (Figs 2 and 3). The girls were biopsied because the clinical findings were consistent with WSN and there was a

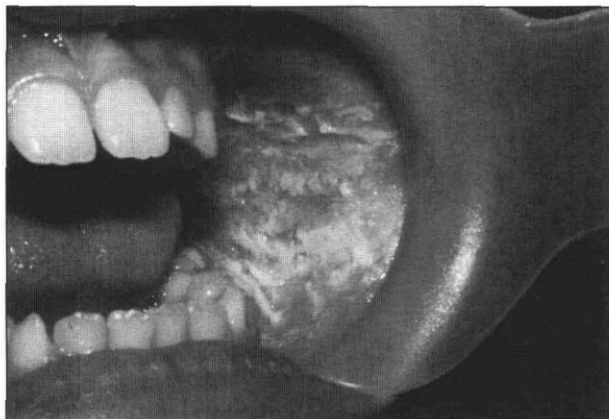
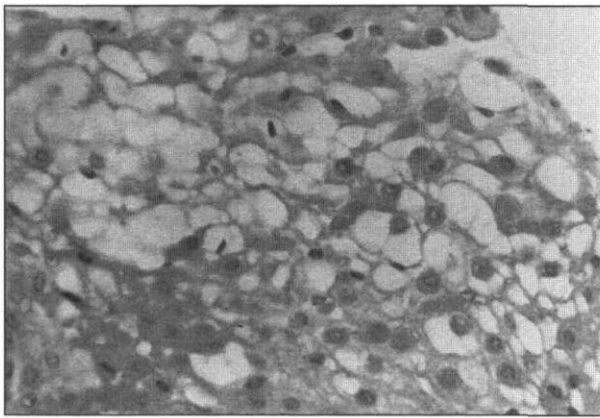


Fig 1. Intraoral photograph showing lesion extent on the patient's left side.

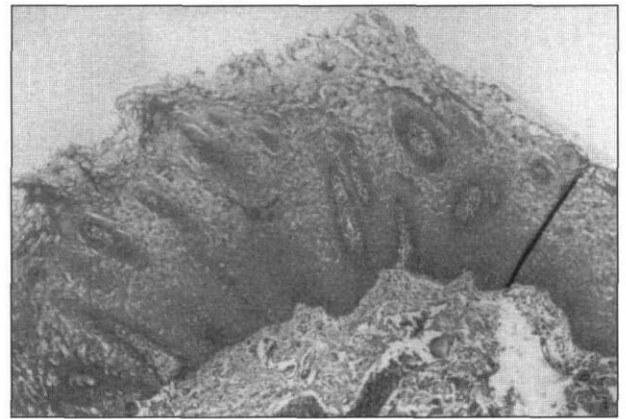

Fig 2. Mucosal fragments that display prominent epithelial thickening with acanthosis and hyperparakeratosis.



**Fig 3. Mild basilar reserve cell hyperplasia, mild spongiosis, intracellular edema with cytoplasmic vacuolization, and perinuclear eosinophilic cytoplasmic condensation.**

high probability that they were affected through paternal transmission. Our diagnosis was communicated to the family physician. All five siblings became patients of record at our clinic for routine dental care and periodic reexamination.

## Discussion

White sponge nevus can affect the nasal, vulvar, vaginal, anal, and penile mucosae.<sup>1, 2, 5, 7</sup> Because of its early onset and asymptomatic presence, a dentist is likely to first discover WSN. To differentiate it from

other white lesions of the oral mucosa, a biopsy is indicated, except in instances where parental transmission of WSN can be clearly established.

There is no known effective treatment for WSN.<sup>6</sup> Rarely, symptoms in the form of itching or burning may occur secondary to bacterial or yeast infections occurring within the infoldings of the lesion. Because the lesions are generally asymptomatic and not known to be premalignant, no compelling need for treatment exists.

Dr. Marcushamer and Dr. King are faculty in the department of pediatric dentistry, and Dr. McGuff is faculty in the department of pathology, all at The University of Texas, Health Science Center at San Antonio.

1. Cannon AB: White sponge nevus of the mucosa (naevus spongiosus albus mucosae). *Arch Dermatol Syphilol* 31:365-70, 1935.
2. Jorgenson RJ, Levin LS: White sponge nevus. *Arch Dermatol* 117: 73-76, 1981.
3. Archard HO: Stomatologic manifestations of internal and integumental disorders. In: *Dermatology in General Medicine*, Fitzpatrick TB, Arndt KA, Clark WH, et al, Eds: New York: McGraw-Hill Book Co, 1971, pp 915-16.
4. Cooke BED: Keratinizing lesions affecting the oral mucosa. *Proc R Soc Med* 60:819-22, 1967.
5. Búchholz F, Schubert C, Lehmann-Willenbrock E: White sponge nevus of the vulva. *Int J Gynaecol Obstet* 23:505-7, 1985.
6. Miller CS, Craig RM Jr: White corrugated mucosa. *J Am Dent Assoc* 117:345-46, 1988.
7. Zegarelli EV, Kutscher AH: Familial white folded hypertrophy of the mucous membranes: report of three cases. *Oral Surg Oral Med Oral Path* 10:262-70, 1957.
8. Gardner AF: White sponge nevus in the oral regions. *J Prosthet Dent* 18:39-45, 1967.

## From the Archives

### Culpable maternal neglect with tragic consequences!

NINETEENTH CENTURY MOTHERS WERE FREQUENTLY BLAMED FOR IGNORING THE LEADING CAUSE OF INFANT MORTALITY — TEETHING

The *Cambridge Chronicle* for December 24 contains a notice of an inquest held respecting the death of a child, aged 15 months, due, according to the evidence of the medical man, to dentition. The facts of the case are briefly as follows: The mother noticed that the child became ill on the previous Saturday, and as the symptoms continued to become worse she went for the doctor on Tuesday, but the child died

before she returned. The medical man in his evidence stated the post-mortem examination showed that the child had been well nourished and that all the organs were particularly healthy. Teething had set up irritation of the gums and caused convulsions, from which the child died. He stated that medical assistance should have been called in earlier, for if the gums had been lanced in the afternoon, the child's life might probably have been saved.

from *Journal of the British Dental Association*, 1897