



Cryosurgery in the management of mucoceles in children

Mauricio Marcushamer, DDS David L. King, DDS, PhD Norma S. Ruano, DDS

The retention of mucous secretions in subepithelial tissue is called a mucous retention phenomenon, which has been subdivided into two types. The first type, the mucous extravasation cyst, lacks an epithelial lining and arises from mucus pooling into the surrounding connective tissue from a torn main duct of a minor salivary gland.¹⁻³ A second type, the mucous retention cyst, is lined by ductal epithelium and results from the accumulation of mucus in an obstructed and dilated excretory duct.

The mucous extravasation cyst is more common³⁻⁶ and occurs most frequently on the lower lip.^{3, 5, 7} This possibly relates to a higher incidence of mechanical trauma to the salivary duct, such as from biting,^{3, 5} although the lesion also can occur on the floor of the mouth, cheek, upper lip, tongue, retromolar fossa, and junction of the hard and soft palate. It presents as an asymptomatic, fluctuant, bluish-gray swelling, usually less than 1 cm in diameter.⁸ Enlargement coincident with meals is an occasional finding. The reported duration of the lesion can vary from a few days to several years, and many patients relate a history of recurrent swelling with periodic rupture and release of fluid. Children and young adults are most frequently affected. Surgical excision is the most frequently recommended treatment for these lesions, but the trauma of this procedure may itself cause recurrence.^{9, 10}

This paper describes the use of cryosurgery to treat mucoceles in six children.

Indications

Six children, three girls and three boys (mean age of 4.8 years, range of 2-8 years), came to the pediatric dental clinic at The University of Texas Health Science Center at San Antonio for dental treatment. During examination all patients manifested an elevated superficial mucous cyst with well-demarcated borders on the lower lip. In five patients, the lesions were translucent and in one patient, bluish-gray (Fig 1). All lesions were asymptomatic. The lesions ranged from 2 to 6 mm in diameter, and lasted from 2 weeks to 3 months in duration. In no case could the type of mucocele (mucous retention cyst versus mucous extravasation cyst) be determined with certainty, but there is no reason to suspect that cryosurgery results would differ as to type of lesion. The medical history was noncontributory in all cases, and consent for treatment was obtained from the patient's parents.

Treatment

Treatment consisted of direct application of liquid nitrogen with a cotton swab without local anesthesia or any sedative agent. Each lesion was exposed directly to eight to 10 consecutive freeze-thaw cycles, each cycle of 5 to 10 sec, beginning at the center of the lesion, then all the borders until the lesion appeared white and frozen (Fig 2). All patients were scheduled for a 1-week, 2-week and 6-month postoperative evaluation.

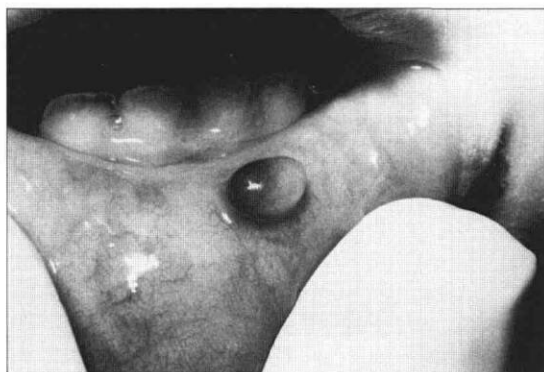

Fig 1. 2-year-old patient with a mucocele in the lower lip.

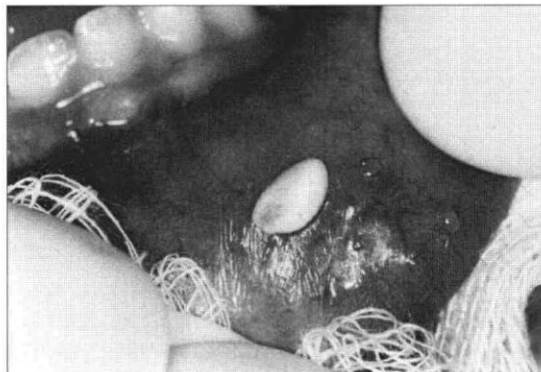


Fig 2. Frozen lesion after eight short freeze-thaw cycles.

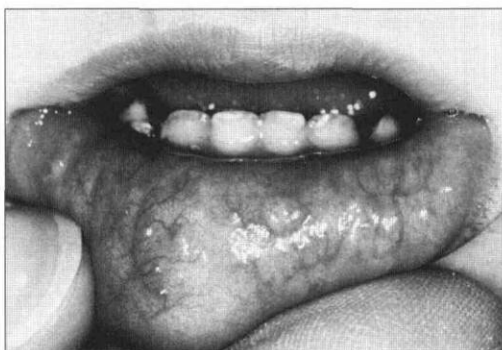

Fig 3. Lesion reduction after 1 week of treatment.

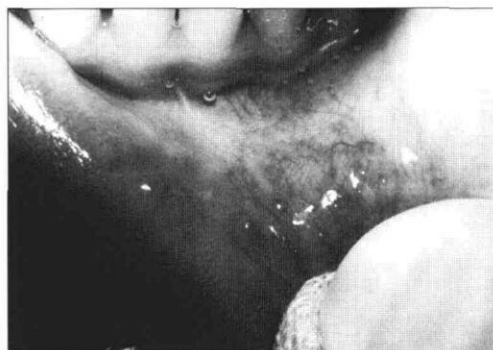

Fig 4. Six months postoperative evaluation.

When a long cycle of 7 to 10 sec was used, some patients reported a slight to moderate burning sensation, but when a 5-sec cycle was used, no pain was reported by any child. During the first 10 min after freezing, mild erythema and swelling was noted. After 1 week all the patients returned to our clinic for evaluation, and in all six cases the mucocele had reduced in size (Fig 3). A secondary application was performed, using the same technique, and the patients returned to the clinic 1 week after for a postoperative evaluation. All the lesions disappeared completely with no evidence of scarring, bleeding, or infection. At the 6-month follow-up visit, no recurrence was noted in any patient (Fig 4).

Discussion

Cryosurgery is a cost-effective, efficacious, and esthetically acceptable modality of therapy for a wide variety of skin disorders.¹¹ A cryogenic agent applied directly or indirectly will cause selective necrosis of tissue, the extent of which depends on the type of lesion and the area to be treated.^{12,13} Some cryogenic agents include liquid nitrogen, carbon dioxide, nitrous oxide, and chlorodifluoromethane. Liquid nitrogen is the cryogen of choice for dermatologic surgery because it is the most versatile and coldest (-196°C). A Thermos™ or a small cup made of rigid polystyrene plastic (Styrofoam™) or metal is useful when the dipstick technique is used.^{14,15} This technique has advantages over surgical excision in that it is easily mastered, painless, effective, and better tolerated by fearful young patients. In our series, the postoperative period showed healing without pain, bleeding, or infection. A disadvantage of cryosurgery is the lack of a specimen to examine microscopically to confirm the diagnosis.

Our experience with this technique agrees with previous reports^{16,17} indicating cryosurgery to be a superior alternative to conventional surgery for mucocele removal.

While it may be impractical for a dental office to keep liquid nitrogen on hand for the sole purpose of mucocele cryosurgery, the small quantity needed on an ad hoc basis may be available from the nearest hospi-

tal, pathology or histology lab, or dermatologist office. It is transportable in Thermos™ or Styrofoam™ containers.

Dr. Marcushamer and Dr. King are faculty in pediatric dentistry and Dr. Ruano is a second-year resident, all in the Department of Pediatric Dentistry, University of Texas Health Science Center at San Antonio.

1. Bhaskar SN, Bolden TE, Weinmann, JP: Pathogenesis of mucoceles. *J D Res* 35:863-74, 1956.
2. Chaudhry AP, Reynolds DH, LaChapelle CF, Vickers RA: Clinical and experimental study of mucocele (retention cysts). *J Dent Res* 39:1253-62, 1960.
3. Cohen L: Mucoceles of the oral cavity. *Oral Surg* 19:365-72, 1965.
4. Poker ID, Hopper C: Salivary extravasation cyst of the tongue. *Br J Oral Maxillofac Surg* 28:176-77, 1990.
5. Harrison JD: Salivary mucoceles. *Oral Surg* 39:268-78, 1975.
6. Yamasoba T, Tamaya N, Syoji M, Fukuta M: Clinicostatistical study of lower lip mucoceles. *Head And Neck* 12:316-20, 1990.
7. Shear M: *Cysts of the Oral Region*. Bristol: John Wright & Sons Ltd. 1976 p 143.
8. Langlais RP, Miller CS: Mucocele. In: *Color Atlas of Common Oral Diseases*. Lea & Febiger, 1992, p32.
9. Bodner L, Tal H: Salivary gland cyst of the oral cavity: clinical observation and surgical management. *Compendium*. 12:150-56, 1991.
10. Poswillo DE: Cryosurgery of benign and orofacial lesions. In: *Cryosurgery of the Maxillofacial Region*. Bradley PF, ed. Boca Raton, FL: CRC Press, Vol. 1. 1986, pp 153-75.
11. Kuflik EG: Cryosurgery updated. *J Am Acad Dermatol*. 31:925-46, 1994.
12. Kuflik EG, Gage AA: Cryosurgery treatment for skin cancer. *New York: Igaku-Shoin*, 35-51, 1990.
13. Zacarian SA: Cryogenics: the cryolesion and the pathogenesis of cryonecrosis. In: *Cryosurgery for skin cancer and cutaneous disorders*. St Louis: CV Mosby Co, 1975, pp 136-59.
14. Dolezal JF: A device to prevent cross-contamination when directly applying liquid nitrogen. *J Dermatol Surg Oncol* 17:827-28, 1991. *Comment* 18: 252, 1992.
15. Jones SK, Darville JM: Transmission of virus particles by cryotherapy and multi-use caustic pencils: a problem to dermatologist? *Br J Dermatol* 121:481-86, 1989.
16. Twetman S, Isaksson S: Cryosurgical treatment of mucocele in children. *Am J Den* 3:175-76, 1990.
17. Toida M, Ishimaru J, Hobo N: A simple cryosurgical method for treatment of oral mucous cysts. *Int J Oral Maxillofac Surg* 22:353-55, 1993.