



Prosthodontic and surgical considerations for pediatric patients requiring maxillectomy

Jack W. Martin, DDS, MS Mark S. Chambers, DMD, MS James C. Lemon, DDS
Béla B. Toth, MS, DDS John F. Helfrick, DDS, MS

Abstract

The quality of treatment and rehabilitation for the head and neck cancer patient, especially the pediatric patient, has progressed markedly over the years due to the cooperation of specialists involved in the total care of the patient. Defects of the oral cavity caused by trauma or removal of malignant or benign tissue require special treatment considerations with the pediatric patient. Aside from radiation and chemotherapy, other forms of adjuvant therapy, such as physical therapy, and patient and family counseling, are needed for proper rehabilitation. In addition, oral hygiene is essential in the overall rehabilitative process. Pediatric dental, orthodontic, prosthodontic, and oral and maxillofacial surgery specialties become integrated in treating the pediatric patient. The concentrated multidisciplinary treatment reduces post-treatment morbidity by shortening recovery and immediate rehabilitation time and by providing long-term care during the critical growth period. (Pediatr Dent 17:116–21, 1995)

head and neck tumors of the maxillofacial region. In such diseases, the principal treatment option is surgical resection of the maxilla (maxillectomy), which may produce pronounced deficits and cosmetic deformities. Consequently, when a maxillectomy is required for treating benign or malignant disease, the maxillofacial prosthodontist must be included in the assessment of the patient prior to surgery. Many articles describe the surgical and prosthodontic management of the adult maxillectomy patient, but little information exists about management of the pediatric maxillectomy patient. This article discusses preoperative evaluation, and surgical and prosthodontic considerations of children diagnosed with maxillary cancer or benign disease. Postsurgical care and growth considerations also are presented.

Presurgical prosthodontic considerations

A prosthodontist's presurgical evaluation of the pediatric patient should include an examination of hard and soft tissues, and a review of medical and dental

Though most malignancies occur in the sixth to seventh decades of life, cancer frequency in children is increasing at an alarming rate.¹ In the US and most economically advantaged nations, cancer kills more children over age 6 months than does any other disease.¹ In 1974, 12 children (0–14 years of age) per 100,000 were diagnosed with cancer. By 1990, the incidence increased to 14 children per 100,000.¹ Moreover, the American Cancer Society estimates that in 1994, 7,600 children in the US under the age of 14 will die of cancer.²

One of the many types of malignancies affecting children is head and neck cancer. Of particular concern to the pediatric dentist would be

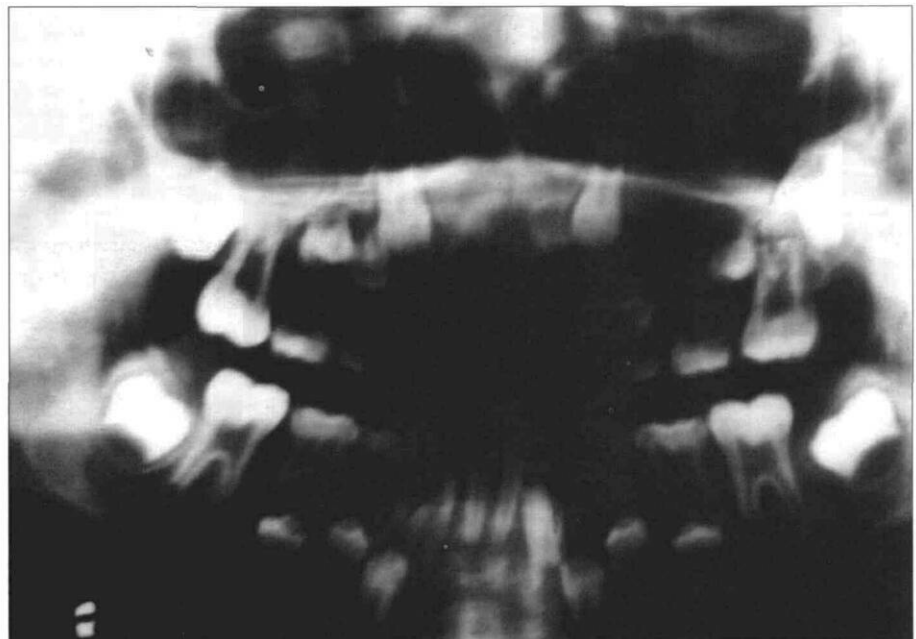


Fig 1. Preoperative panoramic radiograph of pediatric patient scheduled for a maxillectomy procedure. Tumor involving left maxillary sinus and hard palate. Patient is in mixed dentition stage. Evaluation of this patient should include pediatric dental consult.

history including panoramic, occlusal, and selected periapical radiographs. These radiographs not only will indicate the position of the permanent tooth successors, but are useful in diagnosing and treatment planning the maxillectomy procedure. Initial incisions can then be placed without damaging uninvolved tooth buds. A pediatric dentist also should be consulted as

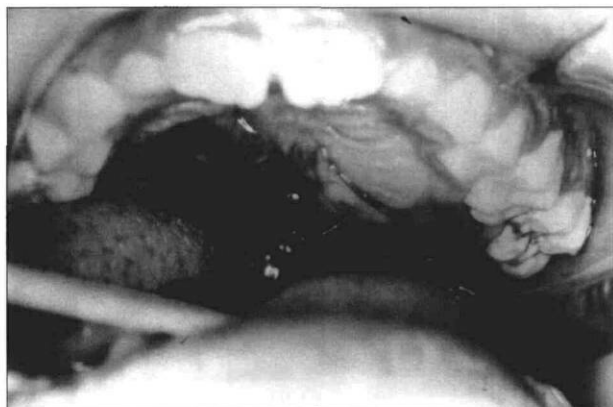


Fig 2. Tumor involving the left maxillary sinus and hard palate.

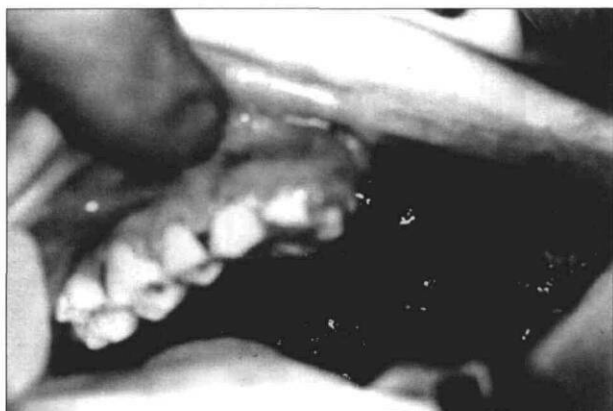

Fig 3. Tumor was surgically removed by an intraoral approach.

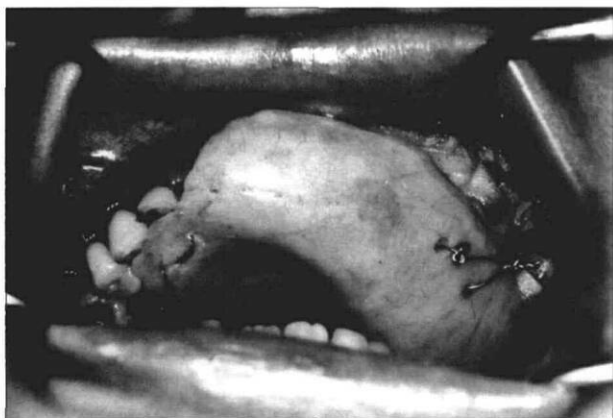


Fig 4. Zygomatic and interdental wires were used to retain the surgical obturator.

part of this assessment when the patient is in the mixed dentition stage to help determine which teeth will be suitable for clasping during the various phases of prosthetic rehabilitation (Figs 1 and 2). At this stage, preliminary impressions of the maxilla and mandible should be made and poured in stone to obtain diagnostic casts. A surgical obturator is fabricated to restore the contour of the palate and seal the margins of the intraoral surgical defect.

Parental information prior to surgery

It is advisable to inform the parents or guardian as well as the patient (according to the patient's maturity and ability to understand) that there will be four critical stages:

1. Surgery
2. Surgical packing removal
3. Interim
4. Definitive rehabilitation (Figs 3 and 4).

The parent should be informed of the required presurgical and postsurgical prosthodontic procedures. The problems associated with a maxillectomy, including difficulties in speech and swallowing, revisions of the surgical obturator prosthesis, and requirements for follow-up visits during the interim obturator stage, should be discussed with the patient and parents.^{3,4} This information should be discussed before surgery and again before surgical pack removal; specifically, problems that will be associated with speech and swallowing. Parents should be informed that general anesthesia or intravenous sedation may be necessary for pack removal and interim obturation procedures. During the first 2 to 3 weeks after pack removal, several office visits will be required for revision of the interim obturator to accommodate healing. Initially, the patient and parents should expect some leakage of liquids and air around the bulb portion of the obturator prosthesis. This leakage may cause hypernasal speech and regurgitation of food and fluids through the nose. Depending on the extent of surgery, the clinician can anticipate these problems and discuss them more appropriately after the surgical procedure.⁵

Parents should be informed that adjuvant therapy such as physiotherapy may be needed to resist a decrease in mouth opening and assist in eliminating harmful habitual oral habits. Decreased oral opening, loss of innervation, and facial deformity secondary to a maxillectomy procedure will depend on the extent of surgery and adjunctive treatments such as radiation and chemotherapy. Parents should also be counseled on their participation in oral hygiene and examining the surgical defect. This parental examination can assist the surgeon and dentist in early detection, treatment, and even prevention of a number of problems, including: decreased oral opening, poor oral hygiene, ill-fitting prosthesis, and, most important, recurrent disease.

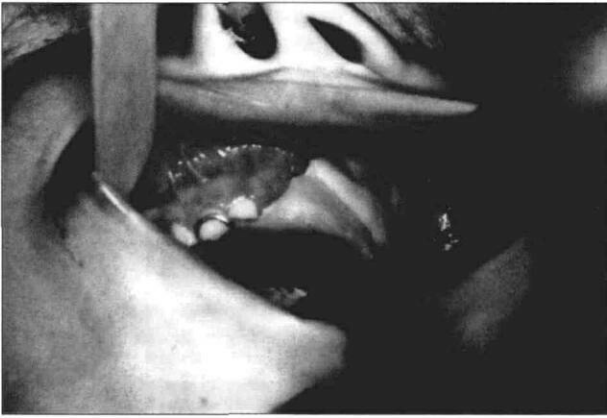

Fig 5. General anesthesia or intravenous sedation may be necessary for pack removal. The surgical obturator is revised to seal the surgical defect with a soft-tissue conditioning material. This now becomes the interim obturator during the initial healing phase.

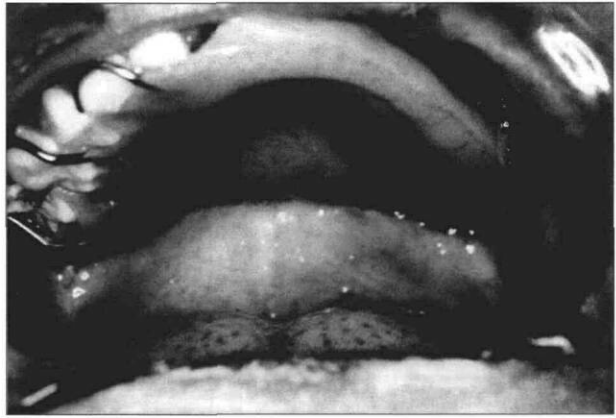


Fig 6. Interim obturator is transformed to an all-acrylic prosthesis 8 weeks postoperatively. Note the light-cured restorations on the buccal and labial surfaces of the remaining maxillary abutment teeth, which provide retentive undercuts for the clasp.

It is important to inform the parents of potential occlusion problems associated with this procedure and the possible need for orthodontic consultation. Loss of primary teeth and normal skeletal growth may necessitate several revisions or remakes of the obturator prosthesis. Growth of the facial structures and jaws may be altered because of the disruption of the growth centers by the ablative procedure. Furthermore, forces placed on the maxillary teeth and maxilla by the obturator prosthesis could affect growth and cause malocclusion.⁶⁻⁹ Patients who need or desire postmaxillectomy orthodontic therapy need to coordinate this treatment between the orthodontist and prosthodontist. Orthodontic banding may interfere with routine clasp designs used in obturator prosthesis fabrication. Innovative clasp designs may be necessary to provide retention to the obturator prosthesis.

These suggestions are by no means exclusive, but are a summary of preliminary information that should be discussed with the patient and family prior to a maxillectomy. Too much information may cause the patient and family undue concern during a very stressful time, so judicious explanation of the pertinent issues should be tailored to fit each family. Medical questions and information about the diagnosis and prognosis of the disease should be directed to the surgeon in charge of the patient's treatment.

The need for psychological consultation with the patient and family should be considered both before and after the surgical procedure. Usually the family is unaware of the significance of the postoperative problems until pack removal and interim obturation¹⁰ (Figs 5 and 6). Psychological counseling may ease the recovery process and allow the child to accept the procedure and adjust to the prosthesis. Providing expert physical care that fosters feelings of safety and security is the most fundamental method of meeting the child's emotional needs.¹¹

Because of the ethical and procedural difficulties inherent in such studies, research is limited on the communication needs of children with cancer.^{11, 12} Waechter's¹³ research, conducted at a time when health care providers and parents thought that these children could not comprehend the gravity of their situation, revealed that the children did realize the seriousness of their illnesses. They were anxious about the secrecy surrounding them and wanted more communication. Most importantly, children with systemic disease and their families have insight and wisdom valuable to health professionals.

Presurgical planning

The surgeon and prosthodontist should discuss the sequence of treatment prior to surgery. If the patient requires a general anesthetic for exploration and biopsy as part of the assessment, then the oral examination, and the impressions, can be done at the same time to expedite treatment. This is especially helpful in uncooperative patients. During this biopsy procedure, the retentive undercuts are evaluated. Undercuts in the primary dentition usually are not found in this age group, but can be placed with light-cured retentive restorations or orthodontic brackets to retain an obturator prosthesis. Retentive undercuts should be placed on the buccal surface of selected posterior and anterior teeth prior to the impression procedure.

The maxillary and mandibular impressions should be poured in stone for master casts, which are mounted on an articulator and evaluated by the treatment team. The maxillary cast can be modified to reflect the anticipated surgical defect. A surgical obturator can then be fabricated on this cast. The surgeon is not bound by presurgical prosthetic planning, because of the unpredictable nature of tumor margins. In lieu of this, the prosthodontist should make every effort to anticipate changes and adjustments to the planned prosthesis at

the time of the ablative procedure. Duplicating the maxillary cast may help allow revision of the prosthesis if more or less supporting tissues are removed during surgery.

The laboratory procedures used to fabricate a surgical obturator for a pediatric patient are essentially the same as for the adult. The obturator protects the surgical wound and acts as a stent to hold the surgical packing in place against the skin graft. Furthermore, it provides oral competence, eliminating the need for a nasogastric tube. Denture teeth for the pediatric obturator prosthesis may be selected from a manufactured mold or be custom made by a sprinkle-on technique, as described by King.¹⁴ Holes are drilled strategically into the surgical prosthesis for interdental wiring of the obturator. Since primary teeth are conical and diastemas are common, other means of fixation include zygomatic or nasal spine wires to help retain the obturator. Fixing the obturator to bone with bone screws should be a last resort in pediatric patients, because when used in the alveolar region, this procedure can damage the remaining permanent tooth buds.

Oral hygiene

Oral hygiene is one of the most important aspects of postoperative care and cannot be overstressed to the patient. Initially, the patient — with parental observation and guidance — should rinse with a saline solution (1 tsp salt/1 tsp soda dissolved in 16 oz of water) three times a day. A commercial irrigation system can be used as part of this regimen. The entire surgical defect should be cleansed. Tooth brushing and flossing should begin as soon as the surgical packing has been removed. The patient and parents may be apprehensive about resuming normal oral hygiene for fear of injuring the surgical site, and this fear must be addressed to lessen psychological stress. If the patient is receiving chemotherapy, hematological values should be monitored prior to resuming normal oral hygiene procedures. When the platelet count remains at or above 50,000/mm³, the coagulation profile is within normal limits, and the absolute phagocyte count is above 500/mm³, routine oral care can be resumed. Rinsing with commercial mouthwashes is not recommended during the initial healing phase because these products usually contain alcohol or phenol, which can irritate the mucosa.

At the fourth week of healing, a solution of 3% hydrogen peroxide, diluted 1:1 with water, can be added to the routine. This mixture used prior to rinsing with the salt and soda solution can help loosen and remove dried mucous crust and desquamated debris in the surgical defect. A 4x4-cm gauze or wash cloth dampened in the peroxide solution can be wrapped around the index finger and used to clean the skin-grafted portion of the defect. Ora-Swab® brushes (Sage Inc, Crystal Lake, IL), which are sponge-tipped applicators, may also be used for this purpose. The patient

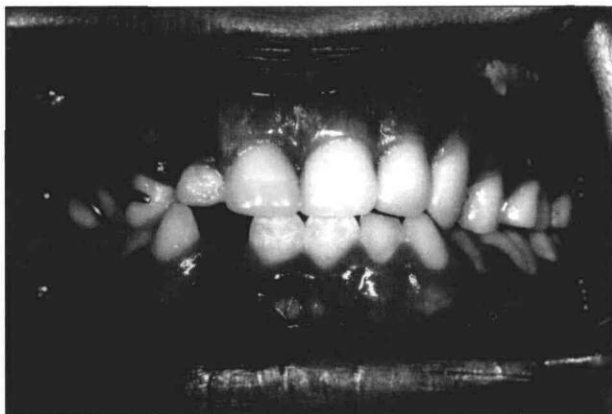should be instructed to lean over a sink during irrigation to allow the fluid to pass out of the mouth and nasal cavity and into the receptacle. The possibility of aspirating the solution is an initial concern, but patients quickly learn to protect their airways. The patient should be instructed to brush and floss prior to cleaning the defect. In addition, the parents must be taught to inspect the defect after each session, to help ensure adequate hygiene and optimal health.^{15,16}

Physical therapy

Decreased oral opening, loss of innervation, and facial deformity secondary to a maxillectomy will depend on the extent of surgery and adjunctive treatments such as radiation and chemotherapy. If the maxillectomy is confined to the alveolus and hard palate, and if the procedure is accomplished intraorally, the postoperative manipulations such as obturator revisions and oral care will be accomplished with relative ease. However, if the maxillectomy involves a Weber-Ferguson incision and the resection is extended to include the orbit, zygoma, and pterygoid muscles, the resulting decreased oral opening and facial deformity can be severe, and rigorous physical therapy is usually required.

Exercises designed to increase oral opening should be initiated as soon as the patient can tolerate therapy — usually one week after the surgical obturator and packing are removed. When the patient is dentate, tongue blades can be inserted between the posterior teeth until the opening limit is obtained. The oral opening is then increased by inserting one tongue blade at a time between those already in place. With each additional tongue blade, opening is increased and the position is held for several minutes to allow the scar tissue to stretch. Tongue blades are added until a pain threshold is reached. Several mouth opening devices, such as a dynamic bite opener and a threaded screw-type appliance, have been discussed in previous articles^{17,18} and can be custom made for each patient. The details in design or adaptation of these devices can make them more appealing for the pediatric patient. One commercial device, the Therabite® mouth opener (Therabite Corp, Bryn Mawr, PA), operates similar to a car jack to open the mouth and can be custom fitted so that the forces on the remaining dentition are distributed equally.

No matter what mouth-opening device or technique is used, it is important to include as many teeth as possible in order to distribute the load and reduce the potential for orthodontic movement of the teeth. During the first 4 weeks after surgery, patients should do mouth-opening exercises three to four times a day. They can also stretch the scar band by intraorally massaging the cheek portion of the scar band with digital manipulation. This movement can be combined with extraoral palpation and stretching of the cheek and upper lip, to keep the tissue as pliable as possible.



◀ Fig 7. The removable definitive prosthesis in place. Frequent revisions or remakes could be needed due to growth.



▶ Fig 8. Patient at age 11. Note the position of the upper lip. Surgical correction can alleviate this minor esthetic problem.

More advanced forms of physical therapy, such as auriculotherapy, electrotherapy, ultrasound therapy, and isometric exercises can be rendered by a trained and licensed physical therapist.¹⁹ Measurements obtained during therapy should be recorded to help the clinician and the patient monitor progress. Even with excellent results, physiotherapy should be continued for at least 1 year, and may need to be extended indefinitely. Follow-up appointments with the therapist ensure that the therapeutic routines are being performed correctly and that an acceptable result is attained and maintained.

The prosthodontist should assess the patient thoroughly at each appointment. If a patient complains of oral pain, localized swelling, or a sudden loss of oral opening, the clinician should suspect and then rule out a recurrence of disease. This assessment should be in a combined effort with the physician. When ruling out recurrent disease, keep in mind that infection or poor compliance with physical therapy can cause localized swelling or abrupt loss of oral opening.^{17, 18, 20}

Surgery and reconstruction

During the primary surgical procedure, a Weber-Ferguson incision is commonly used to gain access for the maxillectomy. If the lesion is located primarily anteriorly, this procedure can sometimes be done without splitting the lip, thus reducing external scars. If there is any difficulty with exposure or if the lesion is located laterally or posteriorly, it is vital to change the approach to allow better access to the tumor.³ More complete exposure of the maxilla is obtained by splitting the lip and extending the incisions around the nose up to the orbit and below the lower eyelid.³

The mucosal cuts on the palate are made first and are similar to a palatal resection. The periosteum is elevated and bony cuts are made with an osteotome or oscillating saw. The orbital rim is spared if the orbital contents have not been invaded. The pterygoid plates and the soft tissues of the pterygomaxillary space are resected at the base of the skull using a curved osteotome.³ A split-thickness skin graft is placed under the soft tissue flap to line the surgically pro-

duced cavity.²¹ The wound is packed, the immediate surgical obturator is placed, and the Weber-Ferguson incision is closed.³

The cosmetic aspects of the resection are secondary to the need for adequate surgical exposure. The Weber-Ferguson incision permits the soft tissues over the maxilla to be reflected laterally, ensuring access to the underlying bony structures. Though this type of incision gives the surgeon excellent exposure for resection of the disease, it adds to postoperative disfigurement and decreases oral opening. An intraoral procedure should be considered if the extent of disease is limited. When the initial incision is made through a tooth socket or diastema, extreme care should be taken to remove the involved permanent tooth buds. Consistent with disease removal, the incision should be made as far posteriorly in the palate as possible to spare the premaxilla. The premaxilla preserves facial contours and enhances support and stability of the prosthesis. Sparing the premaxilla further spares the infraorbital nerve with its contributions to the midface.

Split-thickness skin grafts have been very useful as an initial reconstruction measure. These grafts, usually taken from the thigh or buttocks, limit contracture of the surgical wound and decrease crusting, ultimately leading to better hygiene. When placed in the surgical defect, skin grafts allow for proper hygiene and reduce the secretions that normally accumulate in the cavity.²¹ Fortunately, a child's skin is more pliable than an adult's, making contracture less of a problem.

Reconstructing the surgical defect can be considered after the patient's facial growth is completed (Figs 7 and 8). Radiographs of growth centers may help assess the final growth of the individual. Restoring the infraorbital rim and zygomatic complex can restore facial contours and provide future sites for placing dental implants to stabilize and support a prosthesis.

In addition to implants, grafting procedures are an important component in intraoral reconstruction. There are three forms of grafts: nonvascularized grafts, synthetic grafts, and vascularized free tissue transfer. Through microvascular surgery, vascular free tissue transfer (from such sources as the iliac crest and fibula)

has revolutionized surgical techniques and offers many new opportunities for maxillary reconstruction.²²⁻²⁴ Microvascular surgery is a technique used to join an artery and vein from a free tissue transfer flap to an existing artery and vein in the recipient site.²⁴ A free tissue transfer flap composed of bone, muscle, associated soft tissue, and skin can be removed from one part of the body, via microvascular surgery, and used to restore supporting tissues resected during ablative cancer surgery in the head and neck region.²² With this new technique, the reconstruction of the maxilla and placement of dental endosseous implants can improve facial appearance and prosthesis stability. This rehabilitation, following facial growth, should be coordinated with orthodontic and prosthodontic considerations.²⁵⁻²⁸

Summary

The pediatric maxillectomy patient poses special problems for the dentist and surgeon. Prosthodontic and surgical considerations should be discussed with the patient and parents prior to treatment. Orthodontic and pediatric dental consultations should be planned. Oral hygiene and physical therapy techniques are of prime importance to the young patient and can be an essential part of the recovery process. The importance of cooperation between the surgeon and dentist in planning, treatment, and follow-up is crucial to the survival and rehabilitation of the patient. Psychological consultation with the family should be considered both before and after surgery and may be significant in the overall rehabilitation of the patient.

Dr. Martin is professor, dental oncology; Dr. Chambers is fellow, maxillofacial prosthodontics; Dr. Lemon is associate professor of dental oncology; Dr. Toth is associate professor, dental oncology; and Dr. Helfrick is professor of oral and maxillofacial surgery, University of Texas, MD Anderson Cancer Center, Houston.

1. Bleyer WA: The impact of childhood cancer on the United States and the world. In: Murphy GP, Holleb AI, Eds: *Ca-A Cancer Journal for Clinicians*; American Cancer Society, New York, NY, H & W Publishing 40:355-67, 1990.
2. American Cancer Society: *Cancer Facts & Figures* — 1993. Atlanta: American Cancer Society, 1993.
3. Beumer JP, Curtis TA, Firtell DN: Restoration of acquired hard palate defects. In: *Maxillofacial rehabilitation: prosthodontic and surgical considerations*. St Louis: CV Mosby Co, 1979, p 188.
4. Desjardins RP: Early rehabilitative management of the maxillectomy patient. *J Prosthet Dent* 38:311-38, 1977.
5. King GE: Prosthetic rehabilitation of the nasal and paranasal sinus areas. In: *Comprehensive Management of Head and Neck Tumors*, Thawley SE, Panje WR, Eds. Philadelphia: WB Saunders Co, 1986.
6. Jaffe N, Toth BB, Hoar RE, Reid HL, Sullivan MP, McNeese MD: Dental and maxillofacial abnormalities in long term survivors of childhood cancer: effect of treatment with chemotherapy and radiation to head and neck. *Pediatrics* 73:816-23, 1984.

7. Dixon AD: Early development of the maxilla. *Dent Pract* 3:331-36, 1953.
8. Dixon AD: The development of the jaws. *Dent Pract* 9:10-20, 1958.
9. Graber TM: *Orthodontics: Principles and Practice*. Philadelphia: WB Saunders Co, 1972, pp 27-125.
10. Gillis RE, Swenson WM, Laney WR: Psychological factors involved in maxillofacial prosthetics. *J Prosthet Dent* 41:183-88, 1979.
11. van Eys J: Clinical research and clinical care: ethical problems in the "War on Cancer," In: *Human Values in Pediatric Hematology/Oncology*. Truman JT, van Eys J, Pochedly C, Eds. New York: Praeger, 1986, pp 15-22.
12. Moore IM, Ruccione K: Challenges to conducting research with children with cancer. *Oncol Nurs Forum* 16:587-89, 1989.
13. Waechter EH: Children's awareness of fatal illness. *Am J Nurs* 71:1168-72, 1971.
14. King GE, Frame R: A surgical interim prosthesis. *J Prosthet Dent* 45:108-10, 1981.
15. Toth BB, Hoar R: Oral/dental care for the pediatric oncology patient. *Cancer Bull* 34:66-71, 1982.
16. Toth BB, Fleming TJ: Oral/dental considerations for pediatric patients receiving anticancer treatment. *J Mo Dent Assoc* May-June 33-34, 1983.
17. Barrett VJ, Martin JW, Jacob RF, King GE, Sheets JS: Physical therapy techniques in the treatment of the head and neck patient. *J Prosthet Dent* 59:343-46, 1988.
18. Rocabado M, Johnston BE Jr, Blakney MG: Physical therapy and dentistry: an overview. *J Craniomandib Pract* 1:46-49, 1983.
19. King GE, Scheetz J, Jacob RF, Martin JW: Electrotherapy and hyperbaric oxygen: promising treatments for postradiation complications. *J Prosthet Dent* 62:331-34, 1989.
20. Rouse PB: The role of physical therapists in support of maxillofacial patients. *J Prosthet Dent* 24:193-97, 1970.
21. Teichgraeber J, Larson DL, Castaneda O, Martin JW: Skin grafts in intraoral reconstruction: a new stenting method. *Arch Otolaryngol* 110:463, 1984.
22. King GE, Martin JW, Lemon JC, Schusterman MA, Reece GP: Maxillofacial prosthetic rehabilitation combined with plastic and reconstructive surgery. In: *MD Anderson Oncology Case Reports & Review*. Hickey RC, Ed. 8:1-11, 1993.
23. Martin JW, Lemon JC, King GE: Maxillofacial restoration after tumor ablation. In: *Clinics in Plastic Surgery: Head and Neck Reconstruction*. Schusterman MA, Ed. 21:87-96, 1994.
24. Hidalgo DA: Fibula free flap: a new method of mandible reconstruction. *Plast Reconstr Surg* 84:71-79, 1989.
25. King GE, Lemon JC, Martin JW: Multidisciplinary teamwork in the treatment and rehabilitation of the head and neck cancer patient. *Texas Dent J* June:9-12, 1992.
26. Martin JW, Lomba JA, King GE: Maxillofacial prosthetics and oral surgery for the head and neck cancer patient. *Cancer Bull* 34:48, 1982.
27. Martin JW, Lemon JC: Prosthetic rehabilitation. In: *Head and Neck Surgery-Otolaryngology*. Bailey BJ, Ed. Philadelphia: JB Lippincott Co, 1993, pp 1431-38.
28. King GE, Jacob RF, Martin JW, Fleming TJ, Kramer DC, Udagama A: Prosthetic rehabilitation of the nasal and paranasal sinus areas. In: *Comprehensive Management of Head and Neck Tumors, Vol 1*. Thawley SE, Panje WR, Eds. Philadelphia: WB Saunders Co, 1986.