

Tissue response to intralingival appliances in monkeys

Michael J. Mayhew, DDS, MS Gary J. Dilley, DDS, MS, MSD
Diane C.H. Dilley, DDS John Jacoway, DDS, PhD
Phil T. Johnson, DVM, MS

Abstract

*Stainless steel, distal shoe appliances were placed in the dental arches of monkeys to study the soft tissue response surrounding intralingival extensions. Histologic sections of 30 soft tissue specimens from five *Macaca fascicularis* monkeys were examined at 4-, 6-, 8-, and 10-week intervals. Epithelium surrounded the extensions at all time periods. Pathologic findings of the epithelial lining and in the underlying connective tissue should indicate limiting the use of these appliances in patients with systemic illnesses.*

Premature loss of primary molars frequently is accompanied by space loss and resultant malocclusion. The second primary molar provides a most vital link for the normal eruption and positioning of the first permanent molar. Premature loss of a second primary molar prior to the eruption of the first permanent molar requires special consideration for space maintenance therapy.

The distal shoe intralingival space maintainer is one method for preserving the arch space. Since first reported by Willett¹ in the 1930s, this appliance has met with success in guiding first permanent molar eruption. Although widely used, little is known of the tissue response surrounding the intralingival extension of the distal shoe appliance. It has been hypothesized that an epithelial surface covers the connective tissue approximating the intralingival extension and forms a barrier to oral fluids and bacteria. However, there has been little or no evidence of this epithelization. Therefore, the appliance has not been advocated for use in patients with systemic disease because of a possible bacteremia and systemic involvement.²

Kelisek, Binns, and Carrel³ placed intralingival appliances in rabbits and showed epithelium to cover slowly the incised connective tissue after four weeks, allowing resolution of an initial inflammatory re-

sponse. By 8 and 12 weeks, more epithelium was noted, with some chronic inflammation present. By 16 weeks, a response similar to the 4-week specimens was noted with intense inflammation and minimal epithelization. The authors concluded that the appliances did not cause infection of the surrounding tissues, but that tissue injuries or individual responses may have altered the tissues unfavorably. No attempts at a quantitative analysis of tissue components were made.

The purpose of this study was to investigate the cellular tissue response to stainless steel intralingival appliances placed in the dental arches of monkeys.

Methods and Materials

Five *Macaca fascicularis* monkeys at 3.00–4.00 kg body weight and complete permanent dentitions (except third molars) were obtained. All procedures were conducted with the animals sedated with IM ketamine hydrochloride at a dose of 10.0 mg/kg. Local infiltrations of 0.5 cc of 2% Xylocaine^a with 1:100,000 epinephrine also were administered prior to all oral tissue incisions and extractions. Extractions were planned to allow areas for placement of intralingival extensions. Prior to the extractions, alginate impressions of the dental arches were obtained and poured in stone for the indirect laboratory fabrication of the stainless steel appliances. Teeth planned for extraction were ground from the stone models. Orthodontic bands were fitted on adjacent teeth and the appliances were fabricated to represent distal shoe intralingival appliances (Figure 1).

Thirty-two appliances were cemented^b in the dental arches of the monkeys immediately after dental extractions, while four appliances were inserted after extraction sites had healed for two weeks. At pre-

^a Astra Pharmaceutical Products, Inc., Worcester, ME.

^b Durelon polycarboxylate cement, Premier Dental Products Co., Norristown, PA.




FIGURE 1. Schematic illustration of a three-abutment appliance indicating structural components and approximate positioning of stainless steel intragingival extensions.

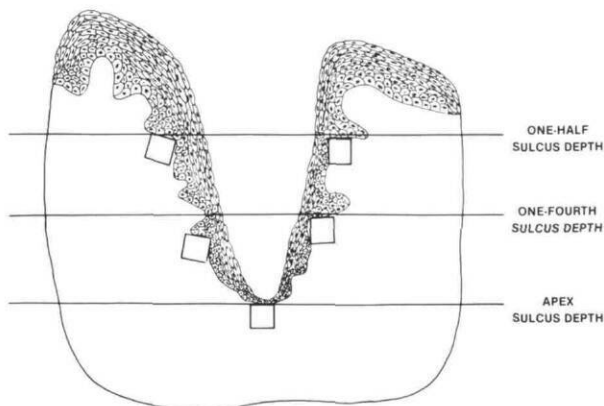


FIGURE 2. Schematic illustration indicating the localization of sampling fields used at three sulcus depths. Two readings each were recorded at the one-half and one-fourth sulcus depths and one at the apex of the sulcus for each section.

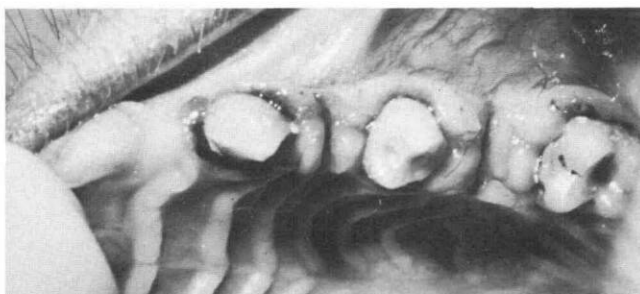

FIGURE 3. Clinical picture following appliance removal.

determined 4-, 6-, 8-, and 10-week intervals, appliances were removed and soft tissue samples from the bony base were obtained. No animals were sacrificed during the study.

The soft tissue specimens were fixed in 10% buffered neutral formalin solution, and then processed and embedded in paraffin for Harris' Hematoxylin and Phloxine Eosin and Gomori's Trichrome staining procedures.⁴ Due to processing errors and premature loss of one appliance, 30 of the potential 36 tissue

Table 1. Comparison of Mean Epithelial Cell Thickness Counts at Three Sulcus Depths at 4, 6, 8, and 10 Weeks*

Location	Week			
	4	6	8	10
One-half	9.52	11.18	10.35	8.17
One-fourth	6.75	8.82	7.47	4.32
Apex	2.05	3.18	3.06	4.05

* Total N = 150 tissue sections.

Table 2. Comparison of Mean Fibroblast Counts at Three Sulcus Depths at 4, 6, 8, and 10 Weeks*

Location	Week			
	4	6	8	10
One-half	9.70	10.63	10.26	10.40
One-fourth	12.22	11.34	10.63	9.52
Apex	12.85	12.49	11.82	12.95

* Total N = 150 tissue sections.

Table 3. Comparison of Histiocytes, Lymphocytes, and Plasma Cells Totaled at Each Site to Provide the Chronic Inflammatory Response at Three Sulcus Depths at 4, 6, 8, and 10 Weeks*

Location	Week			
	4	6	8	10
One-half	4.56	5.13	4.38	4.91
One-fourth	2.83	3.76	3.81	4.17
Apex	2.17	2.35	2.39	2.82

* Total N = 150 tissue sections.

Table 4. Comparison of Mean Polymorphonuclear leucocyte Counts at Three Sulcus Depths at 4, 6, 8, and 10 Weeks*

Location	Week			
	4	6	8	10
One-half	3.30	1.77	1.33	1.17
One-fourth	2.92	1.55	1.26	1.05
Apex	1.80	1.55	1.60	1.00

* Total N = 150 tissue sections.

samples were available for analysis. Five-micron thick sections were cut on a microtome with the tissue oriented in a mesial-distal cross section of the appliance sulcus.

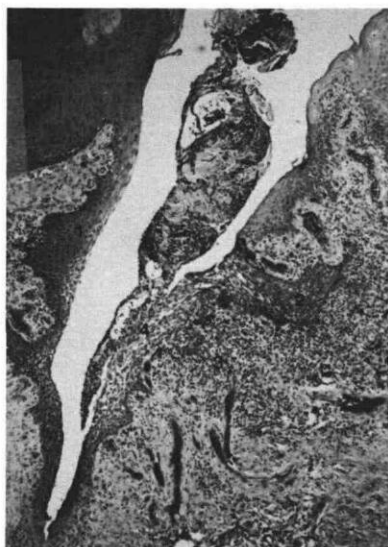Five sections of each sample were examined microscopically for a total of 150 tissue sections. The sections chosen for the study showed the entire extent of the sulcus formed by the extension, were a minimum of 20 μ apart in sequence, and demonstrated no processing artifacts to impede examination. Specific regions of the tissue sulcus to be examined were estimated and selected separately for each specimen. These represented the most apical region of the sul-

cus, and the distance one-fourth and one-half coronal to the apex (Figure 2).

The objectives of microscopic examination were to: (1) determine the integrity and intercellular spacing of the epithelium approximating the extension, and (2) quantitate the cellular components within the adjacent connective tissue. Microscopic examination of epithelial integrity was completed at 200 \times with all quantifications of cellular components determined at 400 \times .

A calibrated ocular grid with 121 intersections per grid covering 100 square microns was used to count the cellular components within the underlying connective tissue which included fibroblasts, epithelial cell thickness, polymorphonuclear leucocytes, histiocytes, lymphocytes, and plasma cells. The counting methods were based on stereologic assessment procedures advocated by Weibel, Kistler, and Scherle⁵ and described in gingival studies by Polson, Kantor,

FIGURE 4. Representative photomicrograph of tissue sulcus at six weeks. Epithelium (1) lines the sulcus with some increase in rete peg proliferation (2). Concentrated areas of inflammatory infiltrate exist (3). Widened intercellular spacing (4) is present representing epithelial breakdown. Hematoxylin and eosin 40 \times .



and Zander,⁶ and Schroeder and Münzel-Pedrazzoli.⁷ A single column of the grid 10.0 μ wide was used to count epithelial cell thickness from the epithelial surface of the basal cell layer.

A final tabulation of mean values resulted in grouping the mean values of each tissue component according to weeks and site analyzed. A descriptive analysis of histological findings then was performed.

Results

Clinical examination of the tissues prior to sampling revealed mild gingival inflammation around all extensions. Gingival hyperplasia was observed surrounding the majority of the stainless steel extensions. Minimal hemorrhage was common within the tissue sulcus for most, but not all, of the appliances upon removal. A typical clinical appearance of the tissue can be noted in Figure 3.

Histologic results of the samples at both 4 and 6

weeks showed that organized, stratified, squamous epithelium covered the exposed connective tissue approximating the stainless steel intragingival extensions (Figure 4). At the 8- and 10-week time intervals ulcerations of the epithelial surface were noted in several specimens. However, all areas of ulceration were seen between the apical and one-fourth sulcus levels. These ulcerated areas were typified by a lack of organized epithelial cells with connective tissue components at the defect surface, localized areas of intense inflammation, and fibrin clots.

Proliferation of rete pegs, generally confined to the more coronal surfaces, were noted extending deep into the connective tissue of all tissue samples. The thickness of the epithelial wall decreased as the analysis progressed from the one-half level to the apical level of the sulcus with minimal changes from weeks 4 through 10 (Table 1).

Areas of normal and widened intercellular spacing of the epithelium were observed in all samples. A direct observation of increased intercellular spacing with increased inflammatory infiltrate in the underlying connective tissue also was made for all samples.

The Gomori's stain, used as a colorimetric determinant for tissue maturation, revealed good maturation of underlying connective tissue for all samples at all time periods. As seen in Table 2, the mean fibroblast counts at the three sulcus levels for all time periods studied remained basically unchanged from weeks 4 through 10. Minimal cell differences also were noted as the analysis progressed from the one-half to the apical levels.

Histiocytes, lymphocytes, and plasma cell counts were recorded together under the heading of chronic inflammatory response (Table 3). A minor gradient was noted as the analysis progressed from the one-half to the apical level while minimal changes also were noted from weeks 4 through 10. Polymorphonuclear leucocyte counts were low and stable for all time periods and levels after the 4-week period (Table 4).

One extraction site was allowed to heal prior to appliance insertion for each time interval. Clinically these tissue samples were more firm and less friable than the majority of tissues from the other sites. Microscopically, no areas of ulceration were noted in these tissue samples. The thickness of the epithelial surface was comparable to that previously discussed for other tissue samples. Fibroblast counts were higher in these specimens, while acute and chronic inflammatory cells decreased in comparison to other samples.

Discussion

The results of this study showed that well-organized epithelium readily covered the exposed connective tissue approximating the stainless steel

intra gingival extensions at least by the 4-week sampling time. How much earlier than 4 weeks this occurred with not discernable by this study. All monkeys, at all time periods, showed this ability for epithelium to progress over the exposed connective tissue. This is in contrast to the findings of Kelisek, Binns, and Carrel³ who reported well-organized epithelium only at the 12-week period when similar appliances were placed in rabbits.

The relationship of rete peg proliferation and dental-gingival sulcus areas of inflammation have been reported by various authors.⁸⁻¹¹ Rete peg proliferation seen in this study also was found to be most associated with areas of high density of inflammatory cells in the underlying connective tissue. Areas of sparse inflammatory cell infiltrate in the connective tissue most often showed a uniform proliferation of epithelium. These findings were in agreement with studies completed in monkeys,¹²⁻¹⁴ and humans,¹⁵ which noted a greater mitotic rate of epithelial cells in relation to an increasing infiltrate in the underlying connective tissue.

A direct relationship also was noted between increased intracellular spacing within the epithelial surface and adjacent dense inflammatory response within the underlying connective tissue. This finding in all tissue specimens warrants an understanding that a destructive process to the epithelium occurred within the clinical conditions of this study. The findings of the levels of the chronic inflammatory response and the fact that the polymorphonuclear leucocytes showed very little change after four weeks, suggests that a chronic state of mild inflammation was acquired by the 4-week interval. This level of inflammation was maintained, which probably contributed to the resultant ulceration of the epithelial surface found at the 8- and 10-week intervals.

Fibroblasts may be utilized to indicate connective tissue maturity. A comparison of fibroblast counts for all tissues at all week intervals reveals minimal differences from week to week. This, in conjunction with the Gomori's stain colorimetric analysis for connective tissue maturity, reveals that by the four-week period, fibroblasts were well organized under these clinical conditions.

The most likely cause of ulceration of the epithelial surface observed in this study is the cellular and molecular result of acute and/or chronic inflammation in the sulcus. No attempt was made to control the oral hygiene status of the animals. The plaque-derived substances of destructive nature coupled with immunopathologic or other destructive inflammatory mechanisms of the host may oppress the host defenses sufficiently to result in tissue destruction.

The four specimens obtained from appliance insertion into fresh incisions of clinically healed extraction sites demonstrated earlier and greater overall matur-

ation. This was supported by the increased fibroblast counts and lower inflammatory cell counts. It is hypothesized that the healing process and epithelization is facilitated by allowing the extraction site to begin organization before placing the intra gingival extension.

The results of this study direct attention to the presence of the inflammatory response and its resultant destructive potential from an intra gingival appliance. The exact etiology of this inflammation is unknown but has several possible sources. These include: (1) the intra gingival extension, (2) bacterial accumulations on the intra gingival extension, (3) food debris and decomposition, (4) trauma to area upon insertion, and (5) individual monkey response. Of these, trauma and individual monkey response seem to be the least likely because of the differences in observed responses between fresh extraction sites and clinically healed sites.

The results reported by Kelisek, Binns, and Carrel³ on epithelization and inflammation with intra gingival appliances in the rabbit model cannot be supported totally by this study. Epithelization to surround the extension was found to occur over a longer period of time in the rabbit model. Intense inflammation was shown to be present by four weeks with minimal epithelization. As epithelization progressed, the inflammation decreased to the extent of resolving the inflammatory state. The authors concluded that injuries to the tissues or individual response by the animal were the most likely exceptions to the proper order of healing of the gingival tissues following placement of the intra gingival appliance. In this study the determinant factor of overall tissue response may be associated more directly with the chronic state of mild inflammation acquired by the 4-week interval. In addition, results from primate research generally best represent those to be expected in humans.

Contradictions for placing intra gingival appliances in children with generalized systemic illnesses, cited by Hicks² and Drinkard and Oldenburg¹⁶ are supported by this study. The potential for ulceration and acute exacerbation of inflammatory responses, possibly associated with transient bacteremias, warrant limited utilization of these appliances. Proven use, without reported consequence in healthy children, probably is due to the ability of the child's oral tissues to resist infection.^{2,17}

Conclusions

It has been shown that epithelium forms initially between the connective tissue and the stainless steel intra gingival extension when placed in monkeys. At the 4-week interval, the epithelial and fibroblast components were well organized. However, a chronic state of mild inflammation was acquired at this same time.

The chronic nature of the cellular inflammatory response may be responsible for the ulceration of the epithelial surface. A more rapid healing or maturation process was found to occur if the extraction site is allowed to heal prior to appliance insertion. Additionally, no ulcerations or breaks in the epithelium were found in these samples. General host responses to the intragingival extensions and inflammatory infiltrate can be predicted.

Support for the contraindication of intragingival appliance placement in a medically compromised patient has been demonstrated. However, in healthy children, the distal shoe space maintainer remains a viable treatment for guiding permanent first molar eruption following premature loss of the primary second molar.

This paper was completed by Dr. Mayhew in partial fulfillment of the requirements for the master of science degree in the department of pedodontics, University of North Carolina School of Dentistry.

Dr. Mayhew maintains a private pedodontic practice in Boone, NC. Dr. Gary J. Dilley maintains a private orthodontic practice in Cary, NC, and is a clinical assistant professor, Department of Orthodontics, University of North Carolina School of Dentistry, Chapel Hill, NC 27514. Dr. Diane C.H. Dilley is an associate professor and is graduate clinical director, Department of Pedodontics at UNC. Dr. Jacoway is a professor, Department of Oral Diagnosis at UNC. Dr. Johnson is principal consultant, P.J. Associates, Chapel Hill, NC. Requests for reprints should be sent to Dr. Diane C.H. Dilley.

1. Willett RC: Radical departures from theories and methods pertaining to children's dentistry. *JADA* 19:1085-1102, 1932.
2. Hicks EP: Treatment planning for the distal shoe space maintainer. *Dent Clin North Am* 17:135-50, 1973.
3. Kelisek R, Binns WH Jr, Carrel R: Short-term tissue response to distal shoe appliances in rabbits: a preliminary report. *J Pedod* 5:142-53, 1981.
4. Luna LG: *Manual of Histological Staining Methods of the Armed Forces Institute of Pathology*, 3rd ed. New York; McGraw-Hill, 1968 pp 38,93.
5. Weibel ER, Kistler GS, Scherle WF: Practical stereological methods for morphometric cytology. *J Cell Biol* 30:23-38, 1966.
6. Polson AM, Kantor ME, Zander HA: Periodontal repair after reduction of inflammation. *J Periodont Res* 14:520-25, 1979.
7. Schroeder HE, Münzel-Pedrazzoli S: Correlated morphometric and biochemical analysis of gingival tissue. *J Microscopy* 99:301-29, 1973.
8. Page RC, Schroeder HE: Pathogenesis of inflammatory periodontal disease — a summary of current work. *Lab Invest* 34:235-49, 1976.
9. Heijl LC, Rifkin BR, Zander HA: Conversion of chronic gingivitis to periodontitis in squirrel monkeys. *J Periodontol* 47:710-16, 1976.
10. Hamp SE, Lindberg R: Histopathology of spontaneous periodontitis in dogs. *J Periodont Res* 12:46-54, 1977.
11. Simpson DM, Avery BE: Histopathologic and ultrastructural features of inflamed gingiva in the baboon. *J Periodontol* 45:500-510, 1974.
12. Engler WO, Ramfjord SP, Hiniker JJ: Development of epithelial attachment and gingival sulcus in rhesus monkeys. *J Periodontol* 36:44-57, 1965.
13. Caffesse RG, Kornman KS, Nasjletti CE: The effect of intensive antibacterial therapy on the sulcular environment in monkeys — Part II: Inflammation, mitotic activity, and keratinization of the sulcular epithelium. *J Periodontol* 51:155-61, 1980.
14. Hopps RM, Johnson NW: Relationship between histological degree of inflammation and epithelial proliferation in Macaque gingiva. *J Periodont Res* 9:273-83, 1974.
15. Marwak AS, Weinmann JP, Meyer J: The effect of chronic inflammation on the epithelial turnover of the human gingiva. *Arch Path* 69:147-53, 1960.
16. Drinkard CR, Oldenburg TR: Appliances for guiding first permanent molar eruption, in *Current Therapy in Dentistry*, McDonald RE, Hurt WC, Gilmore HW, Middleton RA, eds. St. Louis; CV Mosby Co, 1980 pp 446-56.
17. Mackler SB, Crawford JJ: Plaque development and gingivitis in the primary dentition. *J Periodontol* 44:18-24, 1973.

Pediatric Dentistry now Official Publication of the Association of Pedodontic Diplomates

Pediatric Dentistry is now the official publication of the Association of Pedodontic Diplomates. The request for this relationship was passed unanimously by the Board of Directors at the Annual Meeting of the American Academy of Pediatric Dentistry in Scottsdale, Arizona. Beginning with this issue, we will recognize this relationship on the table of contents page of Pediatric Dentistry.