



Complete intrusion of a maxillary right primary central incisor

Arthur Merkle, DMD

Dr. Merkle maintains a private practice of pediatric dentistry in Fort Walton Beach, Florida. Correspond with Dr. Merkle at merkle@adisfwb.com

Abstract

This clinical article presents a rare presentation of complete intrusion of a maxillary right primary central incisor. Routine examination of a 29-month old female patient revealed an intrusion injury where the primary central incisor was displaced through the floor of the nasal cavity. The traumatic impaction was erroneously diagnosed as an avulsion injury by the attending emergency room physician and later discovered by the dental team during routine care. The injury was documented with radiographs. The intruded incisor was removed through the right naris utilizing general anesthesia to manage behavior and surgical access. This article emphasizes the importance of radiographs and demonstrates the need to involve the dental professional in initial assessment of dental trauma. (Pediatr Dent 22:151-152, 2000)

Luxation trauma constitutes 62-73 % of all injuries to the primary dentition. Because alveolar bone in the young child is relatively pliable, primary teeth are more likely to be luxated than fractured. Of luxation injuries to the primary teeth, intrusive and extrusive traumas are the most common. With a direct blow, a primary incisor can be completely intruded. A recent retrospective study showed a high incidence (69%) of complete intrusion of primary incisors among study group cohorts. If intruded sufficiently, the clinical presentation may suggest avulsion rather than intrusion. The apex of a completely intruded primary incisor will ordinarily perforate the thin alveolar bone of the labial vestibule. The following case is unusual in that a maxillary right primary central incisor was intruded enough for the apex of the tooth to perforate the nasal cavity, so that avulsion was assumed.

A 29-month old girl was seen in the dental office for routine dental care. The patient's grandmother requested a dental examination and reported that the patient lost a front tooth and received sutures to her mouth, lip, and chin as a result of an accident eight months earlier. The patient fell off a swing and was treated in the emergency room of a local hospital for her injuries. A plastic surgeon repaired lacerations to the patient's lower lip, chin and maxillary frenum. Dentists on staff in the hospital were not involved in the emergency care of the patient.

Oral examination of the patient revealed a repaired lower lip laceration and a repaired maxillary frenum tear. The maxillary right primary central incisor was not evident. Closer inspection revealed a palpable mass in the maxillary labial vestibule near the anterior nasal spine. A mass was visible on the floor of the nasal cavity viewed through the right naris. A maxillary occlusal radiograph confirmed the presence of the primary incisor (Fig 1). A lateral film of the maxilla revealed an intrusion injury in which the displacement was nearly one whole incisor length (Fig 2).

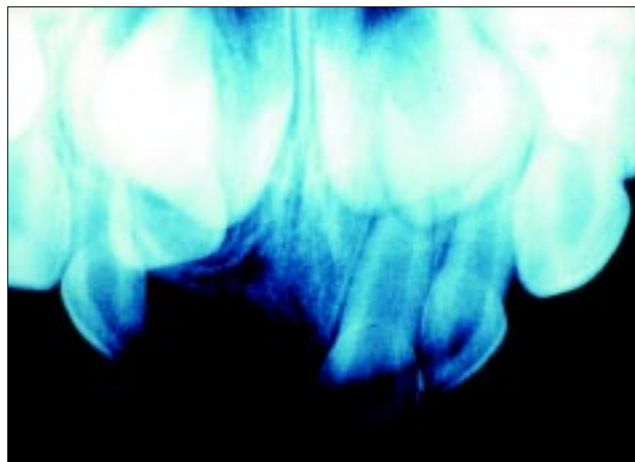


Fig 1. Occlusal radiograph confirming presence of intruded maxillary right primary central incisor.

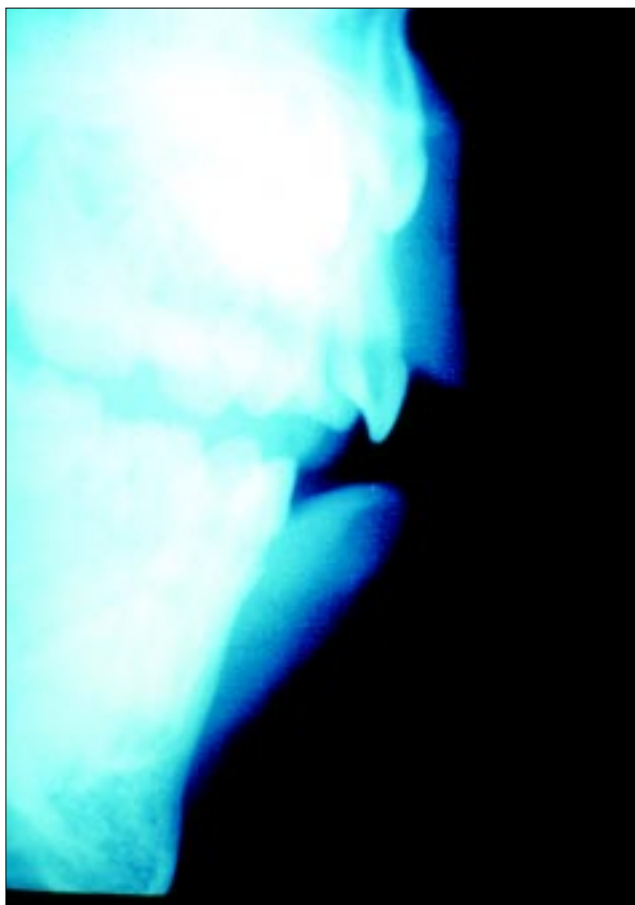


Fig 2. Lateral film of the maxilla revealing extent of intrusion of maxillary right primary central incisor.

Received December 20, 1999 Revision Accepted February 11, 2000

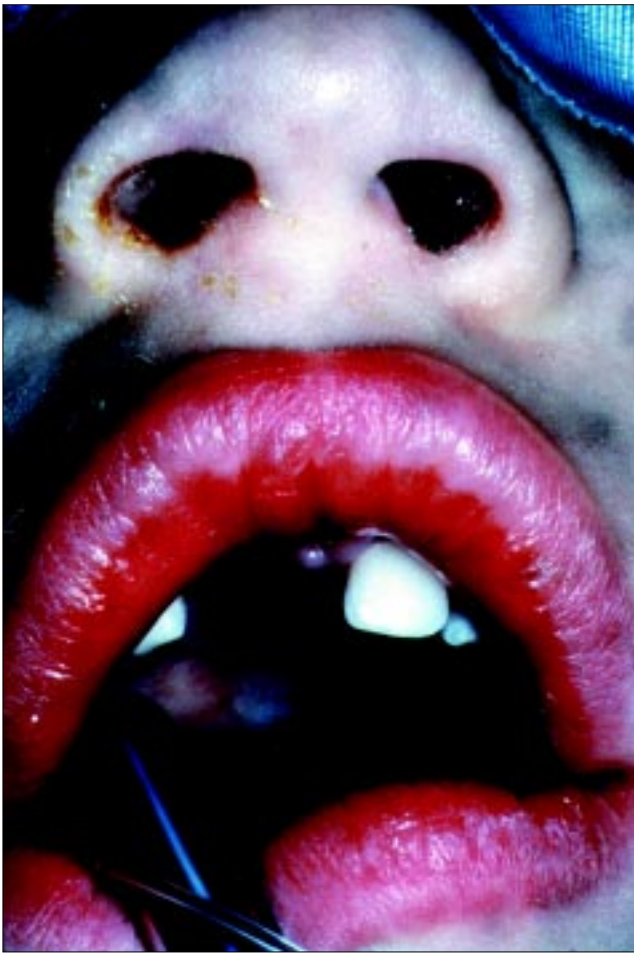

Fig 3. Presurgical photograph following intubation.

Due to potential behavior management problems and the complicated access to the intruded tooth, the patient was referred to an oral surgeon for extraction of the central incisor. The maxillary right primary central incisor was extracted utilizing a nasal approach (Figures 3 and 4). The impacted tooth was delivered via forceps through the right naris. The patient had a normal post-operative recovery. Nine months following the initial examination, the patient appeared to have uncomplicated healing. An occlusal film taken at that recall appointment revealed normally developing maxillary permanent central incisors. Unfortunately, the patient was lost to follow-up prior to the emergence of the maxillary incisors.

Due to the pliable bone that surrounds them, primary maxillary incisors are easily luxated and intruded. These short rooted teeth can be intruded to the point where they appear

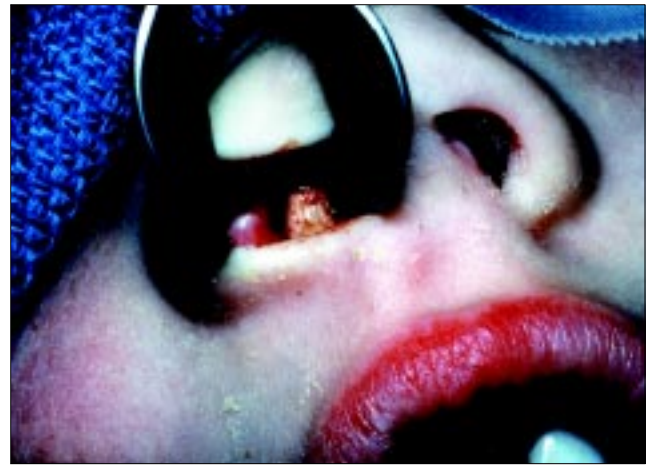

Fig 4. Surgical photograph showing speculum expansion of the right naris prior to forceps delivery of the intruded maxillary right primary central incisor.

to be avulsed. This article emphasizes the importance of careful clinical and radiographic evaluation of dental trauma. Appropriate radiographs should be recorded to confirm clinical findings. Also important is the necessity to involve a dental professional in the initial evaluation of dental trauma. Although the outcome would have been the same, earlier diagnosis and treatment would have placed the patient and her developing dentition at less risk for possible complications associated with the intrusive injury.

References

1. Andreasen JO, Andreasen, FM: Textbook and Color Atlas of Traumatic Injuries to the Teeth, 3rd Ed. Copenhagen, Denmark: Munksgaard, 1994, pp 315-82.
2. McTigue DJ: Introduction to Dental Trauma: Managing Traumatic Injuries in the Primary Dentition. In Pediatric Dentistry: Infancy Through Adolescence, 2nd Ed. Pinkham, JR ED. Philadelphia: W.B. Saunders Co., 1994, pp 209-22.
3. Andreasen JO: Traumatic Injuries of the Teeth, 2nd Ed. Copenhagen, Denmark: Munksgaard, 1981, pp 151-202.
4. Holan G, Ram D: Sequelae and prognosis of intruded primary incisors: a retrospective study. *Pediatr Dent* 4:242-47, 1999.
5. Belostoky L, Schwartz Z, Soskolne WA: Undiagnosed intrusion of a maxillary primary incisor tooth: 15-year follow-up. *Pediatr Dent* 8:294-95, 1986.
6. Rakocz M, Keating J, Croll TP: Traumatic impaction of a maxillary primary incisor into the nasal cavity: Report of a case. *J. Pedodontics* 9:338-43 Summer 1985.