

## Triple-X syndrome accompanied by a single maxillary central incisor: case report

Mari Miura, DDS Naoyuki Kato, DDS, PhD Hiroshi Kojima, DDS, PhD Haruhisa Oguchi, DDS, PhD

### Abstract

Facial, oral, and dental findings of an 11-year-old girl with XXX syndrome are reported. Clinical examination reveals midfacial hypoplasia, congenital absence of teeth, and solitary maxillary central incisors both in primary and permanent dentitions. (*Pediatr Dent* 15: 214-17, 1993 )

### Introduction

The XXX female was first reported by Jacobs et al.<sup>1</sup> Most individuals with the XXX karyotype are phenotypically normal females and have normal gonadal functions. Affected females usually are identified by chance through X-chromatin screening programs or amniocentesis ordered for other reasons. The birth rate is approximately 1/1000.<sup>2</sup> The females who have additional X chromosomes are called poly-X syndrome patients, the largest number being XXXXX. The degree and frequency of abnormalities tend to increase as the number of X chromosomes increase;<sup>3</sup> some of the patients exhibit mental retardation, congenital heart disease, and various epidermodysplasias — mainly hypertelorism, epicanthal folds, shortness of fifth fingers, and microcephaly.<sup>3-5</sup> Oral abnormalities such as midfacial hypoplasia, delayed eruption, congenital absence of teeth, and taurodontism have also been found in this syndrome.<sup>6,7</sup>

A single maxillary central incisor was reported to be associated with short stature<sup>8,9</sup> or growth hormone deficiency,<sup>10</sup> while some authors denied it in their case reports.<sup>11,12</sup> Dolan et al.,<sup>13</sup> Boudailliez et al.,<sup>14</sup> and Bamba et al.<sup>9</sup> reported a deletion of the short arm of chromosome 18 (18p<sup>-</sup>) or a deletion of the long arm of chromosome 7 (7q<sup>-</sup>) in their cases of single maxillary central incisors. However, no reports were found to be associated with poly-X syndrome.

This paper reports on facial, oral, and dental manifestations of a XXX female with a single maxillary central incisor.

### Case report

The patient is a Japanese female, and both parents and her younger brother are normal and healthy.

The patient's in utero course (40 weeks) and delivery were uneventful. The parents were both 27 years old at the patient's birth. Birth weight was 2480 g. During her first 3 years, the patient was diagnosed with XXX (47,XXX) syndrome, patent ductus arteriosus, epilepsy, and mental retardation (at the Department of Pediatrics, Hokkaido University School of Medicine). At 3 years, 6 months of age, she was referred to the Department of Pediatric Den-

tistry, Hokkaido University School of Dentistry for evaluation of a single maxillary primary central incisor. The radiographic examination revealed a single maxillary primary central incisor in the midline with a single root and a single pulp canal (Fig 1). The tooth was composed of normal enamel and dentin.

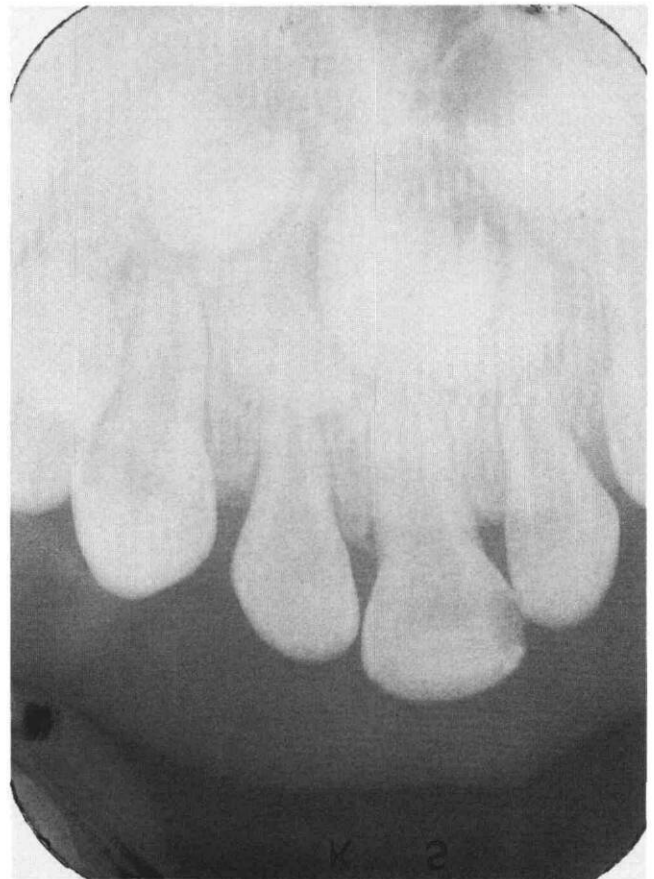
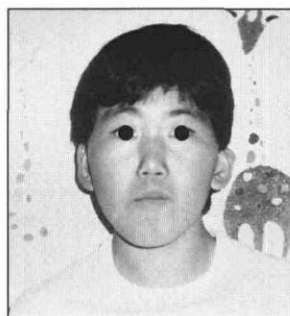


Fig 1. Apical radiograph taken at age 3 years, 6 months. A single maxillary primary central incisor is clearly evident. Note the single maxillary permanent central incisor on the midline of the maxilla.

**Table 1. Cephalometric analysis**

	Patient	Mean ± SD*
Facial angle	79.5	83.14 ± 2.52
Convexity	167.0	169.68 4.61
A-B plane	-6.5	-6.98 2.27
Mandibular plane	43.5	31.98 2.40
Y-axis	89.6	64.61 2.99
Interincisal	106.8	124.32 0.85
L-1 to mandibular	70.0	93.78 5.94
U-1 to FH plane	124.0	109.83 5.25
Gonial angle	144.0	129.20 ± 4.65

\* Standard of the Japanese aged 9y 6m ± 0.6 by Iizuka.<sup>19</sup>



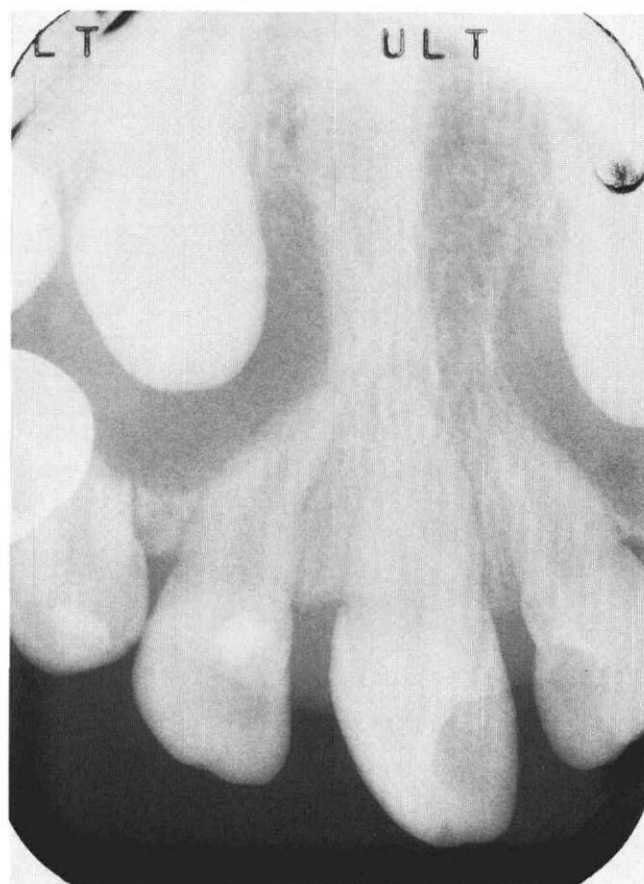
**Fig 2. Facial appearance of the patient at age 11 years.**

The patient revisited our hospital at 11 years of age for oral and dental examination. She was of average height (136 cm) and weight (31 kg). Head circumference was 50 cm — two standard deviations smaller than the average Japanese female. She exhibited low-set ears; hypotelorism with a 30-mm internalcanthus distance and 93-mm outer externalcanthus distance;

epicanthal folds; broad enlarged dorsum and deficient tip of nose; midfacial hypoplasia; and mandibular prognathism (Fig 2). Mandibular prognathism was confirmed by cephalometric analysis (Table 1).

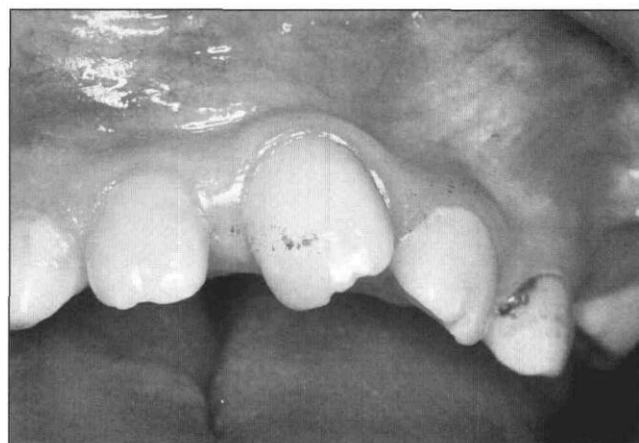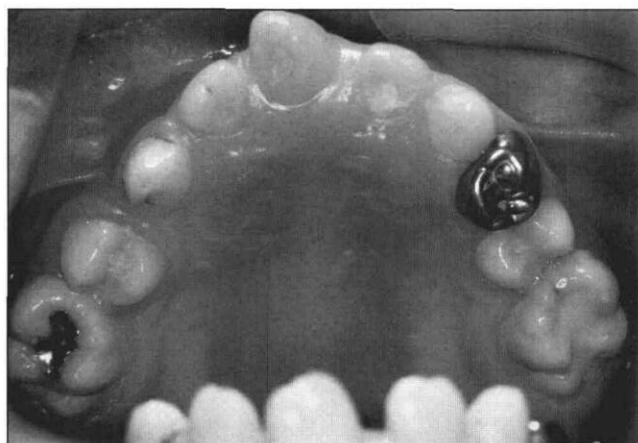Oral findings showed shallow-arched palate, bifid uvula, absence of upper labial frenum, and incisal papilla. The gingiva, tongue, and oral mucosa were normal in color, contour, and texture.

A single maxillary permanent central incisor was ob-



**Fig 4. Apical radiograph taken at age 11 years.**

served, which was rotated and located slightly left of the midline (Fig 3 a, b). The tooth was composed of normal enamel and dentin with a single root and a single pulp canal (Fig 4). We could not discriminate whether this tooth was a left or right incisor. Trauma to the primary anterior teeth or extraction of a maxillary permanent central incisor was denied. In addition, an apical radiograph, taken at 3 years, 6 months of age, clearly showed a single maxillary permanent central incisor on the midline of the



**Fig 3. Intraoral view of: A) the upper jaw (mirror view), and B) the maxillary anterior teeth.**

**Table 2. Mesiodistal (M-D) crown width of permanent teeth (in mm)**

	Patient		Japanese Female*	
	Right	Left	Mean	± SD
<b>Maxilla</b>				
Central incisor		8.20	8.24	± 0.41
Lateral incisor	7.52	7.06	6.64	0.60
First premolar	unerupted	7.98	7.08	0.36
First molar	12.66	13.20	10.39	0.51
<b>Mandible</b>				
Central incisor	6.56	6.25	5.19	0.36
Lateral incisor	unerupted	7.56	5.81	0.39
First premolar	unerupted	unerupted	6.94	0.34
First molar	12.30	13.46	10.69	± 0.60

\* Average M-D width (mean ± SD) of permanent teeth in the Japanese female was quoted from the study of Otsubo.<sup>20</sup>

upper jaw (Fig 1). The mesiodistal width of this tooth was 8.2 mm, which is within normal range. Morphology of the other erupted teeth was normal.

She was in mixed dentition stage, and eruption of permanent canines and premolars was slightly delayed for her age. The mesiodistal width of each erupted permanent tooth was fairly greater than average size, except for a single maxillary permanent central incisor (Table 2).

A panoramic radiograph showed congenital absence of maxillary second premolars on both sides (Fig 5).

## Discussion

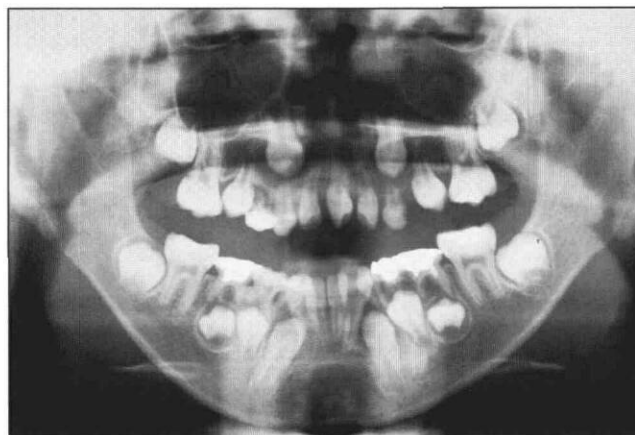
XXX female was first reported by Jacobs et al.<sup>1</sup> Since then, only a few reports have been published that describe oral and dental manifestations.

Poly-X syndrome was reported to be associated with midfacial hypoplasia, delayed eruption, and congenital absence of teeth.<sup>6,7</sup> The patient reported here also has these anomalies. However, she has a shallow-arched palate, while Archidiacono et al.,<sup>6</sup> Farge et al.,<sup>7</sup> and Kohn et al.<sup>15</sup> noticed high-arched palates in poly-X patients.

The most characteristic finding in this case was single maxillary central incisors both in primary and permanent dentitions. As far as we know, no report has been published on the association between a single maxillary central incisor and poly-X syndrome. Bartholomew et al. reported a case of a single maxillary primary central incisor in association with hypomelanosis of Ito, which is considered to be an X-linked inherited disease.<sup>16</sup>

Dolan et al.<sup>13</sup> and Boudailliez et al.<sup>14</sup> reported a deletion of the short arm of chromosome 18 (18p<sup>-</sup>) in their cases of single maxillary central incisors. Bamba et al., however, noted two cases of 7q<sup>-</sup> instead of 18p<sup>-</sup> in six patients with single maxillary central incisors.<sup>9</sup>

Since Rappaport et al. reported on seven cases of solitary maxillary central incisor and short stature,<sup>10</sup> several



**Fig 5. Panoramic radiograph taken at age 11 years.**

reports on single maxillary central incisors have been published that evaluated patients' growth rates.<sup>8,9</sup> Wesley et al. pointed out that "there are persons with this tooth anomaly who do not have a growth hormone deficiency, whereas others with the same anomaly do have hypopituitarism."<sup>11</sup> A recent paper by Hunter et al. reported a patient with a single maxillary central incisor, whose height and weight were within normal limits.<sup>12</sup> In our case, the patient's height and weight were normal, although head circumference was smaller (-2 S.D.) than the average size.

The tooth crown size of 45,X females was reported to be smaller than normal females.<sup>17</sup> However, a report by Alvesalo et al. had the mesiodistal width of the crown of XXX patient not statistically different from that of normal females.<sup>18</sup> The influence of the additional X chromosomes on the morphology and size of teeth is still unclear. In the present case, the mesiodistal width of each erupted permanent tooth was fairly greater (6.3–27.0%) than the average size except for a maxillary permanent central incisor.

The functional significance of the X chromosome in dental anomalies is a very interesting research problem. Since only a few reports have appeared, more are needed to clarify the characteristic features of oral and dental manifestations in XXX syndrome.

Dr. Miura is a resident, Dr. Kato is an instructor, Dr. Kojima is an assistant professor, and Dr. Oguchi is a professor in the Department of Pediatric Dentistry, Hokkaido University School of Dentistry, Sapporo, 060, Japan.

1. Jacobs PA, Baikie AG, Court Brown WM, MacGregor TN, Maclean N, Harnden DG: Evidence for the existence of the human "super female." *Lancet* 2:423–25, 1959.
2. Cohen MM, Nadler HL: The 47,XXX female. *Nelson Textbook of Pediatrics*, 12th ed, Behrman RE, Vaughan VC III Eds. Philadelphia: WB Saunders Co, 1983, p 309.
3. Telfer MA, Richardson CE, Helmken J, Smith GF: Divergent phenotypes among 48,XXXX and 47,XXX females. *Am J Hum Genet* 22:326–35, 1970.
4. Brody J, Fitzgerald MG, Spiers ASD: A female child with five X chromosomes. *J Pediatr* 70:105–9, 1967.
5. Sergovich F, Uilenberg C, Pozsonyi J: The 49,XXXXX chromo-

- 
- some constitution: Similarities to the 49,XXXXY condition. *J Pediatr* 78:285-90, 1971.
6. Archidiacono N, Rocchi M, Valente M, Filippi G: X pentasomy: a case and review. *Hum Genet* 52:69-77, 1979.
  7. Farge P, Dallaire L, Albert G, Melancon SB, Potier M, Leboeuf G: Oral and dental development in X chromosome aneuploidy. *Clin Genet* 27:122-26, 1985.
  8. Fulstow ED: The congenital absence of an upper central incisor: report of a case. *Br Dent J* 124:186-88, 1968.
  9. Bamba S, Terayama H, Ikeda M, Ogata K: Clinical evaluation of 6 patients with a single maxillary central incisor. *J Jpn Soc Dent Handicap* 10:52-66, 1989.
  10. Rappaport EB, Ulstrom RA, Gorlin RJ, Lucky AW, Colle E, Miser J: Solitary maxillary central incisor and short stature. *J Pediatr* 91:924-28, 1977.
  11. Wesley RK, Hoffman WH, Perrin J, Delaney JR Jr: Solitary maxillary central incisor and normal stature. *Oral Surg* 46:837-42, 1978.
  12. Hunter ML, Chadwick BL, Hunter B: Single deciduous and permanent central incisor: Congenital absence or median fusion. *Pediatr Dent* 1:181-84, 1991.
  13. Dolan LM, Willson K, Wilson WG: 18p- syndrome with a single central maxillary incisor. *J Med Genet* 18:396-98, 1981.
  14. Boudailliez B, Morichon-Delvallez N, Goldfarb A, Pautard JC, Lenaerts C, Piussan C: Solitary upper incisor, hypopituitarism and monosomy 18p chromosome aberration. *J Genet Hum* 31:239-42, 1983. [Text in French]
  15. Kohn G, Winter JSD, Mellman WJ: Trisomy X in three children. *J Pediatr* 72:248-52, 1968.
  16. Bartholomew DW, Jabs EW, Levin LS, Ribovich R: Single maxillary central incisor and coloboma in hypomelanosis of Ito. *Clin Genet* 32:370-73, 1987.
  17. Kari M, Alvesalo L, Manninen K: Sizes of deciduous teeth in 45,X females. *J Dent Res* 59:1382-85, 1980.
  18. Alvesalo L, Tammissalo E, Therman E: 47,XXX females, sex chromosomes, and tooth crown structure. *Hum Genet* 77:345-48, 1987.
  19. Iizuka T: The cephalometric study on the facial growth in Japanese children. *J Stomatol Soc Jpn* 25:260-72, 1958. [Japanese Text]
  20. Otsubo J: A study on the tooth material in Japanese adults of normal occlusion, its relationship to coronal and basal arches. *J Jpn Orthod Soc* 16(1):36-46, 1957. [Japanese Text]
-