

## Clinical and radiographic oral changes in a case of American Burkitt's lymphoma

Steven A. Moore, DDS Harry Israel, DDS, PhD G. Frank Johnson, MD  
John D. Bullock, MD, FACS Robert D. Stout, MD

### Abstract

*Loosening of the teeth and dental pain were the presenting symptoms in a nine-year-old boy with American Burkitt's lymphoma. Radiographic evaluation revealed osteolytic changes in the body of the mandible and there was an absence of lamina dura about the teeth. The papillae at the apices of the developing roots were enlarged, coalescent, and devoid of cortical margins. Burkitt's lymphoma among Africans is a tumor with a well-known predilection for the bone around the dentition. Jaw changes in the American disease are less pronounced, but in this instance involvement of the tooth supporting structures was more similar to the lesions of African Burkitt's lymphoma than those reported in the American type.*

**B**urkitt's lymphoma is an undifferentiated tumor that originally was described among children in the African nation of Uganda. Dr. Denis Burkitt reported large and rapidly expanding lesions that grossly distort the face. He noted that the tumor involves the alveolar processes of the maxilla and mandible to such an extent that the deciduous teeth become mobile and then displaced prior to exfoliating.<sup>1</sup> Following the characterization of the tumor, Burkitt demonstrated the dramatic response of this lesion to chemotherapy.<sup>2</sup> Since then, continuing investigation of Burkitt's lymphoma has revealed that it is a unique neoplasm yielding enormous information about tumor pathophysiology.

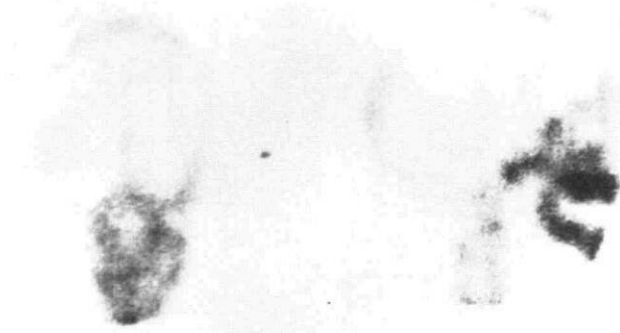
Following the original reports of Burkitt's tumor from Africa, similar cases began to be identified sporadically in other parts of the world.<sup>3</sup> A series was reported mainly among young people in the United States.<sup>4</sup> In contrast to the Africans, the most common site of presentation was the abdomen. Lymph node involvement was customary and facial bones were a less striking feature of the disease.

Though the American Burkitt's lymphoma appears to involve the facial and dental structures less than the African tumor both in terms of incidence and degree, there are reports of facial bone, submandibular lymph node, and alveolar bone manifestations.<sup>4-9</sup> This report deals particularly with the facial and dental involvement of a young male with American Burkitt's lymphoma. The dentition and tooth supporting bone were involved to such an extent that they provided the presenting symptoms.

### Case Report

A nine-year-old Caucasian male complained of loose and painful teeth of a few days duration. An oral and radiographic examination failed to alert the dentist to any untoward consequences and the symptoms were dismissed as relating to the further eruption of the permanent dentition. These symptoms were followed by headache, malaise, and anorexia over the next 10 days. At the same time a right orbital swelling developed. A diagnosis of sinusitis was made and antibiotic therapy was initiated. There was no improvement over the next 7 days, and the child was admitted to a general hospital. Increasing eye signs of proptosis and diplopia prompted biopsy of the lesion in the inferior orbit. Microscopic examination revealed an anaplastic malignancy and a presumptive diagnosis of a small cell lymphoma of the Burkitt's type was made. The patient was transferred to the Children's Medical Center, Dayton, Ohio.

His past medical history was negative except for the treatment of anemia with iron two years prior to the present illness. He was an only child and both parents were in good health. A maternal uncle died of leukemia at age one and one-half. Physical examination revealed diffuse jaundice and scleral icterus. The temperature was 37.4° C, the pulse rate was 120/min, respirations were 24/min, and the blood pressure was 100/50 mm hg. His height was 145 cm and weight was 40 kg. There was postoperative edema and hematoma of the right eye. The teeth



**Figure 1.** Radioactive uptake of the isotope  $TC^{99m}$  by the bone is evident throughout the maxilla, mandible, calvaria, and orbits.

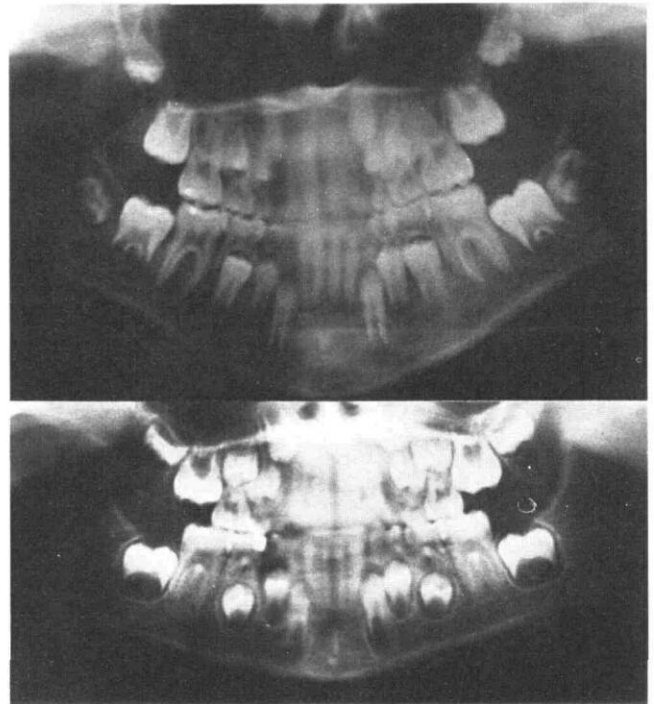
were noted to be tender and loose. There was no bleeding or petechiae of the mucous membranes although they were pale. The patient had bilateral cervical lymphadenopathy. The testes were firm, tender, and enlarged, and measured 5 cm in greatest diameter. The chest was clear to percussion and auscultation. The heart rate and rhythm were normal. There was a grade II/VI systolic ejection murmur at the upper left sternal border. The abdomen was soft, and the liver was palpable 5 cm below the right costal margin. It was tender and smooth. The spleen was not palpable. Good bowel sounds were present. The inguinal lymph nodes could not be identified. A skeletal radiographic survey demonstrated diffuse porosity of the osseous structures with characteristic leukemic density changes in the ulna and humerus. A bone radionuclide scan using Technetium  $TC^{99m}$  diphosphonate was positive for increased calvarial, orbital, maxillary, and mandibular activity (Figure 1).

An orthopantomograph demonstrated striking changes in the mandible (Figure 2). The inferior cortical elements were intact. The cancellous segments were indistinct, giving body and ramus a hazy appearance. The cortical bone around the teeth, so-called lamina dura, was absent. The dental papillae at the apices of the developing roots were without cortical margins. The papillae appeared larger than normal, tended to blend with the surrounding mandibular body, and there was an appearance of coalescence between adjacent papillae. In particular, the developing premolar papillae appeared contiguous since each tooth was of nearly similar length. The follicles encasing the third molars also were devoid of lamina dura.

Laboratory evaluation at initial staging showed  $12,200/mm^3$  white cells, and  $165,000/mm^3$  platelets. The differential white count revealed 12% blasts, 6% myelocytes, 7% metamyelocytes, 21% bands, 11% segmented, 32% lymphocytes, 8% monocytes, and 3% eosinophils. Red cell morphology was altered by anisocytosis, poikilocytosis, polychromasia, and

hypochromasia. Blood chemistry revealed a total bilirubin of 6.0 mgs/dl with a direct of 2.6 mgs/dl and an indirect of 3.4 mgs/dl. SGOT was 261 u/ml, the SGPT 267 u/ml, and the LDH 2028 u/ml. The blood electrolytes and urinalysis were normal. Burkitt's type cells were confirmed soon after admission in both the peripheral blood and iliac crest marrow, corroborating the findings in the tissue specimen removed from the right orbit. The spinal fluid had no malignant cells.

Two weeks following admission a dental consultation was requested because of the discolored maxillary central incisor. According to the patient's mother this change became apparent during his admission at the previous hospital. The tooth had always been asymptomatic and no history of trauma could be elicited. The extraoral physical examination revealed right suborbital edema and ecchymosis. A tumor-related left facial paresis existed and there was no evidence of other expansile lesions (Figure 3). The mixed dentition was in good repair. The teeth were no longer tender and were firm. There was no gingival hyperemia or edema and the mucous membranes were pale, but otherwise unremarkable. The maxillary left central incisor was pink and darkened (Figure 4). Transillumination did not suggest an enlarged pulp



**Figure 2.** The top orthopantomograph is that of the boy reported here, the lower is of a healthy individual. This comparison is used to help delineate the lesions in the boy with Burkitt's. The most dramatic changes are seen in the tooth-supporting portion of the mandible. The cortical bone elements are absent around the erupted teeth and papillae of the permanent dentition. The overall osteolytic character of the mandible is reflected in the larger than usual papillae, their coalescence, and generalized radiolucency.

chamber. There was no tenderness or swelling adjacent to the apex of the tooth. The intraoral radiographs showed an absence of cortical bone, and the clinically discolored left maxillary central incisor was without evidence of internal resorption (Figure 5). The intraoral films were exposed eight days after the orthopantomograph.

The induction treatment course consisted of prednisone. Subsequent chemotherapy included cytoxan, vincristine, and methotrexate. Irradiation was administered to the testes. Although the initial response was favorable, the patient steadily declined. Thrombocytopenia and neutropenia necessitated withholding further chemotherapy. Fever, loss of appetite, extreme weakness, and progressive lethargy terminated in death two months following admission to the Children's Medical Center and less than three months after initially being examined for dental pain.

## Discussion

Burkitt's lymphoma is a malignancy arising from undifferentiated B-cell derived lymphocytes and is, therefore, characterized by immunologic factors associated with the B-cell.<sup>10</sup> Even though the tumor has a well delineated histologic basis, there appear to be sizable opinion differences when morphologic criteria are utilized in diagnosis.<sup>11</sup> In terms of etiology, the Epstein-Barr virus has been implicated in the African type, but evidence for any association with the American tumor is less clear.<sup>12</sup> Magrath stated, ". . . it (is) most unlikely that Burkitt's lymphoma in America is etiologically related to the E-B virus."<sup>13</sup> The genetic factor exists in the translocation aberration between chromosome 8 and 14; t(8q-, 14q+). This is not exclusive to Burkitt's lymphoma, since it also has been observed in undifferentiated lymphoma. The karyotypic changes are present regardless of the presence or absence of the Epstein-Barr virus.<sup>14</sup>

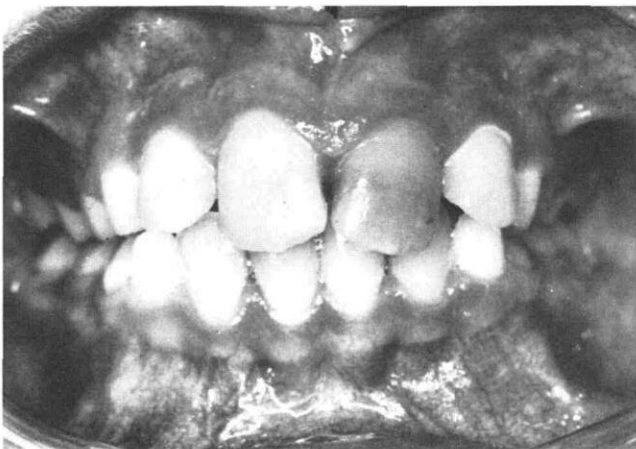
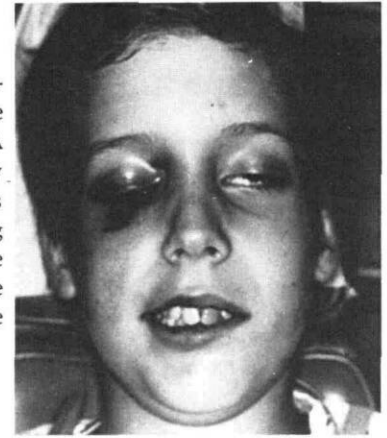
Figure 4. The maxillary left central incisor appears darkened and nonvital.

Figure 3. Ecchymosis and swelling of the right orbital areas are a result of previous biopsy. A left seventh nerve palsy developed slowly, and is demonstrated by the drooping of the corner of the mouth, the lack of expression, and the shallow nasolabial fold on the affected side.



Even though there are differences in the type of involvement, clinical course, and response to therapy, the American and African tumors share immunologic and morphologic similarities.<sup>15</sup> In terms of this report, it is the facial involvement that is pre-emptive. Burkitt observed the massive destruction to the orofacial region in African lymphoma and it prompted him to assume that the disease initiates "in the alveolar process of a maxilla or the mandible."<sup>1</sup> Adatia speculated that the high incidence of jaw involvement "may be related to odontogenesis."<sup>16</sup> The American entity is clearly more sparing of the facial bones.<sup>3</sup> Arseneau et al. found it to be basically an abdominal tumor.<sup>4</sup> They reported that "Facial bones were involved in five cases, and in three were the presenting sites of tumor." Dunnick et al. reviewed the radiographic manifestation in 40 patients, and only four had any bone lesions.<sup>9</sup> Osteolytic areas were identified in the mandible of 2 patients. Another radiographic study by Alford et al. detected no evidence

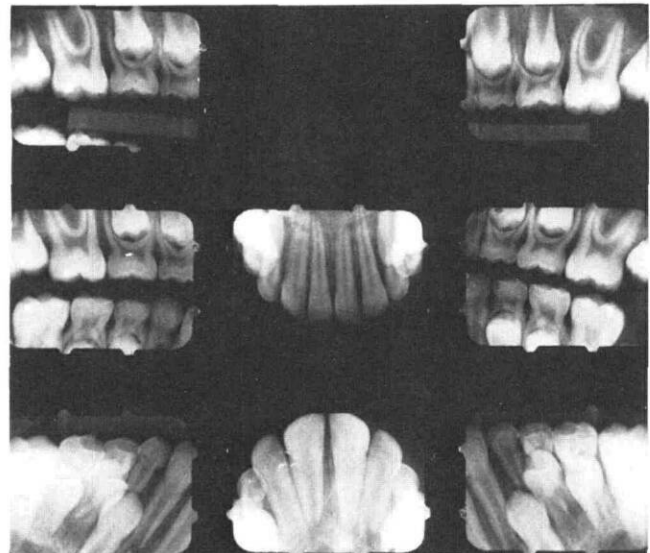


Figure 5. The dental radiographs demonstrate the overall osteolysis, but less dramatically than the orthopantomograph. There is no demonstrable internal resorption of the left maxillary central incisor which probably indicates early changes of pulpal hemorrhage into the dentinal tubules.

for bone involvement in 12 children.<sup>17</sup> Nine of these had some diagnostic combination of radionuclide scans, skeletal surveys, or mandibular series.

The radiographic changes in this patient appear more analogous to those described among Africans than North Americans. At least, the radiologic reports give that impression. Cockshott provided a lucid picture of destruction in the jaws of Africans. He described the changes as an absence of lamina dura about the germinal follicles and the teeth in one-half of 166 patients.<sup>18</sup> Pullon and Wexler reported one case of American Burkitt's lymphoma having "vague radiolucencies at the apices of the lower left second premolar, the lower left first and second permanent molar, . . ."<sup>8</sup>

The Burkitt's tumor has generated enormous investigative interest because of its unique properties. We can expect more information about this lymphoma, especially in terms of how the African and American (nonendemic) type relate to each other. Though the clinical course and organ systems involved seem to vary in the two diseases, this case demonstrates dento-facial lesions that suggest common morphologic associations. The changes described in this paper are pronounced and produce a clear picture of jaw involvement. The presence of these lesions in the tooth supporting structures may contribute in the differential diagnosis process of young persons with lymphoma.

The authors wish to express their appreciation to Barbara Brusaw, Cornelia Patrick, and Tina Buzzard for manuscript preparation, and Joe Trypak for photography.

Dr. Moore is a second-year pedodontic resident; Dr. Israel is director of dental research and associate clinical professor of pediatrics; Dr. Johnson is director and clinical professor of radiology; Dr. Bullock is associate clinical professor of ophthalmology; and Dr. Stout is director of hematology/oncology and associate professor of pediatrics, all at Wright State University School of Medicine, The Children's Medical Center, One Children's Plaza, Dayton, Ohio 45404. Requests for reprints should be sent to Dr. Israel.

1. Burkitt, D. A sarcoma involving the jaws in African children. *Br J Surg* 46:218-23, 1958.

2. Burkitt, D. Long-term remissions following one- and two-dose chemotherapy for American lymphoma. *Cancer* 20:756-59, 1967.
3. Cohen, M.H., Bennett, J.M., Berard, C.W., Ziegler, J.L., Vogel, C.L., Sheagren, J.N., Carbone, P.P. Burkitt's tumor in the United States. *Cancer* 23:1259-72, 1969.
4. Arseneau, J.C., Canellos, G.P., Banks, P.M., Berard, C.W., Gralnick, H.R., Devita, V.T., Jr. American Burkitt's lymphoma: a clinicopathologic study of 30 cases. *Am J Med* 58:314-21, 1975.
5. Abaza, N.A., Iczkocitz, M.L., Henefer, E.P. American Burkitt's lymphoma manifested in a solitary submandibular lymph node. *Oral Surg Med Path* 51:121-27, 1981.
6. Ferris, R.A., Hakkal, H.G., Cigtay, O.S. Radiologic manifestations of North American Burkitt's lymphoma. *A J R* 123:614-20, 1975.
7. Silverman, S., Jr. *Oral Cancer*. New York: American Cancer Society, 1981, pp 86-88.
8. Pullon, P.A., Wexler, D.N. Burkitt's lymphoma: a problem in dental diagnosis. *J Dent Child* 42:213-15, 1975.
9. Dunnick, N.R., Reaman, G.H., Head, G.L., Shawker, T.H., Ziegler, J.L. Radiographic manifestations of Burkitt's lymphoma in American patients. *A J R* 132:1-6, 1979.
10. Mann, R.B., Jaffe, E.S., Braylan, R.C., Nanba, K., Frank, M.M., Ziegler, J.L., Berard, C.W. Nonendemic Burkitt's lymphoma, a B-cell tumor related to germinal centers. *N Engl J Med* 295:685-91, 1976.
11. Ziegler, J.L. Medical progress, Burkitt's lymphoma. *N Engl J Med* 305:735-45, 1981.
12. Zeigler, J.L., Magrath, I.T., Gerber, P., Levine, P.H. Epstein-Barr virus and human malignancy. *Ann Intern Med* 86:323-36, 1977.
13. Magrath, I.T. Lymphocyte precursors and neoplastic counterparts in vivo and in vitro, (pp 226-30), in: Berard, C.W., moderator, A multidisciplinary approach to non-Hodgkin's lymphoma. *Ann Intern Med* 94:218-35, 1980.
14. Douglass, E.C., Magrath, I.T., Lee, E.C., Whang-Peng, J. Serial cytogenetic studies of nonendemic Burkitt's lymphoma cell lines. *J Nat Cancer Inst* 65:891-95, 1980.
15. Jaffe, E.S. Non-Hodgkin's lymphomas as neoplasms of the immune system. 94:222-26, in: Berard, C.W., moderator. A multidisciplinary approach to non-Hodgkin's lymphomas. *Ann Intern Med* 94:218-35, 1980.
16. Adatia, A.K. Significance of jaw lesions in Burkitt's lymphoma. *Br Dent J* 145:263:66, 1978.
17. Alford, B.A., Coccia, P.E., L'Heureux, P.R. Roentgenographic features of American Burkitt's lymphoma. *Radiology* 124:763-70, 1977.
18. Cockshott, W.P. Radiological aspects of Burkitt's tumor. *Br J Radiol* 38:172-80, 1965.

## Quotable Quote

Microwave-cooked food may retain more vitamins than food cooked other ways, says nutritionist Gertrude Armbruster of Cornell University. She found, for example, that cooking fruits and vegetables in a microwave oven cuts the loss of vitamin C up to 50%. Vitamin C is one of the vitamins most easily destroyed by cooking. Baking and boiling require longer cooking time, which breaks down the vitamin.

From: *Science* '83, Vol. 4, No. 1, January/February.