



Treatment of Class III problems begins with differential diagnosis of anterior crossbites

Peter Ngan, DMD Annie M. Hu, DDS, MS Henry W. Fields, Jr., DDS, MS, MSD

Abstract

Etiology of Class III malocclusion can be genetic or environmental. Proclination of mandibular incisors and retroclination of maxillary incisors can cause posturing of the mandible in an anterior position due to incisal interference, a condition called pseudo Class III malocclusion that can be misleading in evaluating a patient with skeletal Class III malocclusion. Unfortunately, cephalometric evaluation may not be the most reliable tool in differentiating whether the maxilla or the mandible contributes to the skeletal disharmony. The most consistent findings seem to be the dental characteristics of Angle's Class III molars and canines, retroclined mandibular incisors, and the presence of an edge-to-edge or an anterior crossbite occlusion. This paper presents a diagnostic scheme to differentiate between dental and skeletal crossbites. Early treatment of Class III malocclusion can help to minimize the adaptations and limitations that are often seen in severe malocclusion of the late adolescence. However, treatment of skeletal crossbites remains a continuous challenge to the profession. Due to the diversity and variability in facial growth, accurate individualized growth prediction is not possible at the moment. Treatment directed at the mandible seems to invite relapse during the pubertal growth period. Treatment directed at the maxilla shows promising results and is awaiting long-term clinical results following early orthopedic interventions. Several intraoral appliances have proved to be successful in eliminating dental crossbites. (Pediatr Dent 19:386-95, 1997)

Prevalence of Class III malocclusion

The prevalence of Class III malocclusion varies among different ethnic groups (Table 1). The prevalence of this type of malocclusion in the Caucasian population is approximately 3-5% (Table 1).¹⁻⁹ In studies of US African-American population groups, the prevalence is approximately 3-6%.¹⁰⁻¹³ Though few epidemiologic studies are

available for other ethnic groups, higher frequency of Class III malocclusion is reported in Asian populations.¹⁴⁻¹⁶

Etiology of Class III malocclusion

The few studies of human inheritance and its role in Class III malocclusion support the belief that growth and the size of the mandible are affected by heredity.^{17, 18} Jacobson et al.¹⁹ noted that the most well-known example of inheritance, as described by McGuigan in 1966,²⁰ is that of the Hapsburg family. The distinct characteristics of this family included a prognathic lower jaw. Of 40 members of the family for whom records were available, 33 showed prognathic mandibles. In 1970, Litton et al.¹⁷ studied the families of 51 individuals with Class III anomalies. They concluded that dental Class III characteristics were related to genetic inheritance in offspring and siblings.

Rakosi and Schilli²¹ describe some environmental influences, such as habits and mouth-breathing, on the etiology of Class III malocclusion. Excessive mandibular growth could arise because of mandibular posture, as constant distraction of the mandibular condyle from the fossa may be a growth stimulus. Functional mandibular shifts because of respiratory

TABLE 1. REPORTED PREVALENCE OF CLASS III MALOCCLUSION IN CAUCASIAN POPULATION

Investigator	Date	Sample	Incidence
Ainsworth ¹	1925	4170 (2-11 yrs)	1.25%
Huber and Reynolds ⁵	1946	500 (16-32 yrs)	12.2
Bjork ²	1947	322 (boys 1 yrs)	2.8
Enrich and Associates ¹³	1957	1476 (12-14 yrs)	3
Humphreys and Associates ³	1950	2711 (2-5 yrs)	1.52
Massler and Frankel ⁴	1951	2758 (14-18 yrs)	9.4
Newman ⁶	1956	3355 (6-14 yrs)	0.48
Goose and Associates ⁷	1957	2956 (7-15 yrs)	2.91
Hill and Associates ⁷	1959	4251 (6-8 yrs)	1
		4127 (15-18 yrs)	1
Altemus ¹⁰	1959	3280 (12-16 yrs)	5
Horowitz and Doyle ¹²	1970	410 (9-14 yrs)	8.7
Garner and Butt ¹¹	1985	445 (13-15 yrs)	6.3%

needs, tongue size, or pharyngeal dimensions, may also affect the jaw size.²²

Characteristics of skeletal Class III malocclusion

Individuals with Class III malocclusion may have combinations of skeletal and dentoalveolar components. Consideration of the various components is essential so that the underlying cause of the discrepancy can be treated appropriately. Jacobson et al.¹⁹ conducted a cephalometric study to identify the various types of skeletal Class III patterns. The Class III pattern with the highest frequency was the normal maxilla and prognathic mandible. Approximately 25% of the Class III group showed a deficiency in the maxilla. In comparison to subjects with normal skeletal patterns, Class III subjects had a shorter anterior cranial base, a more obtuse gonial angle, glenoid fossa positioned further forward, more proclined maxillary incisors, and more retroclined mandibular incisors. Ellis and McNamara²³ reported a higher frequency of maxillary retrusion in their sample (Table 2). Similar results were reported by

TABLE 2. COMPONENTS OF CLASS III MALOCCLUSION (ELLIS AND MCNAMARA)²¹

Group	Maxilla	Mandible	No. (%)
I	retrusive	protrusive	30.1
II	retrusive	neutral	19.5
III	neutral	neutral	19.2
IV	protrusive	protrusive	14.9
V	retrusive	retrusive	7.9
VI	neutral	neutral	4.6
VII	neutral	neutral	1.6
VIII	protrusive	neutral	1.6
XI	protrusive	retrusive	0.33

Guyer et al.²⁴ However, cephalometric analysis may not be the most reliable tool to differentiate whether the maxilla or mandible contributes to the skeletal disharmony. In two separate studies, clinicians failed to identify the etiology of Class II²⁵ and Class III malocclusion,²⁶ respectively. The most consistent findings seem to be the dental characteristics which include Angle's

Class III molars and canines, retroclined mandibular incisors, proclined maxillary incisors, and an edge-to-edge incisor relationship or anterior crossbite.

Differential diagnosis of anterior crossbite

Anterior crossbite is defined as a malocclusion resulting from the lingual position of the maxillary anterior teeth in relationship to the mandibular anterior teeth.²⁷ Anterior crossbite in the primary dentition may be due to the abnormal inclination of the maxillary and mandibular incisors, occlusal interferences (functional), or skeletal discrepancies of the maxilla and/or mandible.^{27, 28} To differentiate a dental from a skeletal crossbite, the following diagnostic scheme can be adapted (Fig 1).

I. Dental assessment: Check if the Class III molar relationship is accompanied by a negative overjet. If a positive overjet or end-to-end incisal relationship is found, together with retroclined mandibular incisors, a compensated Class III malocclusion is suspected (i.e., upper incisors are proclined and lower incisors are retroclined to compensate for the skeletal discrepancy). If a negative overjet is found, proceed to the functional assessment.

II. Functional assessment: As-

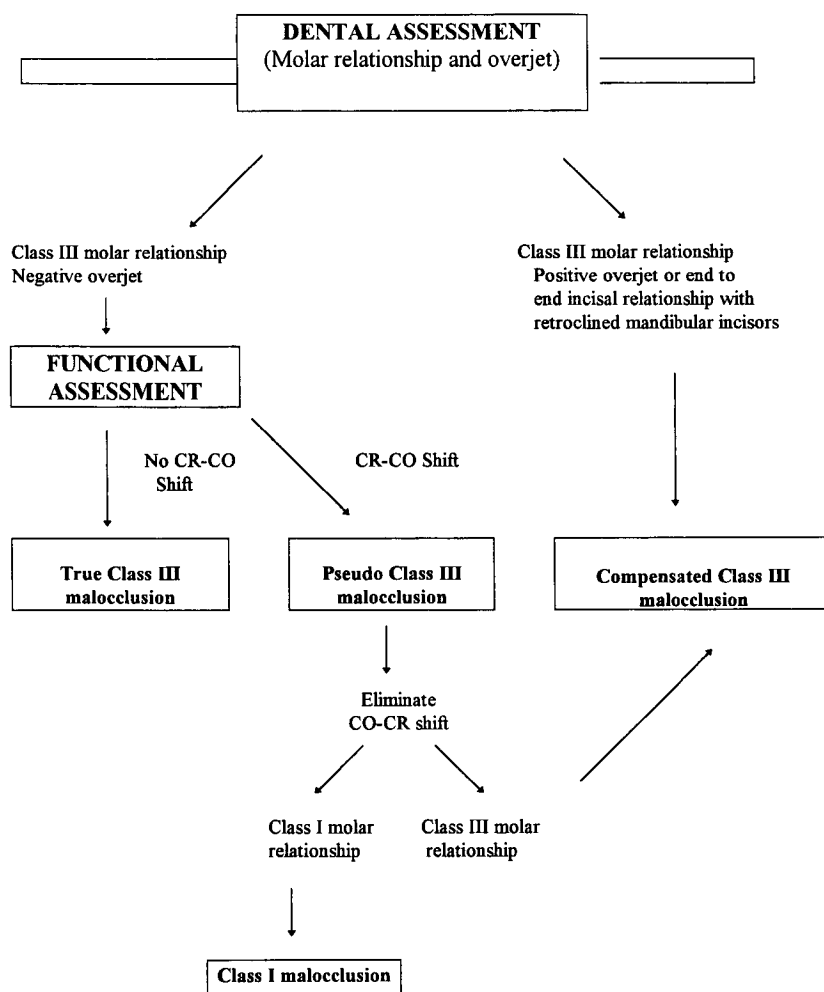


Fig 1. Diagnostic scheme for dental and skeletal anterior crossbites.

sess the relationship of the maxilla to the mandible to determine whether a centric relation/centric occlusion (CR-CO) discrepancy exists. Anterior positioning of the mandible may result from abnormal tooth contact that forces the mandible forward. Patients who present with a forward shift of the mandible on closure may have a Class I skeletal pattern, normal facial profile, and Class I molar relation in centric relation, but a Class III skeletal and dental pattern in centric occlusion, a situation referred to as pseudo Class III malocclusion. Elimination of CR-CO shift should reveal whether it is a simple Class I malocclusion or a compensated Class III malocclusion. On the other hand, a patient with no shift on closure most likely has a true Class III malocclusion.

III. Profile analysis: Turley²⁹ recommended evaluation of the overall facial proportions, chin position, and midface profile. Is the overall profile convex, straight, or concave? Is the maxilla retruded or is the mandible protruded? By blocking out the upper and lower lips, evaluate the chin relative position to the nose and upper face. Is the chin retruded or protruded? By blocking out the lower lip and chin, evaluate the midface. There should be a convexity or an imaginary line extending from the inferior border of the orbit through the alar base of the nose down to the corner of the mouth. A straight or concave tissue contour indicates a midface deficiency.

Growth and growth predictions of Class III malocclusion

No two persons are identical, and each person has a unique facial growth pattern,³⁰ but several investigations have attempted to predict the progression of Class III malocclusions. The aim was to determine if growth prediction can be used to differentiate children with Class III tendency. The data might provide a specific skeletal morphological pattern that is identifiable in Class III malocclusions.

According to Enlow,³¹ individuals or ethnic groups with a brachycephalic head form have a correspondingly greater tendency toward Class III malocclusions and prognathic profiles. The head form is rounder, shorter horizontally, and encompasses a wider brain. This sets up a cranial base that is more upright and has a more closed flexure, which decreases the effective horizontal dimension of the middle cranial fossa. The middle and anterior cranial fossae are wider but less elongated. The anterior cranial fossa provides the template that establishes the horizontal length and bilateral width of the nasomaxillary complex, which is thereby shorter but wider.³¹ The author concluded that the composite result is a relative retrusion of the nasomaxillary complex and a more forward placement

of the entire mandible, with a greater tendency toward a prognathic profile and Class III molar relationship.

In 1970, Dietrich³² reported that Class III skeletal discrepancies worsened with age. Children with a negative ANB angle were examined in three stages: stage 1, deciduous; stage 2, mixed; and stage 3, permanent dentition. The percentage of children with mandibular protrusion increased from 23 to 30 to 34% as the dentition progressed from stage 1 through stage 3, respectively. Maxillary anteroposterior deficiency problems went from 26 to 44 to 37%. These results indicate that the abnormal skeletal characteristics can become worse with time. Rakosi and Schilli²¹ reported a conflicting result. The authors examined 2000 preschoolers and found that 18% of all malocclusions in the primary dentition were Class III. With increasing age, the number decreased to 3% in the mixed dentition.

In a study conducted by Guyer and coworkers²⁴ in 1986, a control group of 32 Class I individuals was compared with 144 Class III individuals. The samples were divided into four age categories: 5–7 years; 8–10 years; 11–13 years; and 13–15 years. Various morphological characteristics of Class III malocclusions were found in all four groups. The authors concluded that the unique skeletal and dental abnormalities were present at an early age, and though patients may become worse with age, they usually do not begin Class III development later in life.

Mitani and associates³³ looked at the growth of 34 untreated Japanese subjects with mandibular prognathism during the 3 years after the pubertal growth peak. They concluded that the morphologic characteristics of mandibular prognathism established before pubertal growth peak did not fundamentally change. However, their total growth increments were about the same as those with a normal mandible after the pubertal growth peak.

Prediction of a Class III skeletal pattern based on morphology can play an important step in orthodontic diagnosis and treatment planning. Johnston³⁴ proposed a simplified method of generating long-term forecasts by using a printed "forecast grid." This method employed mean-change expansion of a few cephalometric landmarks. The author stated that the grid may provide a simple introduction to growth prediction. However, a drawback to the grid system is that it does not fit a random series of patients nearly so well.

Aki et al.³⁵ proposed the use of the symphysis morphology as a prediction of the direction of mandibular growth. Results indicated that a mandible with an anterior growth direction was associated with a small height, large depth, small ratio, and large angle of the symphysis. A posterior growth direction was associated with a large height, small depth, large ratio, and small angle of the symphysis.

Schulhof and Bagba³⁶ compared a computer-derived growth forecast (Rocky Mountain Data Systems

(RMDS), Sherman Oaks, CA) with actual growth in 50 untreated patients ages 5 to 8.5 years. Approximately 10 years of cephalometric records were available for each patient. The results of the computer forecast were compared with three other methods of growth forecasting. The results indicated that the RMDS computer program was the most accurate in this study. The accuracy range of the prediction was from 70 to 80%.

In 1977, Schulhof and associates³⁷ studied 14 skeletal Class III patients in order to better predict which patients would grow more in the mandible than the cranial base. To predict normal or abnormal growth, the molar relationship, cranial deflection, porion location, and ramus positions were measured and compared with the norms and standard deviations. Using the RMDS program, if the sum of the deviations is greater than four, the computer warns the orthodontist of possible difficulty due to increased mandibular growth. The authors again reported an accuracy rate of 70–80%.

In an attempt to identify morphologic characteristics of the Class III skeletal pattern, Williams and Andersen³⁸ concluded by stating that “the diversity of skeletal patterns resulting in Class III relationships suggests the shortcomings of numeric predictive systems based on average incremental growth and a single formula.” In reviewing the current status of facial growth prediction, Houston³⁹ also stated that “in view of the variability of growth of most facial dimensions, detailed and accurate individualized growth prediction is not possible. The best that can be done is to base treatment planning on the existing facial pattern, allowing for average growth changes for the group to which the patient belongs.”

Early treatment of Class III malocclusion:

Joondeph⁴⁰ stated that “the objective of early orthodontic treatment is to create a more favorable environment for future dentofacial development. Interceptive treatment can reduce the amount of dental compensations to skeletal discrepancy that are often associated with a more severe malocclusion in late adolescence.” The goals of early interceptive treatment may include the following:^{40, 41}

1. To prevent progressive, irreversible soft-tissue or bony changes
2. To improve skeletal discrepancies and provide a more favorable environment for normal growth
3. To improve occlusal function
4. To enhance and possibly shorten phase II comprehensive treatment
5. To provide a more pleasing facial esthetic, thus improving the psychosocial development of the child.

In 1983, Campbell⁴¹ reviewed guidelines developed by Turpin (1981) for deciding when to intercept Class III malocclusion. The author recommended that early treatment should be considered for a patient who pre-

sents with characteristics listed as positive factors.

Positive Factors: Convergent facial type; AP functional shift; symmetrical condyle growth; young, with remaining growth; mild skeletal disharmony; good cooperation expected; no familial prognathism; good facial esthetics.

For individuals who present with characteristics listed as negative factors, Turpin suggested delaying treatment until growth is completed. He further stated that patients should always be aware that surgery may be necessary, even when an initial phase of treatment may be successful.

Negative Factors: Divergent facial type; no AP shift; asymmetrical growth; growth complete; severe skeletal disharmony; poor cooperation expected; familial pattern established; poor facial esthetics.

Early treatment of nonskeletal crossbites

Several intraoral appliances have been advocated for correction of nonskeletally related anterior crossbites. The fixed, inclined plane is strongly advocated by Croll and Riesenberger.²⁸ This appliance can correct the malocclusion rapidly with little concern about patient com-

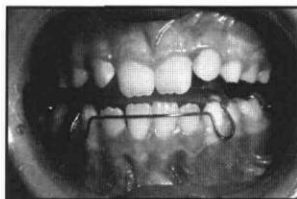

Fig 2. Bite ramp incorporated into a removable appliance for “jumping” an anterior crossbite.

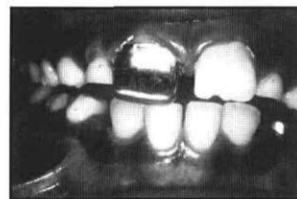


Fig 3. A reverse stainless-steel crown to correct a single tooth in anterior crossbite.

pliance when the inclined plane is cemented. The bite ramp (Fig 2) can easily be decorated to enhance patient’s acceptance. However, this appliance has several disadvantages.⁴² The force exerted on the ramp is unpredictable, patients may experience speech difficulty during treatment, and a potential for root damage exists due to the heavy, irregular forces placed on the tooth.

A reverse stainless-steel crown (Fig 3) can be used to correct anterior crossbite.²⁸ An oversized permanent lateral incisor preformed crown form is trimmed and contoured at the gingival margin to fit snugly over the maxillary primary tooth or teeth in crossbite. The crown is reverse-cemented (i.e., facial to the lingual) with polycarboxylate cement. One drawback is that some patients and parents find the stainless-steel crowns unattractive. With the advent of bonded resin composite, the stainless-steel crown can be replaced by bonded composite resin slopes for anterior tooth crossbite correction.⁴³

A tongue blade can be used for correction of a single tooth in crossbite. This method is very unpredictable

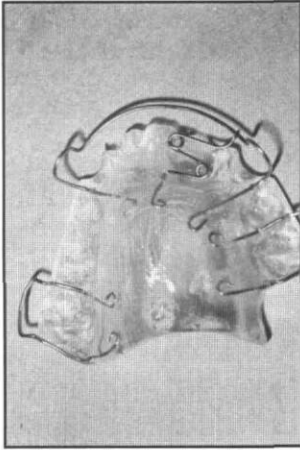


Fig 4. A removable appliance with auxiliary springs to correct one or two teeth in anterior crossbite.

The removable appliance with auxiliary springs (Fig 4) requires patient cooperation for successful treatment, but can be used successfully to move one or two teeth. This appliance is best used for mixed-to-permanent dentition.⁴²

The maxillary lingual arch with finger springs⁴² (Fig 5) is fabricated using an indirect technique. Bands are fitted on the maxillary second primary molars or the permanent first molars. An impression of the maxillary arch and bands is taken. Bands are transferred to the impression before pouring. A lingual arch is fabricated and soldered to the molar bands. Finger springs with helices are soldered to the lingual arch.

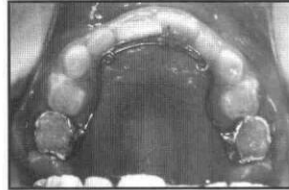


Fig 5. A maxillary lingual arch with finger springs to correct a single or multiple teeth in anterior crossbite.

and its effect is dependent upon the frequency of patient use and the patient's tolerance of discomfort. This is best applied to teeth with mobility, when a positive overjet can be obtained immediately.⁴²

Treatment of skeletal crossbites

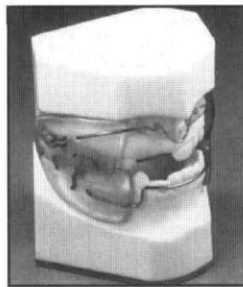


Fig 6. Functional regulator (FR-3) of Fränkel.

Functional regulator (FR-3) of Fränkel (Fig 6)

This appliance is designed to counteract the muscle forces acting on the maxillary complex.⁴⁴ Fränkel noted that the vestibular shields in the depths of the sulcus are placed away from the alveolar buccal plates of the maxilla to allow for forward development of the maxilla, whereas the shields are fitted closely to the

alveolar process of the mandible to hold or redirect growth posteriorly.⁴⁵

Robertson⁴⁶ followed 24 patients (12 Class II treated with FR-2 and 12 Class III treated with FR-3) for two years. The mean age range of the Class II group at the start of treatment was 11 years and 9.4 years in the Class III group. The principal treatment changes were den-toalveolar. Overjet corrections reported in the two groups were mostly due to crown tipping, with minimal changes of the skeletal structure.

Loh and Kerr⁴⁷ studied the lateral cephalometric radiographs of 20 patients treated with FR-3. No control group was used and the mean treatment time was 3.1 years \pm 1.9. The FR-3 appeared to effect occlusal changes by proclination of the upper maxillary incisors and retroclining of the mandibular incisors. The mandible was repositioned in a backward, downward direction, which in turn increased the facial height. Minimal change was noted in the maxilla. The authors concluded that the best indication for a good response to treatment with the FR-3 would be in a Class III malocclusion with an increased overbite of 4–5 mm and in younger, early mixed dentition patients.

McNamara and Huges⁴⁸ presented three case reports who were treated with the functional regulator, with two findings common among the three subjects. Mandibular growth was redirected in a vertical direction and the maxillary dentition moved forward. Variable responses were noted for the maxilla.

In a more recent study by Ulgen and Firatli,⁴⁹ 20 patients with functional Class III malocclusions were treated with FR-3. The control group, of comparable age to the treated sample, consisted of 20 subjects with functional Class III malocclusion. The patients in both groups were able to reposition their mandible backward into an anterior edge-to-edge position. The results showed a significant increase in the ANB angle in the treated group, mostly due to a decrease in SNB as the mandible rotated downward and backward. No significant changes in SNA were reported. The authors stated that the treatment period in this study was shorter compared to others, mainly because of poor patient cooperation.

In conclusion, the functional regulator of Fränkel may have some clinical application, particularly in patients with a potential for dental complications, problems of limited severity, and reduced facial height.⁴⁴ However, this appliance would not be the ideal choice for treatment of patients who present with maxillary anteroposterior deficiency as the primary etiology. Petit⁵⁰ and McNamara and Brudon⁴⁴ also recommend the use of FR-3 for retention after

protraction headgear therapy.

Chin cup therapy

The use of appliances resembling chin cups (Fig 7) to help reduce a prognathic mandible was reported as early as the 1800s. In an attempt to explain failure during early trials with the chin cup,

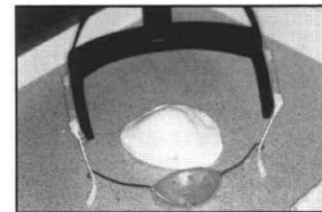


Fig 7. Chin cup appliance for modifying growth in patient with mandibular prognathism and vertical growing pattern.

Graber⁵¹ concluded that an inappropriate amount of force, little understanding of facial growth, and use of the chin cup after completion of skeletal growth

contributed to the failure.

In 1977, Graber⁵¹ treated 30 skeletal Class III Caucasian children, averaging 6 years of age, with chin cup therapy for a period of 3 years. An untreated Class III control was used for comparison. The author reported a posterior rotation of the mandible, a decreased gonial angle, a restriction in vertical condylar growth, and a clockwise rotation of the maxilla.

Mitani and Sakamoto⁵² also reported similar results. Though only three Japanese females were followed, growth direction was altered downward and backward in the patients with the use of the chin cup.

Asano⁵³ found a decrease in the anteroposterior length of the mandible in a study of 80 4-week-old male Wistar rats treated with mandibular retraction device, compared to the 100-member control group. No "catch up" growth behavior was noted in the experimental group. Overall growth of the growing rats' mandibles was retarded, however no effect on the growth behavior was noted after appliance removal.

In 1986, Mitani and Fukazawa⁵⁴ evaluated the effects of orthopedic force coincident with the growth changes of the mandible during the pubertal period to compare a treated group of 21 Japanese females to a Class III control group of comparable age. The patients were examined in three stages: prepeak; peak; and postpeak. Some incremental growth of the mandible accompanied use of the chin cup in all three stages. Because the peak stage showed the greatest incremental change, the author concluded that orthopedic force does not alter the basic growth timing of the mandible. The thickness of the mandibular symphysis also decreased during chin cup therapy. Lastly, the authors stated that the complete inhibition of mandibular growth is difficult to achieve and that individual reactions to the chin cup force varied.

A study by Ishii et al.⁵⁵ evaluated the effects of the protraction headgear in conjunction with the chin cup. Lateral cephalograms of 63 Japanese patients, averaging 10.75 years of age were analyzed. The authors found significant movement of the maxilla in the forward direction with a counterclockwise rotation of the nasal floor. The maxilla moved forward in an average of 2.104 mm and ANS moved upward by 0.137 mm. Changes in the mandible included a backward and downward redirection. The mandible moved backward and downward by 2.035 mm. Thus the maxilla and mandible contributed equally to the correction of the anteroposterior jaw relationship.

In 1986, Ritucci and Nanda⁵⁶ focused on the effects of chin cup on the maxilla and cranial base. Though the sample sizes of the treated and control groups were small (10 treated Class III patients and 7 untreated Class I controls), their findings were similar to those reported in a later study by Sugawara et al.⁵⁷ Ritucci and Nanda reported a clockwise rotation of the maxilla with minimal downward vertical growth. Similar to the results of Sugawara et al.,⁵⁷ the chin cup has no effect on the

anteroposterior growth of the midface. Proclination of the maxillary incisors was common, most likely due to occlusal interferences, going from a negative to a positive overjet. The authors also found that the cranial flexure angle (N-S-Ba) was also decreased.

Sugawara et al.⁵⁷ recently published a report on the long term effects of chin cup therapy on three groups of Japanese girls who started chin cup treatment at 7, 9, and 11 years. All three groups were followed by serial lateral head films taken at the ages of 7, 9, 11, 14, and 17 years. The authors found no effect of the chin cup in the anteroposterior direction of the maxilla. The skeletal profile showed great improvement during the initial stages of chin cup therapy. Patients who entered treatment at an earlier age showed a so-called catch-up manner of mandibular displacement in a forward and downward direction before growth was completed. The authors concluded that chin cup therapy did not necessarily guarantee positive correction of skeletal profile after completion of growth.

A more recent article by Allen and co-workers⁵⁸ described the use of the chin cup in conjunction with an upper, removable appliance. An average difference in overjet of 6.89 mm between the treated and control groups was present prior to start of treatment. The authors reported that correction of the Class III relationship was attributed to proclination of upper incisors, retroclination of lower incisors, and downward movement of the mandible. Though improvements were noted, the ANB angle did not change appreciably. The authors questioned whether the chin cup does or does not bring about a change in the anteroposterior jaw relationship.

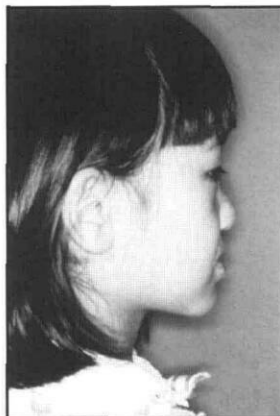In summary, attempts to restrict mandibular growth using chin cup therapy have shown different results. Sugawara et al.⁵⁷ stated that clinicians "should not overestimate the effects of a chin cup appliance to correct skeletal facial profiles" and concluded that "a chin cup should be applied within limitations on the basis of proper diagnosis and treatment objectives." For patients with skeletal Class III malocclusion due primarily to maxillary anteroposterior deficiency, the chin cup therapy would not address the underlying problem.^{56, 57}

Protraction headgear treatment

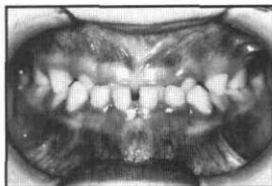Protraction headgear, in conjunction with a palatal expansion appliance (Fig 8 A-H) has been used to correct patients with maxillary deficiency and/or mandibular prognathism.^{29, 55, 59-63} Dramatic skeletal changes can be obtained in animals with continuous protraction forces to the maxilla.⁶⁴⁻⁶⁸ In human studies, the individual most responsible for reviving the interest in this technique was Delaire.⁶⁹ More recently, Petit⁵⁰ modified Delaire's basic concepts by increasing the amount of force generated by the appliance, thus decreasing the overall treatment time.

In 1944, Oppenheim⁷⁰ stated that one cannot control

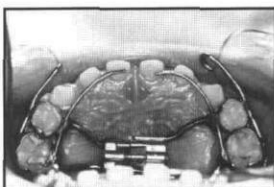
Fig 8. Protraction headgear in conjunction with fixed expansion appliance to correct skeletal crossbites.



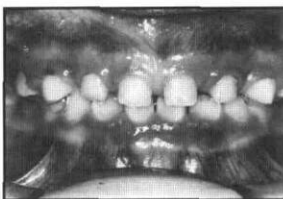A. Pretreatment profile of a 5-year-old girl with maxillary incisors.



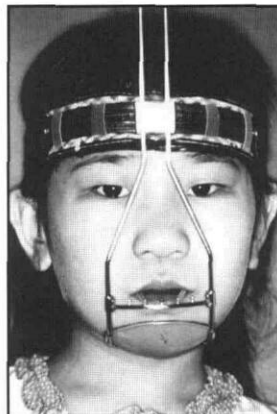
B. Intraoral photograph showing anterior crossbite of all maxillary incisors.



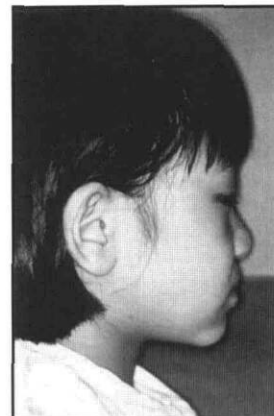
C. Maxillary expansion appliance with labial wire extending to the canine region for maxillary protraction.



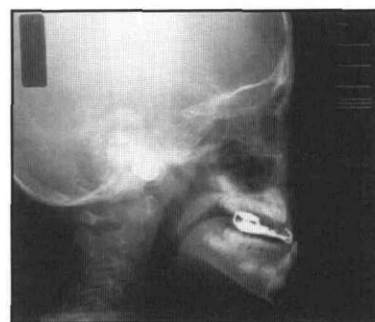F. Intraoral photograph showing correction of anterior crossbite.



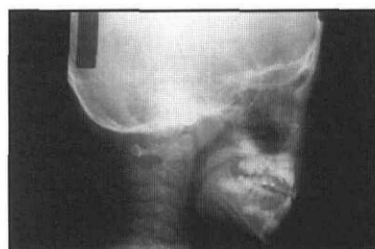D. Protraction headgear with elastics (14 oz per side) protracting at 30° to occlusal plane.



E. Post-treatment profile. Note the improvement in facial convexity.



G. Pretreatment lateral cephalogram showing skeletal Class III malocclusion.



H. Post-treatment lateral cephalogram showing improvement in anteroposterior skeletal relationship.

the growth or anterior displacement of the mandible. He suggested moving the maxilla forward in hope of counterbalancing mandibular protrusion. Haas⁷¹ showed displacement of the maxilla downward and forward with the use of palatal expansion. Several clinical studies have noted that maxillary protraction was enhanced when used in conjunction with a palatal expander.^{29, 59-61, 71} Palatal expansion may "disarticulate" the maxilla and initiate cellular response in the suture, allowing a more positive reaction to protraction forces.^{72, 73}

Nanda⁷² demonstrated the use of modified protraction headgear in patients prior to their adolescent growth spurt. A combination of rapid palatal expansion and/or the use of the chin cup was often combined with use of the protraction headgear. The author reported favorable results after 4-8 months of protraction headgear treatment. The maxilla and dentition were anteriorly displaced 1-3 and 1-4 mm, respectively.

Wisth and colleagues⁶² evaluated lateral cephalograms of 22 Class II children, aged 5-10 years, treated with protraction facemasks. They compared them at pretreatment, after 3-12 months of treatment, and after an observation period of 6-48 months, with a control group of individuals with normal occlusion. Treatment results for 18 children showed a significant decrease in mandibular prognathism and a correction of the overjet. The changes observed during retention were found to be comparable to the control groups. The authors concluded that maxillary protraction had a normalizing effect not only on the negative overjet but

on the general facial morphology.

McNamara⁵⁹ and Turley²⁹ reported similar findings with a bonded, maxillary-expansion appliance and protraction headgear. Treatment resulted in anterior movement of the maxilla, downward and backward rotation of the mandible, increased lower facial height, and overall improvement of soft-tissue contour.

Takada and colleagues⁷⁴ treated 61 female Japanese children with a modified maxillary protraction headgear and chin cup. The treatment group was divided into three categories: prepubertal (7-10 years);

midpubertal (10–12 years); and late pubertal (12–15 years) with average treatment time of 1.1, 1.0, and 1.4 years, respectively. They reported a significant increase in maxillary length for the prepubertal and mid-pubertal groups. The results were not as significant in the late pubertal group.

Ngan and colleagues⁶¹ found similar results in Chinese Class III patients treated with maxillary expansion and protraction. Six months of treatment resulted in correction of negative overjet and molar relationship. The maxilla moved anteriorly and the mandible rotated posteriorly. The authors noted a significant improvement in facial profile, which added to the benefit of early orthopedic intervention.

Fixed comprehensive appliance therapy and surgical correction

Skeletal discrepancies that cannot be resolved during mixed dentition by growth modification may require comprehensive appliance therapy and/or surgical correction. Treatment of Class III malocclusion in adolescence is indicated in many instances to alleviate the potential psychosocial problems, prevent the problem from becoming too severe, and perhaps reduce the need for surgery. However, some cases that are apparently rendered during childhood recur during the adolescent growth spurt. The strategies of Class III treatment⁷⁵ in adolescence include

- Forward displacement of the midface
- Inhibition of mandibular growth
- Redirection of mandibular growth
- Dental and alveolar process repositioning.

The choice of strategies is dependent on facial morphology and estimates of the duration of growth. Cases of midface deficiency are best treated with face-mask orthopedics combined with fully bracketed arches in both jaws. The long-term prognosis of this treatment is unknown. Mandibular prognathism alone may be treated with chin cup therapy to inhibit mandibular growth, but this has limited potential. Class III elastics and extractions sometimes permit mild mandibular prognathisms to be camouflaged by tooth movements and alveolar process repositioning, but this treatment, along with face masks and chin cups, is limited to mild-to-severe problems.

For patients with continued disproportional sagittal and vertical growth, or Class III patients with mandibular excess combined with a divergent facial pattern, there are no good nonsurgical treatment solutions. Such patients are outside the "envelope of discrepancy" proposed by Proffit and Ackerman.⁷⁶ Early surgery is an alternative solution, but surgical intervention in the maxilla in a young child has the potential to reduce growth that is already likely to be somewhat deficient.⁷⁷ Patients with true mandibular prognathism may continue to grow for several years beyond puberty. Therefore, continuing mandibular growth must be assumed until two lateral cephalograms taken at least 1 year

apart show no demonstrable growth. The current surgical methods for correcting skeletal Class III problems are ramus osteotomy to set back a prognathic mandible, mandibular inferior border osteotomy to reduce chin height and/or prominence,⁷⁸ and/or LeFort I osteotomy to advance a deficient maxilla, often with segmentation to allow transverse expansion.

Conclusions

The ability to differentiate between pseudo Class III malocclusion and true skeletal Class III malocclusion can help clinicians formulate early treatment for these patients. This paper presents a diagnostic scheme to differentiate between dental and skeletal crossbites based on dental and functional assessments. Several intraoral appliances have proved to be successful in eliminating dental crossbites. However, treatment of skeletal crossbites remains a continuous challenge to the profession. Due to the diversity and variability in facial growth, accurate individualized growth prediction is not possible at the moment. Treatment directed at the mandible seems to invite relapse during the pubertal growth period. Treatment directed at the maxilla shows promising results but awaits long-term clinical results following the early orthopedic intervention.

Dr. Ngan is Professor and Chair, Department of Orthodontics, West Virginia University, School of Dentistry. Dr. Hu is in private practice in Olnui, Maryland. Dr. Fields, Jr. is Professor and Dean, The Ohio State University, College of Dentistry.

1. Ainsworth NJ: The incidence of dental disease in the children. In Medical Research Council: Reports of the Committee for the Investigation of Dental Disease, Special Report Series, No. 97, 1925.
2. Bjork A: The face in profile: An anthropological X-ray investigation of Swedish children and conscripts. Lund: Berlingska Boktryckeriet 40:58, 1947.
3. Humphreys HF, Leighton BC: A survey of anteroposterior abnormalities of the jaws in children between the ages of two and five and a half years of age. *Brit D J* 88:3–15, 1950.
4. Massler M, Fränkel JM: Prevalence of malocclusion in children aged 14–18 years. *Am J Orthodont* 37:751–68, 1951.
5. Huber RE, Reynolds JW: A dentofacial study of male students at the University of Michigan in the physical hardening program. *Am J Orthodont Oral Surg* 32:1–21, 1946.
6. Newman GV: Prevalence of malocclusion in children six to fourteen years of age and treatment in preventable cases. *JADA* 52:566–75, 1956.
7. Goose DH, Thomson DG, Winter FC: Malocclusion of school children of the West Midlands (England). *Brit D J* 102:174–78, 1957.
8. Ast DB, Carlos JP, Cons NC: The prevalence and characteristics of malocclusion among senior high school students in upstate New York. *Amer J Orthodont*, 51:437–45, 1965.
9. Hill IN, Blayney JR, Wolf W: The Evanston dental caries study. XIX. Prevalence of malocclusion of children in a fluoridated and control area. *J D Res*, 38:782–94, 1959.
10. Altemus LA: Frequency of the incidence of malocclusion in American Negro children aged twelve to sixteen. *Angle Orthodont* 29:189–200, 1959.
11. Garner LD, Butt MH: Malocclusion in black American and Nyeri Kenyans. An epidemiologic study. *Angle Orthodont* 55:139–46, 1985.
12. Horowitz HS, Doyle J: Occlusal relations in children born and reared in an optimally fluoridated community. II. Clini-

- cal findings. *Angle Orthodont* 40:104-11, 1970.
13. Emrich RE, Brodie AG, Blayney JR: Prevalence of Class 1, Class 2, and Class 3 malocclusions (Angle) in an urban population. An epidemiological study. *J Dent Res* 44:947-53, 1965.
 14. Iwagaki H: Hereditary influence of malocclusion. *Am J Orthodontica* 24:328-36, 1938.
 15. Ishii H, Morita S, Takeuchi T, Nakamura S: Treatment effect of combined maxillary protraction and chin cup appliance in severe skeletal Class III cases. *Am J Orthod Dentofacial Orthop* 92: 304-12, 1987.
 16. Allwright WC, Bundred WH: A survey of handicapping dentofacial anomalies among Chinese in Hong Kong. *Internat D J* 14:505-19, 1964.
 17. Litton SF, Ackermann LV, Isaacson RJ, Shapiro BL: A genetic study of Class 3 malocclusion. *Am J Orthod* 58:565-77, 1970.
 18. Harris JE, Kowalski CJ, Watnick SS: Genetic factors in the shape of the craniofacial complex. *Angle Orthod* 43:107-11, 1973.
 19. Jacobson A, Evans WC, Preston CB, Sadowsky PL: Mandibular prognathism. *Am J Orthod* 66:140-71, 1974.
 20. McGuigan DG: *The Hapsburgs*. London, WH Allen, 1966.
 21. Rakosi T, Schilli W: Class III anomalies: a coordinated approach to skeletal, dental, and soft tissue problems. *J Oral Surg* 39:860-70, 1981.
 22. Proffit WR, Fields HW: *Contemporary Orthodontics*, 2nd ed. pp 134-36, 1993.
 23. Ellis E 3rd, McNamara JA Jr.: Components of adult Class III malocclusion. *J Oral Maxillofac Surg* 42:295-305, 1984.
 24. Guyer EC, Ellis EE 3rd, McNamara JA Jr., Behrents RG: Components of class III malocclusion in juveniles and adolescents. *Angle Orthod* 56:7-30, 1986.
 25. Simon L, Tullock C, Phillips C, Fields H: Frequency of reporting measures of Class II malocclusions. *International Dent J* 73:347, 1953, 1993.
 26. Shuen S, Ngan P, Fields H, Beck M: Accuracy and reliability of diagnosing Class III malocclusion in young patients. *J Dent Res* 74:139 [ABSTR #1024], 1995.
 27. Vadiakas G, Viazis AD: Anterior crossbite correction in the early deciduous dentition. *Am J Orthod Dentofacial Orthop* 102:160-62, 1992.
 28. Croll TP, Riesenberger RE: Anterior crossbite correction in the primary dentition using fixed inclined planes. I. Technique and examples. *Quintessence Int* 18:847-53, 1987.
 29. Turley PK: Orthopedic correction of Class III malocclusion with palatal expansion and custom protraction headgear. *J Clin Orthod* 22:314-25, 1988.
 30. Thompson JR: The individuality of the patient in facial skeletal growth. Part 2. *Am J Orthod Dentofacial Orthop* 105:117-27, 1994.
 31. Enlow DH: *Handbook of Facial Growth*, 2nd ed. WB Saunders Co, Philadelphia, PA, 1982.
 32. Dietrich UC: Morphological variability of skeletal Class 3 relationships as revealed by cephalometric analysis. *Rep Congr Eur Orthod Soc* 131-43, 1970.
 33. Mitani H, Sato K, Sugawara J: Growth of mandibular prognathism after pubertal growth peak. *Am J Orthod Dentofacial Orthop* 104:330-36, 1993.
 34. Johnston LE: A simplified approach to prediction. *Am J Orthod* 67:253-57, 1975.
 35. Aki T, Nanda RS, Currier GF, Nanda SK: Assessment of symphysis morphology as a predictor of the direction of mandibular growth. *Am J Orthod Dentofacial Orthop* 106:60-69, 1994.
 36. Schulhof RJ, Bagha L: A statistical evaluation of the Ricketts and Johnston growth-forecasting methods. *Am J Orthod* 67:258-276, 1975.
 37. Schulhof RJ, Nakamura S, Williamson WV: Prediction of abnormal growth in class III malocclusions. *Am J Orthod* 71:421-30, 1977.
 38. Williams S, Andersen CE: The morphology of the potential Class III skeletal pattern in the growing child. *Am J Orthod* 89:302-11, 1986.
 39. Houston WJ: The current status of facial growth prediction: a review. *B J Orthod* 6:11-17, 1979.
 40. Joondeph DR: Early orthodontic treatment. *Am J Orthod Dentofacial Orthop* 104:199-200, 1993.
 41. Campbell PM: The dilemma of Class III treatment. Early or late? *Angle Orthod* 53:175-91, 1983.
 42. Payne RC, Mueller BH, Thomas HF: Anterior cross bite in the primary dentition. *J Pedod* 5:281-94, 1991.
 43. Croll TP: Correction of anterior tooth crossbite with bonded resin-composite slopes. *Quintessence Int* 27:7-10, 1996.
 44. McNamara JA, Brudon WL: *Orthodontic and orthopedic treatment in the mixed dentition*. Ann Arbor: Needham Press Inc., 1993.
 45. Fränkel R: Maxillary retrusion in Class 3 and treatment with the function corrector 3. *Rep Congr Eur Orthod Soc* 249-59, 1970.
 46. Robertson NR: An examination of treatment changes in children treated with the function regulator of Fränkel. *Am J Orthod* 83:299-310, 1983.
 47. Loh MK, Kerr WJ: The Function Regulator III: effects and indications for use. *B J Orthod* 12:153-57, 1985.
 48. McNamara JA Jr., Hulse SA: The functional regulator (FR-3) of Fränkel. *Am J Orthod* 88: 409-24, 1985.
 49. Ulgen M, Firatli S: The effects of Fränkel's function regulator on the Class III malocclusion. *Am J Orthod Dentofacial Orthop* 105:561-67, 1994.
 50. Petit H: Adaptations following accelerated facial mask therapy, in clinical alteration of the growing face, JA McNamara, Jr. KA Ribbens and RP Howe, eds, *Monograph 14, Craniofacial Growth Series, Center for Human Growth and Development, University of Michigan, Ann Arbor, 1983*.
 51. Graber LW: Chin cup therapy for mandibular prognathism. *Am J Orthod* 72:23-41, 1977.
 52. Mitani H, Sakamoto T: Chin cap force to a growing mandible. Long-term clinical reports. *Angle Orthod* 54:93-122, 1984.
 53. Asano T: The effects of mandibular retractive force of the growing rat mandible. *Am J Orthod Dentofacial Orthop* 90:464-74, 1986.
 54. Mitani H, Fukazawa H: Effects of chin cap force on the timing and amount of mandibular growth associated with anterior reversed occlusion (Class III malocclusion) during puberty. *Am J Orthod Dentofacial Orthop* 90:454-63, 1986.
 55. Ishii H, Morita S, Takeuchi Y, Nakamura S: Treatment effect of combined maxillary protraction and chin cap appliance in severe skeletal Class III cases. *Am J Orthod Dentofacial Orthop* 92:304-12, 1987.
 56. Ritucci R, Nanda R: The effect of chin cup therapy on the growth and development of the cranial base and midface. *Am J Orthod Dentofacial Orthop* 90:475-83, 1986.
 57. Sugawara J, Asano T, Endo N, Mitani H: Long-term effects of chin cap therapy on skeletal profile in mandibular prognathism. *Am J Orthod Dentofacial Orthop* 98:127-33, 1990.
 58. Allen RA, Connolly IH, Richardson A: Early treatment of Class III incisor relationship using the chin cap appliance. *Eur J Orthod* 15:371-76, 1993.
 59. McNamara JA Jr.: An orthopedic approach to the treatment of Class III malocclusion in young patients. *J Clin Orthod* 21:598-608, 1987.
 60. Ngan P, Wei SH, Hagg U, Yiu CK, Merwin D, Stickel B: Effect of protraction headgear on Class III malocclusion. *Quintessence Int* 23:197-207, 1992.
 61. Ngan P, Hägg U, Merwin D, Yiu C, Wei SH: Soft tissue and dentoalveolar profile changes associated with maxillary expansion and protraction headgear treatment. *Am J*

- Orthod Dentofacial Orthop 109:38-49, 1996.
62. Wirth PJ, Tritrapunt A, Rygh P, Boe OE, Norderval K: The effect of maxillary protraction on front occlusion and facial morphology. *Acta Odontol Scand*, 45:227-37, 1987.
 63. Mermigos J, Full CA, Andreasen G: Protraction of the maxillofacial complex. *Am J Orthod Dentofacial Orthop* 98:47-55, 1990.
 64. Jackson GW, Kokich VG, Shapiro PA: Experimental and postexperimental response to anteriorly directed extraoral force in young *Macaca nemestrina*. *Am J Orthod* 75:319-33, 1979.
 65. Kambara T: Dentofacial changes produced by extraoral forward force in the *Macaca irus*. *Am J Orthod* 71:249-77, 1977.
 66. Nanda R: Differential response of midfacial sutures and to bones to anteriorly directed extraoral forces in monkeys. *J Dent Res* 57, 1978, Spec Iss p 362 [ABSTR#1150].
 67. Nanda R: Protraction of maxilla in rhesus monkeys by controlled extraoral forces. *Am J Orthod* 74:121-41, 1978.
 68. Dellinger EL: A preliminary study of anterior maxillary displacement. *Am J Orthod* 63:509-16, 1973.
 69. Delaire J: Confection du masque orthopedique. [Manufacture of the "orthopedic mask."] *Rev Stomatol Chir Maxillofac* 72:579-82, 1971.
 70. Oppenheim A: A possibility for physiologic orthodontic movement. *Am J Orthodont Oral Surgery* 30:227-328, 345-68, 1944.
 71. Haas AJ: Palatal expansion: just the beginning of dentofacial orthopedics. *Am J Orthod* 57:219-55, 1970.
 72. Nanda R: Biomechanical and clinical considerations of a modified protraction headgear. *Am J Orthod* 78:125-39, 1980.
 73. Bell RA: A review of maxillary expansion in relation to rate of expansion and patient's age. *Am J Orthod* 81:32-37, 1982.
 74. Takada K, Petdachai S, Sakuda M: Changes in dentofacial morphology in skeletal Class III children treated by a modified maxillary protraction headgear and a chin cup: a longitudinal cephalometric appraisal. *Eur J Orthod* 15:211-21, 1993.
 75. Moyers, RE. Adolescent treatment. In *Handbook of Orthodontics*, Moyers RE, ed, Year-Book Medical Publishers, Inc., 4th Ed, Chicago, 1988, pp 456.
 76. Proffit WR, Ackerman JL: A systematic approach to orthodontic diagnosis and treatment planning. In *Current Orthodontic Concepts and Techniques*, Graber TM, Swain BF, eds, The CV Mosby Co., 3rd Ed, St. Louis, 1985.
 77. Kokich V, Shapiro P: The effects of LeFort I osteotomies on the craniofacial growth of juvenile *Macaca Nemestrina*. In *The Effect of Surgical Intervention on Craniofacial Growth*. McNamara JA Jr., Carlson DS, Ribbens KA, eds, Monograph 12, Craniofacial Growth Series, Center for Human Growth and Development, Ann Arbor: University of Michigan, pp 131-41, 1982.
 78. Sinclair PM, Proffit WR: Class III problems: Mandibular excess/maxillary deficiency. In *Surgical-Orthodontic Treatment*, Proffit WR, White RP, eds, Mosby Year-Book, St. Louis, 1990, pp 441.
-

Earn CE credits while you read this journal



Earn credits from your home on your own time. No need to travel; no long lectures to attend. *Pediatric Dentistry* now offers up to 18 continuing education credits per year for demonstrating an understanding of topics discussed in selected journal articles.

It couldn't be easier! As a subscriber, you will receive a multiple-choice test covering several articles around the same time you receive the journal. Simply read the selected articles and return your answer sheets to AAPD for grading. We will notify you of the number of credits you earned for your correct answers.

The CE logos on the cover of the journal and on the title pages indicate which articles will be tested. Annual subscription price is \$60.

A related service, the Continuing Education Registry, helps you keep track of your CE credits. Subscribers will receive reporting forms on which to record continuing education credits. For \$30 per year, credit information submitted to AAPD will be entered into a confidential record. Reports will be furnished annually or by request. If you subscribe to both services, your journal CE credits will be entered automatically into the CE Registry.