



## Birooted primary canines: report of three cases

Norman W. Ott, DMD    Randall N. Ball, DMD

**B**irooted primary canines have been reported only a few times,<sup>1-3</sup> are considered very rare, and have only been diagnosed following radiographic examination. In every report, the birooted teeth have been bilateral and involve the maxillary primary canines, with one report of additional involvement of the mandibular primary canines. There appears to be no sexual predilection, and all but one case occurred in black children and in children with otherwise normal dentitions. Bimstein and Bystrom<sup>4</sup> and Bryant and Bowers<sup>5</sup> reported the patients' siblings to have normal canines. A summary of the previous cases is presented in the Table. The cause of this phenomenon is unknown but is associated with the development of Hertwig's epithelial root sheath.

This article presents three additional cases of birooted primary canines, including the first reported case of birooted mandibular primary canines in a black child.

### Case one

An 8-year 6-month-old black male was first seen for emergency dental care of the maxillary right primary first molar. The child's medical history was unremark-

able for trauma, allergies, or previous medical problems. The dental history included two amalgam restorations and odontalgia of 2 days duration prior to this visit. Clinical and radiographic examinations were performed, and the painful maxillary right primary first molar was extracted. On the radiographic examination, bilateral, birooted, maxillary primary canines were noted (Fig 1a & 1b). Their clinical crowns were normal color and shape. Crown sizes also were normal, as the mesiodistal measurements of the maxillary right and left primary canines were 7.0 mm and 7.1 mm, respectively. Teeth numbers 1, 4, 12, 13, 16, 17, 19, 20, 24, 25, 29, 30, and 32 were not developing or clinically detectable, but single rooted permanent maxillary canines were developing normally and were well positioned. Maxillary permanent lateral incisors had erupted without interference from the primary canine roots. Panoramic radiographs of an older sister showed a normal adult dentition, with one early radiograph demonstrating a normal primary maxillary canine.

### Case two

A 4-year 11-month-old black male presented for

TABLE. PREVIOUSLY REPORTED CASES OF BIROOTED CANINES

<i>Author/Year</i>	<i>Age (yr)</i>	<i>Sex</i>	<i>Race</i>	<i>Teeth</i>	<i>Clinical Characteristics</i>	<i>Siblings</i>
Brown (1975)	4	F	Not reported	Max	Normal clinical crowns; other oral structures normal	Not reported
Kelly (1978)	5	F	Black	Max	Normal clinical crowns; mandibular canines normal	Not reported
Krolls and Donohue (1980)	5	F	Black	Max	Normal clinical dentition	Not reported
Bimstein and Bystrom (1982)	5	M	Black	Max	Normal clinical dentition	Sister (13 yr): normal permanent teeth
Bryant and Bowers (1982)	5	M	Caucasian	Max/Mand	Normal appearance; no other anomalies	Two older sisters: normal permanent teeth

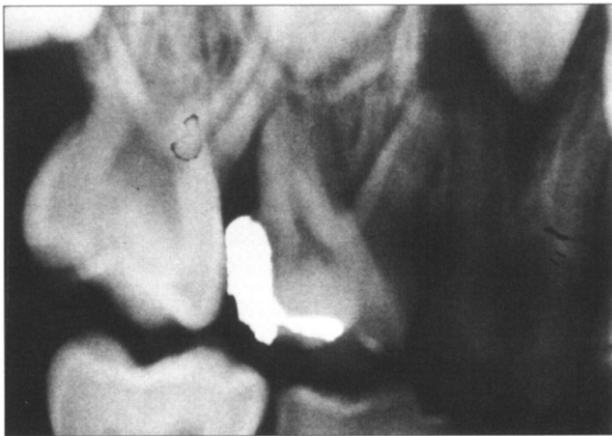


Fig 1a. Case 1: Maxillary right primary canine.

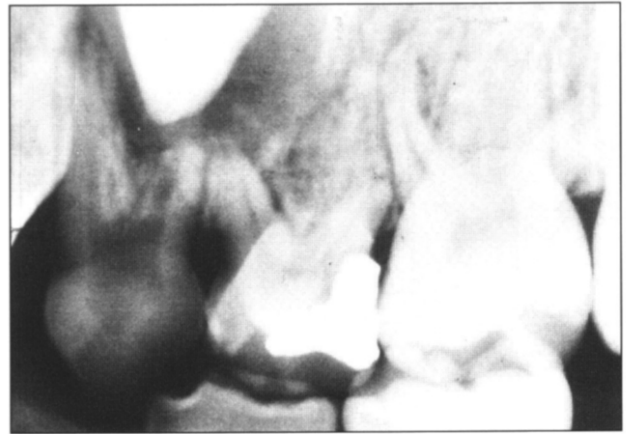


Fig 1b. Case 1: Maxillary left primary canine.

dental examination 1 year after extensive restoration under general anesthesia. The child's medical history was unremarkable for trauma, allergies, or previous medical problems. The dental treatment history included molar pulpotomies, nine stainless steel crowns, extraction of the maxillary incisors, and a space maintainer. Clinical and radiographic examinations revealed bilateral, birooted, maxillary primary canines (Figs. 2a & 2b). Restorations prevented classification of color,

nines in both arches and normally positioned permanent canines and maxillary lateral incisors. The primary canine crowns were normal in color, shape, and size. The maxillary right and left primary canines measured 7.5 mm and 7.3 mm respectively, and the mandibular right and left primary canines each measured 6.5 mm mesiodistally. The child has no siblings, and the parents reported no knowledge of birooted canines in other family members.

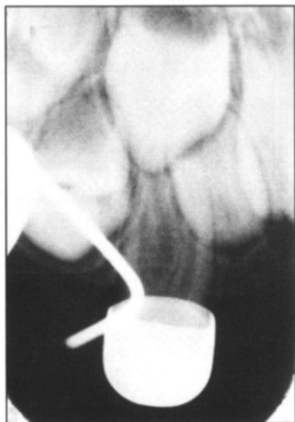

Fig 2a. Case 2: Maxillary right primary canine.

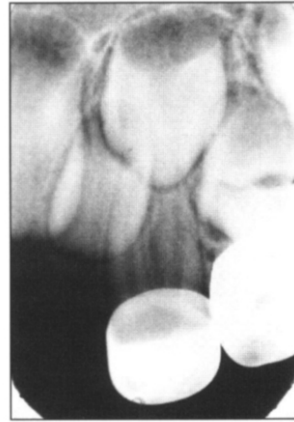

Fig 2b. Case 2: Maxillary left primary canine.

shape, or size of their clinical crowns. The remaining dentition was normal. This child's one sibling, an older sister, had a single panoramic radiograph demonstrating normal primary canines.

### Case three

An 8-year 4-month-old black male presented for routine examination with a chief complaint of "wide spaces in his front teeth". Medical and dental histories were noncontributory. Clinical examination of the mixed dentition showed an age-appropriate mixed dentition with no anatomic abnormalities. A panoramic radiograph (Fig 3) revealed bilateral primary birooted canines in both the maxilla and mandible. Also noted were normally developing single-rooted permanent ca-

### Discussion

Case one represents the first report of birooted primary canines with additional dental anomalies. Although dental anomalies have been associated with numerous syndromes, all three children were healthy and without evidence of other physical abnormalities, except for the absence of 13 permanent teeth in this first case.

Case three represents the first report of mandibular birooted primary canines in a black child, and only the second report in the literature. Case reports suggest that birooted primary canines may be more prevalent in black children.

The influence of the additional root upon crown morphology was assessed by measuring the mesiodistal dimensions of the affected teeth. There was no elon-

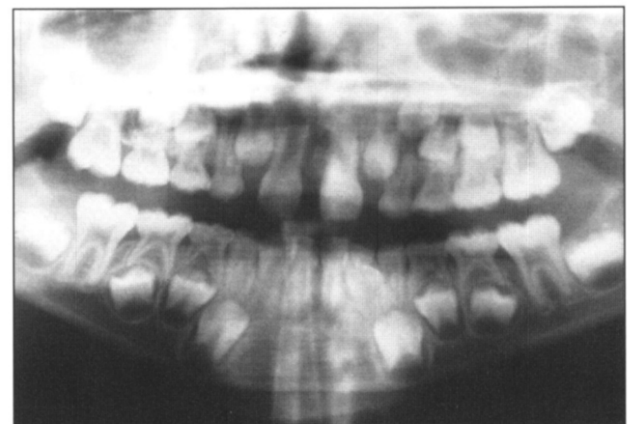

Fig 3. Case 3: Maxillary and mandibular primary canines.

gation of the crowns mesiodistally, and all crowns measured were considered to have normal dimensions.

In the permanent dentition supernumerary roots are not uncommon, with normally single-rooted permanent premolars and canines being particularly affected.<sup>6</sup> Reports of similar occurrences in the primary dentition are rare. In addition to the five individual cases previously reported for birooted primary canines, a single report documents seven Caucasian children with bilateral supernumerary rooted primary central incisors<sup>7</sup>, and three case reports identify supernumerary roots in mandibular first primary molars.<sup>8-10</sup>

The mechanism for normal development of multiple roots is well known. From the cervical loop of the dental organ, the inner and outer enamel epithelia proliferate as a double layer of cells known as Hertwig's epithelial root sheath. The outer and inner enamel epithelia bend at the future cemento-enamel junction, creating the epithelial diaphragm. The rim of this sheath encloses the primary apical foramen. In multirooted teeth, an unknown factor stimulates continued morphodifferentiation. By differential growth, tongue-like extensions of the horizontal diaphragm develop, grow toward each other, and fuse. For each new secondary apical foramen, a root will develop.<sup>11</sup>

Of the 20 birooted primary canines reported to date, all demonstrate root furcations in the coronal third. Their biroot formation, beginning between 9 and 10 months postnatally, may result from an enhanced expressivity of the gene initiating differential growth of Hertwig's epithelial root sheath in multirooted teeth. Although trauma or other disturbances in morphodifferentiation may affect root form and size in later periods,<sup>12</sup> early trauma would not explain the appearance of bilateral birooted primary canines. The findings of Morrow and Hylin,<sup>7</sup> whose primary central incisors all demonstrated bifurcation only in the apical fourth of the roots, suggest that the potential for developing supernumerary roots is present throughout the course of root elongation.

Although these primary canines may resorb and exfoliate without incident, potential exists for interference with eruption of the adjacent permanent teeth. If found, the anomaly should be described to parents. There is no clear or compelling rationale advocating interim radiographs, but follow-up examination around the time of exfoliation is appropriate when evidence of clinical abnormality exists.

Dr. Ott is LTC, Dental Corps and assistant director, US Army Pediatric Dentistry Residency Program, Fort George G. Meade, Maryland. Dr. Ball is LTC, Dental Corps, and chief, Pediatric Dentistry, Fort Irwin, California.

This article is a work of the United States Government and may be reproduced without permission. Opinions expressed herein, unless otherwise specifically indicated, are those of the authors, and do not purport to express views of the United States Army or any other Department or Agency of the United States Government (para. 4-3, AR 360-5).

1. Brown CK: Bilateral bifurcation of the maxillary deciduous cuspids. *Oral Surg* 40:817, 1975.
2. Kelly JR: Birooted primary canines. *Oral Surg* 46:872, 1978.
3. Krolls SO, Donahue AH: Double-rooted maxillary primary canines. *Oral Surg* 49:379, 1980.
4. Bimstein E, Bystrom EB: Birooted bilateral maxillary primary canines. *ASDC J Dent Child* 49:217-18, 1982.
5. Bryant RH, Bowers DF: Four birooted primary canines: report of a case. *ASDC J Dent Child* 49:441-42, 1982.
6. Shafer WG, Hine MK, Levy BM: *Textbook of Oral Pathology*, 3rd Ed. Philadelphia: WB Saunders Co, 1974, p 40.
7. Morrow JW, Hylin DL: Supernumerary rooted primary central incisors: report of seven cases. *ASDC J Dent Child* 60:337-38, 1993.
8. Falk WV, Bowers DF: Bilateral three-rooted mandibular first primary molars: report of case. *ASDC J Dent Child* 50:136-37, 1983.
9. Badger GR: Three-rooted mandibular first primary molar. *Oral Surg* 3:547, 1982.
10. Acs G, Pokala P, Cozzi E: Shovel incisors, three-rooted molars, talon cusp, and supernumerary tooth in one patient. *Pediatr Dent* 14:263-64, 1992.
11. ten Cate AR: *Oral Histology: Development, Structure, and Function*, 2nd Ed. St. Louis: CV Mosby Co, 1985, pp 69-72.
12. Sicher H, Bhaskar SN: *Orban's Oral Histology and Embryology*, 7th Ed. St. Louis: CV Mosby Co, 1972, pp 31-36.