

Treatment of multiple tooth ankylosis with removable prosthesis: case report

Kyle E. Pedersen, DDS Kerrod B. Hallett, MDSc, FRACDS

Introduction

Ectodermal dysplasia is a hereditary disorder characterized by the absence or defect of two or more ectodermally derived structures. These structures include teeth, hair, skin, nails, and sweat glands. Oligodontia, anodontia, and dysmorphic teeth have been reported in both the primary and permanent dentition of affected individuals. Hair tends to be sparse and very fine while skin is dry due to absence or diminished numbers of sweat glands. If hypohidrosis is a feature of the disorder, heat intolerance is common.¹

Freire-Maia and Pinheiro² have described and classified 117 forms of ectodermal dysplasia based on combinations of specific clinical and morphological features. This disorder may be transmitted by all mendelian modes of inheritance, as well as by spontaneous *de novo* mutations. The phenotypic expression of ectodermal dysplasia is variable. Therefore, affected individuals may exhibit a range of clinical features involving teeth, hair, skin, and sweat glands.

Tooth ankylosis is defined as a fusion of cementum or dentin with alveolar bone.³ Affected teeth are unable to move vertically as the alveolar bone grows and, therefore, appear to submerge below the occlusal plane. There has been much debate in the dental literature concerning the diagnosis, etiology, and treatment of ankylosis.^{4,5} Some primary ankylosed teeth will exfoliate normally and not interfere with permanent suc-

cessor development. Others will cause future surgical problems, loss of arch space, or eruption difficulties of succedaneous teeth. The pediatric dentist must monitor this clinical situation carefully and determine whether intervention is required.

Case report

Chief complaint

A 5-year-old Caucasian female presented to the University of Texas Health Science Center at San Antonio. She was referred to the pediatric dental clinic by her private dentist. Her parents stated that the referring dentist exposed radiographs that revealed several missing permanent teeth. The patient's chief complaints were difficulty in chewing food and attrition of the primary maxillary incisors.

Clinical exam

Physical findings included a pale complexion, smooth skin with normal finger nails, and fine, sparse hair and eyebrows. Mild frontal bossing was evident and her profile was slightly convex with a retrusive chin. Lower anterior facial height was markedly deficient and both lips appeared thin. The patient's past medical history was unremarkable except the parents reported that the patient became easily flushed and overheated during physical activity. The patient was one of two children born to nonconsanguineous parents. Neither parent nor the younger male sibling displayed abnormal features consistent with ectodermal dysplasia. Although the pedigree was incomplete, several family members on the maternal side had a history of missing teeth and sparse hair.

Intraoral exam showed healthy gingiva and mucosa. The primary dentition was complete with generalized spacing and no dental caries. All teeth were small and had a tapered appearance gingivo-occlusally. In addition, all primary first molars appeared submerged relative to the primary second molars. However, all molars emitted a solid sound on percussion. Both maxillary central incisors had small fractures in the enamel and were sensitive to percussion.

In centric occlusion, two anterior contacts resulted in a 5-mm bilateral posterior open bite (Fig 1). To improve function, the patient positioned the mandible forward so that all the incisors were contacting end to

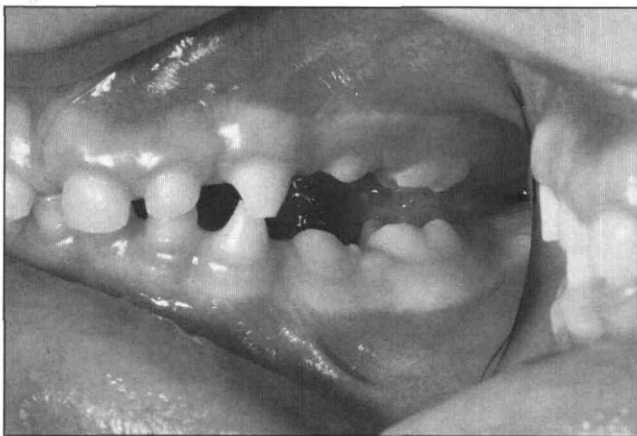


Fig 1. Intraoral photograph showing extent of posterior open bite.

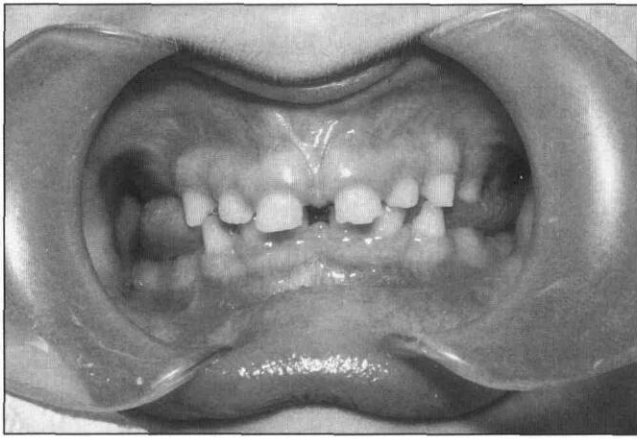


Fig 2. Intraoral photograph showing tongue thrust upon swallowing.

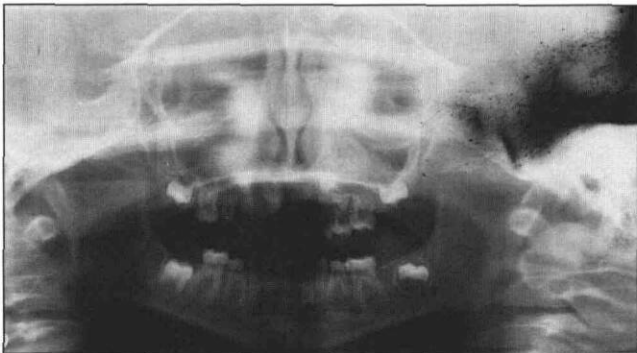


Fig 3. Panoramic radiograph of developing dentition.

end. This increased the occlusal function to four anterior contacts. The tongue was normal in size. The resting position of the tongue was evaluated as normal. A posterior bilateral tongue thrust was observed on swallowing (Fig 2).

Radiographic exam

The panoramic and periapical radiographic examination confirmed development of the following permanent teeth: all first molars, maxillary canines and central incisors, maxillary left first premolar, and mandibular left canine (Fig 3). Radiographically, all primary molars showed an absence or discontinuity of the periodontal ligament space.

Treatment

Based on the findings, a clinical diagnosis of hypohydrotic ectodermal dysplasia complicated by ankylosis of all primary molars and traumatic occlusion of anterior teeth was made. Our treatment goals were to provide the patient with a balanced occlusion to distribute masticatory forces equally and to improve function and esthetics. A conservative treatment plan of complete maxillary and mandibular overdentures was implemented (Fig 4). Due to the 100% overbite in centric occlusion, the interarch separation was increased

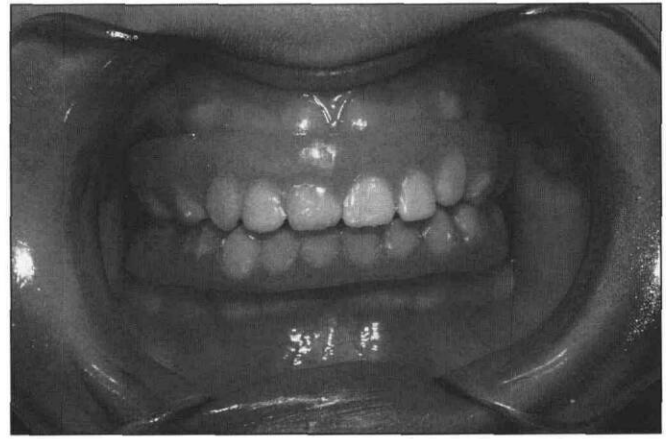


Fig 4. Intraoral photograph showing complete maxillary and mandibular overdentures.

4 mm to improve esthetics, create room for denture teeth and to increase lower vertical face height to that compatible with facial growth norms (Figs 5 and 6).

12-month followup

As with all removable appliances, there is potential for misplacement. The dentures were lost after 3 months and a spare set was used temporarily until a new set could be fabricated. The patient was seen on a regular basis to assess development. Due to the vertical growth of the alveolar ridges, the ankylosed teeth were slightly more submerged. However, a continued conservative approach was still indicated.

Discussion

Children can adapt quite well to intraoral removable appliances with some practice.⁶ As this patient grows, replacement dentures will have to be fabricated, primarily to accommodate increasing vertical dimension. If the maxillary permanent teeth erupt, a fixed anterior prosthesis may be considered. Implants may be indicated later in order to replace missing lower permanent teeth if the alveolar bone is adequate.^{7,8} This was the principal reason for adopting a nonsurgical approach. Leaving the submerged primary first molars in place, improves the stability and retention of

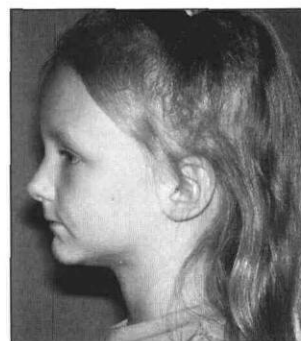

Fig 5. Profile of patient.

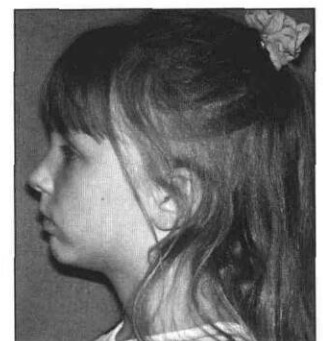

Fig 6. Profile of patient with dentures in place.

the overdentures and preserves the alveolar bone in these areas. The parents are compliant and the patient will be monitored at frequent intervals. However, if recall examination reveals significant additional submergence, specific primary teeth will be extracted.

The association of ectodermal dysplasia with tooth ankylosis and lack of vertical arch development has not been reported in the dental literature. As discussed previously, ectodermally derived tissues are either absent or defective in this disorder. Normal tooth development is dependent upon a series of reciprocal tissue interactions between ectodermal (oral epithelium) and ectomesenchymal (cranial neural crest) tissue.⁹ Dental defects seen in ectodermal dysplasia are likely a result of abnormal interactions between these tissues. Recent studies¹⁰⁻¹² have demonstrated that normal development of root dentin, cementum, and periodontal ligament also depends on interactions between epithelium (Hertwig's epithelial root sheath) and ectomesenchyme (dental papilla and dental sac). Thus, the defects of the periodontium in this case could well result from inappropriate interactions involving these tissue components. Abnormal development of these structures could initiate tooth ankylosis and the subsequent submergence of the involved primary teeth.

Dr. Pedersen is pediatric dental resident and Dr. Hallett is visiting assistant professor, both in the department of pediatric dentistry, The University of Texas Health Science Center at San Antonio, Texas.

The authors express their gratitude to Gretchen Groff for preparing this manuscript.

1. Witkop CJ Jr, Brearley LJ, Gentry WC Jr: Hypoplastic enamel, onycholysis, and hypohidrosis inherited as an autosomal dominant trait. A review of ectodermal dysplasia syndromes. *Oral Surg Oral Med Oral Pathol* 39:71-86, 1975.
2. Freire-Maia N, Pinheiro M: *Ectodermal dysplasias: a clinical and genetic study*. New York: Alan R Liss Inc., 1984.
3. Biederman W: Etiology and treatment of tooth ankylosis. *Am J Orthod* 48:670-84, 1962.
4. Biederman W: The problem of the ankylosed tooth. *Dent Clin North Am* 10:409-24, 1968.
5. Kurol J, Koch G: The effect of extraction on infraoccluded deciduous molars: a longitudinal study. *Am J Orthod* 87:46-55, 1985.
6. Till MJ, Marques AP: Ectodermal dysplasia: treatment considerations and case reports. *Northwest Dent* 71:25-28, 1992.
7. Ekstrand K, Thomsson M: Ectodermal dysplasia with partial anodontia: prosthetic treatment with implant fixed prosthesis. *ASDC J Dent Child* 55:282-84, July-August 1988.
8. Guckes AD, Brahim JS, McCarthy GR, Rudy SF, Cooper LF: Using endosseous dental implants for patients with ectodermal dysplasia. *J Am Dent Assoc* 122:59-62, 1991.
9. Kollar EJ: Histogenetic aspects of dermal-epidermal interactions. In *Developmental Aspects of Oral Biology*. Slavkin HC, Bavetta LA, EDS. New York: Academic Press. 1972, pp. 125-49.
10. Thomas HF, Kollar EJ: Differentiation of odontoblasts in grafted recombinations of murine epithelial root sheath and dental mesenchyme. *Arch Oral Biol* 34:27-35, 1989.
11. MacNeil RL, Thomas HF: Development of the murine periodontium. I. Role of basement membrane in formation of a mineralized tissue on the developing root dentin surface. *J Periodontol* 64:95-102, 1993.
12. MacNeil RL, Thomas HF: Development of the murine periodontium. II. Role of the epithelial root sheath in formation of the periodontal attachment. *J Periodontol* 64:285-91, 1993.

From the Archives

John Hunter grinds out an interceptive stratagem

In a case where decay of the first adult grinder (occurs) before the temporary grinders are shed, I would recommend removing the diseased tooth immediately, though it may occasion no kind of trouble, for, if it can be drawn before the temporary grinders are shed and before the second adult grinder has cut the gum, it will in a short time not be missed, because the bicuspid on that side will fall back a little and the second and third grinders will come a little forward, by which means the space will be filled up, and these teeth will make room which is often very much wanted, especially in the upper jaw.

in Diseases of the Teeth, John Hunter, 1778