

Cementum and epithelial attachment response to the sulcular and periodontal ligament injection techniques

John E. Peterson, DDS, MS
Lars Matsson, DDS, Odont Dr
Wilfred Nation, DDS

Abstract

This investigation studied the effect of the sulcular and periodontal ligament injection techniques on certain periodontal tissues. Eleven monkeys (Macaca nemestrina) were given injections of local anesthetic into the sulcular tissue or the periodontal ligament on the lingual side of maxillary molars. Contralateral teeth served as controls. After three months biopsies were taken and made into histologic sections. Of 6 teeth receiving a sulcular injection, 1 had a small area of cementum resorption. Of the 16 teeth which received a periodontal ligament injection, 2 had areas of cementum resorption and 1 showed an area of hypercementosis. No detrimental changes were found in the level of epithelial attachment.

"Sandard techniques" are used most often to achieve nerve block and infiltration anesthesia in dentistry. However, on occasion these techniques have proved to be either uncomfortable to the patient or have resulted in inadequate anesthesia. Consequently, practitioners have begun to modify existing techniques and develop new ones that meet their clinical needs. The sulcular and periodontal ligament injections are examples of such modifications.

The sulcular injection technique is especially useful in the maxillary-posterior-lingual areas of the primary and mixed dentition. For example, it may be used in combination with a buccal infiltration before extraction, or when applying rubber dam clamps. In this technique the needle is inserted gently approximately 0.5-1.0 mm into the tissue at the bottom of the gingival sulcus and a small amount of solution is injected slowly (Figure 1). Clinically, the use of this method in pediatric dentistry causes no apparent damage to the periodontium. In addition, the procedure seems to be less painful and therefore better tolerated by patients than alternative injection techniques.

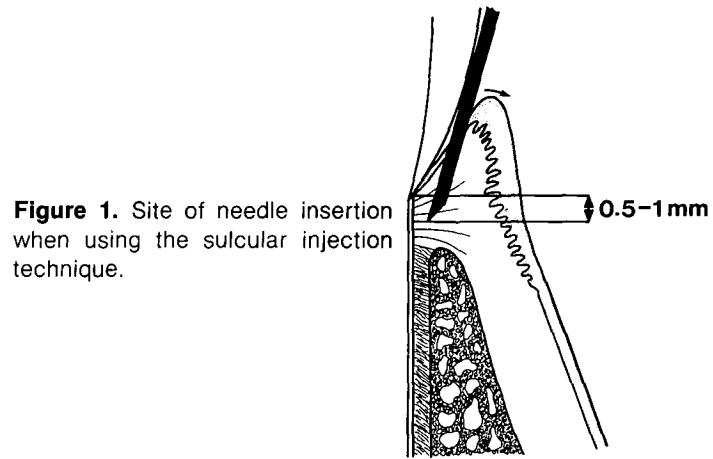


Figure 1. Site of needle insertion when using the sulcular injection technique.

The periodontal ligament (PDL) injection has been described by Mead,¹ Roberts and Sowray,² and Walton and Abbott.³ In this technique the needle is inserted into the PDL where the solution is injected (Figure 2).

Favorable clinical experience using the sulcular and PDL injection techniques encourages further study. However, Mead¹ and Roberts and Sowray² expressed concern about possible detrimental effects from the intra-PDL injection. These concerns apparently were based on clinical impressions.

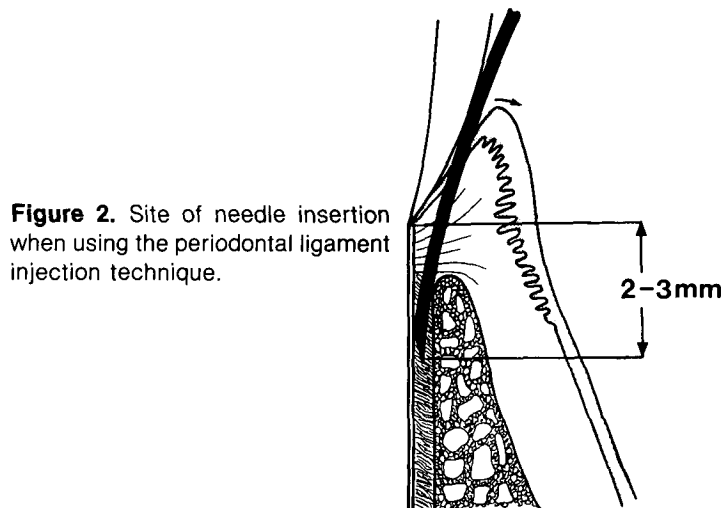


Figure 2. Site of needle insertion when using the periodontal ligament injection technique.

Recently Walton and Garnick⁴ investigated the histologic effects of the PDL injection on the periodontium of monkeys using a standard syringe. They found no significant detrimental effect on the periodontal tissues following the injection. Some manufacturers, however, have recommended the use of a pistol-type syringe for this kind of injection. These syringes may generate far more pressure than the standard syringe, and the effect of the pistol-type syringes on the periodontium is unknown.

The purpose of this investigation was to obtain additional information about the effect of sulcular and PDL injections on the cementum and level of epithelial attachment.

Methods and Materials

Eleven male monkeys (*Macaca nemistrina*), approximately four years old, were used in this study. During the entire experimental period the animals were fed primate chow^a ground to a grainy consistency. No oral hygiene was performed. All injection and biopsy procedures were performed with the animals anesthetized by IM ketamine HCl.^b One side of the maxilla of each animal randomly was designated as the experimental side. Injections were performed on first and second molars. Corresponding contralateral teeth were left untreated for controls. The study was conducted in two phases with two groups of monkeys. In the first phase six monkeys were given sulcular injections on first molars and PDL injections on second molars. In the second phase only PDL injections were given. These were performed on both the first and second molars of five additional monkeys. This resulted in a total of 6 sulcular injections and 16 PDL injections. There were an equal number of control teeth for each type of injection.

At each injection site, approximately 0.1 ml of mepivacaine HCl^c with 1:20,000 levonordefrin^d was injected using a pistol-type syringe^e and a 30-gauge needle. The syringe was used because this type has been marketed lately expressly for giving PDL injections. In addition, the syringe facilitated the standardized injection pressures and amounts of solution injected. The actual amount of pressure generated by the syringe was not determined. However, in an attempt to keep this pressure constant for each injection site, the specified amount of solution was delivered to each site over a period of approximately ten seconds.

The lingual site of maxillary molars was chosen as the injection site. Others have suggested the interproximal area for periodontal injections, but for research purposes the lingual area provides excellent accessibility, and there

are no adjacent roots or PDLs which might create additional variables.

The needle was inserted to a depth of 0.5-1.0 mm for the sulcular injections, and 2-3 mm for the PDL injection. The syringe uses a 30-gauge needle with a reinforcing sleeve which fits over the needle. The depth of penetration was measured by adjusting the sleeve to stop 1 mm from the tip of the needle for the sulcular injection and 3 mm for the PDL injection.

After three months biopsies were taken from the injection areas and from the control areas. The biopsy consisted of lingual periodontal tissues with the adjacent tooth portion. It was felt that three month's time period between injections and biopsies would allow reversible, acute responses from the injections to resolve. Thus, the biopsy would reveal the long-term effect of these injection techniques.

The tissue samples were fixed in 10% formalin and demineralized in 5% formic acid. After demineralization the biopsies were dehydrated in graduated alcohol and embedded in paraffin by vacuum infiltration for about 30 minutes at a pressure of 13.6 kp. Serial sections, 7 μ m thick, were cut in the buccolingual plane throughout the entire biopsy and stained with hematoxylin and eosin.

All stained sections were inspected by light microscopy at 100x. This microscopic analysis was performed simultaneously by two of the authors without knowledge of group membership of the sections. Special interest was given to the cementum in order to detect resorptions or other defects, and to the attachment level of the junctional epithelium (JE). Cementum defects were determined to be present if the thickness or texture of the cementum changed abruptly. Downgrowth of epithelium was said to exist if the JE extended below the cemento-enamel junction (CEJ).

Results

All biopsies from both the injection and control areas showed a clearly defined inflammatory infiltrate of the connective tissue, adjacent to the JE. The inflammatory infiltrate mainly consisted of mononuclear inflammatory cells.

In 10 control biopsies from first molars and 1 control biopsy from a second molar, the attachment level of the JE was below the CEJ (Figure 3). Except for the chronic inflammation found in all biopsies and the attachment level of the JE, below the CEJ in some of the biopsies, all control biopsies showed normal gingiva and PDL.

Sulcular Injection

One section from the six sulcular injection biopsies showed a 0.05 mm area of resorption of the cementum at about the depth of needle penetration (Figure 4). In some of the biopsies a low attachment level of the JE was seen; however, this same anomaly was found with equal frequency in contralateral controls.

^a Lab Chows, Ralston and Purina Co.; St. Louis, Mo.

^b Vetalar, Parke-Davis; Detroit, Mich.

^c Carbocaine, Cook-Waite Labs, Inc.; New York, N.Y.

^d Neo-cobefrin, Cook-Waite Labs, Inc.; New York, N.Y.

^e Peripress, Renaissance Laboratory; Lexington, Ky.

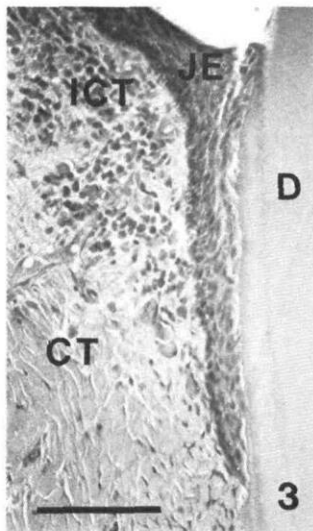


Figure 3. Junctional epithelium (JE) situated below the cemento-enamel junction. CT = connective tissue. ICT = infiltrated connective tissue. D = dentin. Bar represents 100 μ m.

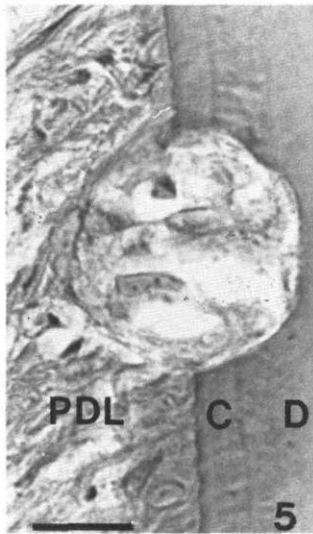


Figure 4. Resorption of cementum (C) in the area of injection after using the sulcular injection technique. PDL = periodontal ligament. D = dentin. Bar represents 20 μ m.

Periodontal Ligament Injection

In three of the biopsies from areas where PDL injections had been performed, changes of the root cementum were found. These changes were situated at approximately the level of the needle tip penetration. Two of the biopsies showed resorptions extending into the dentin. In one of these sections, a considerable part of the resorption lacuna was filled with cellular cementum (Figure 5), and in the other section the resorption appeared to be outlined with a thin layer of cementum (Figure 6). The third biopsy with alterations to the cementum showed a thickened layer of cementum, without any signs of preceding resorption (Figure 7). In some of the biopsies where PDL injections were performed, a low attachment level of the JE was seen. However, the same anomaly was found with equal frequency in contralateral controls.

Discussion

When injecting anesthetic into, or close to, the PDL, three factors may potentially induce tissue damage: (1) mechanical trauma from the needle itself; (2) fluid pressure from injecting the solution; (3) the caustic effect of the anesthetic solution. This study has made no

attempt to investigate separately these three factors.

In several sections from areas where injections had been performed, as well as in contralateral control areas, the attachment level of the JE was situated below the CEJ. As this was seen in both experimental and control areas, any relationship between the injection techniques and this

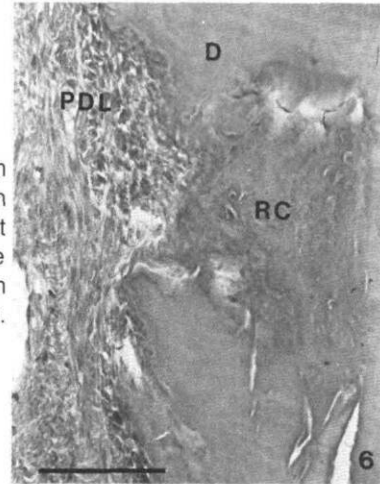


Figure 5. Resorption of cementum and dentin (D) in the area of injection after using the periodontal ligament injection technique. Note the reparative formation of cementum (RC). PDL = periodontal ligament. Bar represents 100 μ m.

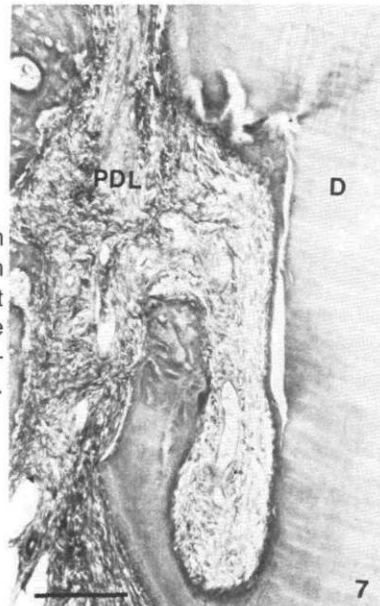


Figure 6. Resorption of cementum and dentin (D) in the area of injection after using the periodontal ligament injection technique. Note the outline of the cementum PDL = periodontal ligament. Bar represents 100 μ m.

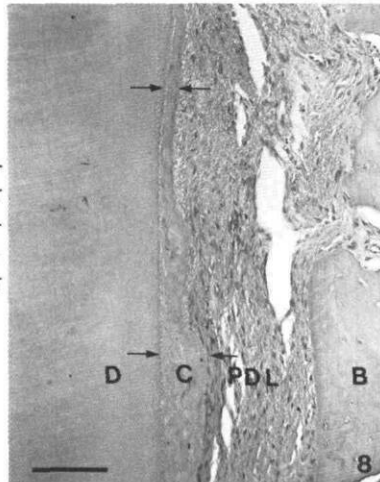


Figure 7. Thickened layer of cementum (C) in the area of injection after using the periodontal ligament injection technique. D = dentin. PDL = periodontal ligament. B = bone. Bar represents 100 μ m.

pathological finding can be excluded. This finding was thought to be the result of prior chronic inflammation of the gingival tissue which continued on throughout the study.

Sulcular Injection

In an area where a sulcular injection had been performed, one biopsy section showed a site of cementum resorption. As this area of resorption was situated at about the level of needle tip penetration and no such resorption was found in the control biopsies, it is reasonable to suspect that the resorption was of iatrogenic origin. The lesion, however, was small and showed a lining of new cementum, indicating an arrest of the resorptive process. Therefore, the clinical significance of a lesion of this nature is probably negligible and no need for any restrictions in using the proper sulcular injection technique seems to exist. However, care should be used to avoid contact with the root surface when introducing the needle to reduce the risk of damaging the cementum.

Periodontal Ligament Injection

On two teeth where a PDL injection was performed, resorption of the root surface was noted. On a third tooth an area of hypercementosis was found. No similar findings were seen within the controls. As these changes of the cementum were located at approximately the site where the anesthetic solution was injected, it is likely that the lesions were caused by the injection procedure. The areas of resorption were shallow, and showed clear indications of repair with no ankylosis. The area of hypercementosis seemed arrested.

It should be noted that the PDL is narrower in the breed of monkeys used in this study than the reported width in humans.⁵ Thus, more ligament space may be available in humans to accommodate the needle and to dissipate the pressure built up by the injection.

It should be stressed that this investigation only studied the effect of PDL injections on fully developed permanent teeth. The effect on the incompletely formed apex

of a newly erupted permanent tooth if the needle is inserted too deeply, or on the succedaneous tooth when the technique is used on primary teeth in later stages of physiologic resorption, is not known. The effect on permanent teeth with pre-existing damage to the PDL due to trauma or periodontal disease is also unknown. Also, the effects of various types of local anesthetics with and without vasoconstrictors should be studied further.

Conclusion

A. Sulcular injection

1. Cementum defects occurred in one of six injection sites.
2. There was no difference between the control and the experimental teeth regarding the incidence of JE downgrowth below the CEJ.

B. PDL injection

1. Cementum defects occurred in 3 of 16 teeth that received a PDL injection. These defects consisted of shallow resorption areas or hyperformation of cementum.
2. There was no difference between the control and experimental teeth regarding the incidence of JE downgrowth below the CEJ.

Dr. Peterson is a professor and chairman, Department of Pediatric Dentistry, Loma Linda University School of Dentistry, Loma Linda, Calif. 92350. Dr. Matsson is senior scientist, Department of Pedodontics, University of Lund School of Dentistry, Malmö, Sweden. Dr. Nation is assistant professor, Department of Pedodontics, Loma Linda University. Reprint requests should be sent to Dr. Peterson.

1. Mead, S.V. Anesthesia in Dental Surgery, 2nd Ed. St. Louis: C.V. Mosby Co., 1951, pp 216-17.
2. Roberts, D.H., Sowray, J.H. Local Anesthesia in Dentistry, 2nd Ed. Bristol, Great Britain: John Wright and Son Ltd., 1979, pp 78-79.
3. Walton, R.E., Abbott, B.J. Periodontal ligament injection: a clinical evaluation. *JADA* 103:571-75, 1981.
4. Walton, R.E., Garnick, J.J. The periodontal ligament injection: histologic effects on the periodontium in monkeys. *J Endod* 8:22-26, 1982.
5. Coolidge, E.D. The thickness of the human periodontal membrane. *JADA* 24:1,260-70, 1937.

Information for Authors

All manuscripts must be accompanied by the following written statement, signed by one author: "The undersigned author transfers all copyright ownership of the manuscript entitled (name of the article) to the American Academy of Pedodontics should the work be published. The undersigned author warrants that the article is original, is not under consideration by another journal, and has not been published previously. I sign for and accept responsibility for releasing this material on behalf of any and all coauthors." Authors will be consulted, when possible, regarding republication of their material.